Clinical Anatomy and Imaging of the Spine

John A. Carrino, M.D., M.P.H.
Vice Chairman
Department of Radiology and Imaging, Hospital for Special Surgery
Professor of Radiology, Weill Cornell Medical College
535 East 70th Street
3E-012
New York, NY 10021
Email: CarrinoJ@HSS.EDU

Spinal Column

Anatomy

- Series of vertebrae, ligaments, and articulations

Function

- Flexible support structure for thorax, abdomen, and cranium
- Protection for cord and nerve roots

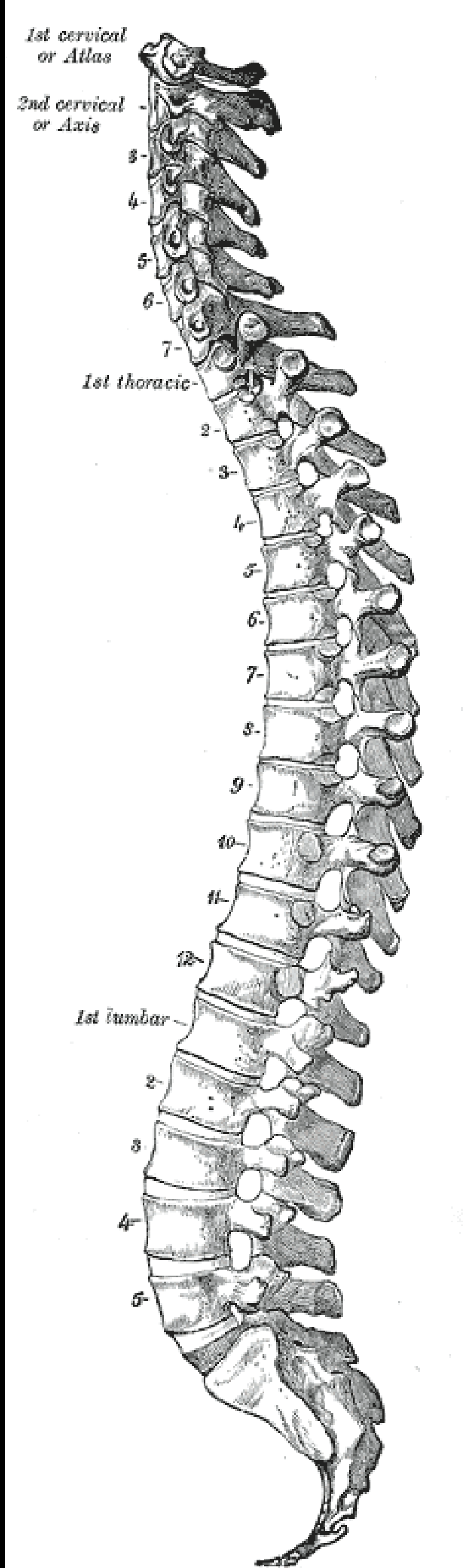

Henry Gray (1821–1865). Anatomy of the Human Body. 1918.

Contents

Imaging techniques

- Radiography
- Myelography
- CT
- MRI

Radiography

- Bony (osseous) structures
- Soft tissue
- Used to assess:
  - Alignment
  - Morphology
  - Osseous destruction

Courtesy of Anna Nidecker and Ari Blitz

Myelography – Rad Fluoro

- Central canal, neural foramen, nerve roots, caliber of cord.
- Used for:
  – Canal narrowing.
  – Foraminal narrowing.
  – Nerve root pathology (mass, arachnoiditis)

Courtesy of Anna Nidecker and Ari Blitz

Myelography – CT

- Bony structures, like CT
- Implants/Hardware
- Central canal, neural foramen, nerve roots, caliber of cord
- Used for:
  - Canal narrowing
  - Foraminal narrowing
  - Intradural lesion if MRI contra-indicated

Courtesy of Anna Nidecker and Ari Blitz

CT

Courtesy of Anna Nidecker and Ari Blitz

- Bony structures, including neural foramen, central canal
- Soft tissue
  - Disc
  - Thecal sac (limited)
- Used to assess:
  - Fracture
  - Malalignment
  - Some soft tissue abnormalities

Courtesy of Anna Nidecker and Ari Blitz

MRI

- Soft tissues – spinal cord, nerve roots, paraspinal soft tissue
- Bone – for marrow abnormalities
- Used to assess:
  - Degenerative changes
  - Trauma
  - Infection
  - Neoplasm

MR imaging primer

T1 WI
- fluid dark
- fat bright unless fat sat (used with contrast)

T2 WI
- fluid bright
- fat bright unless fat sat (looks similar to STIR)

STIR
- fluid sensitive (bright) & rest dark

PD : high SNR
- Fluid somewhat bright
- fat bright unless fat sat

PD-TSE (Intermediate Weighted)

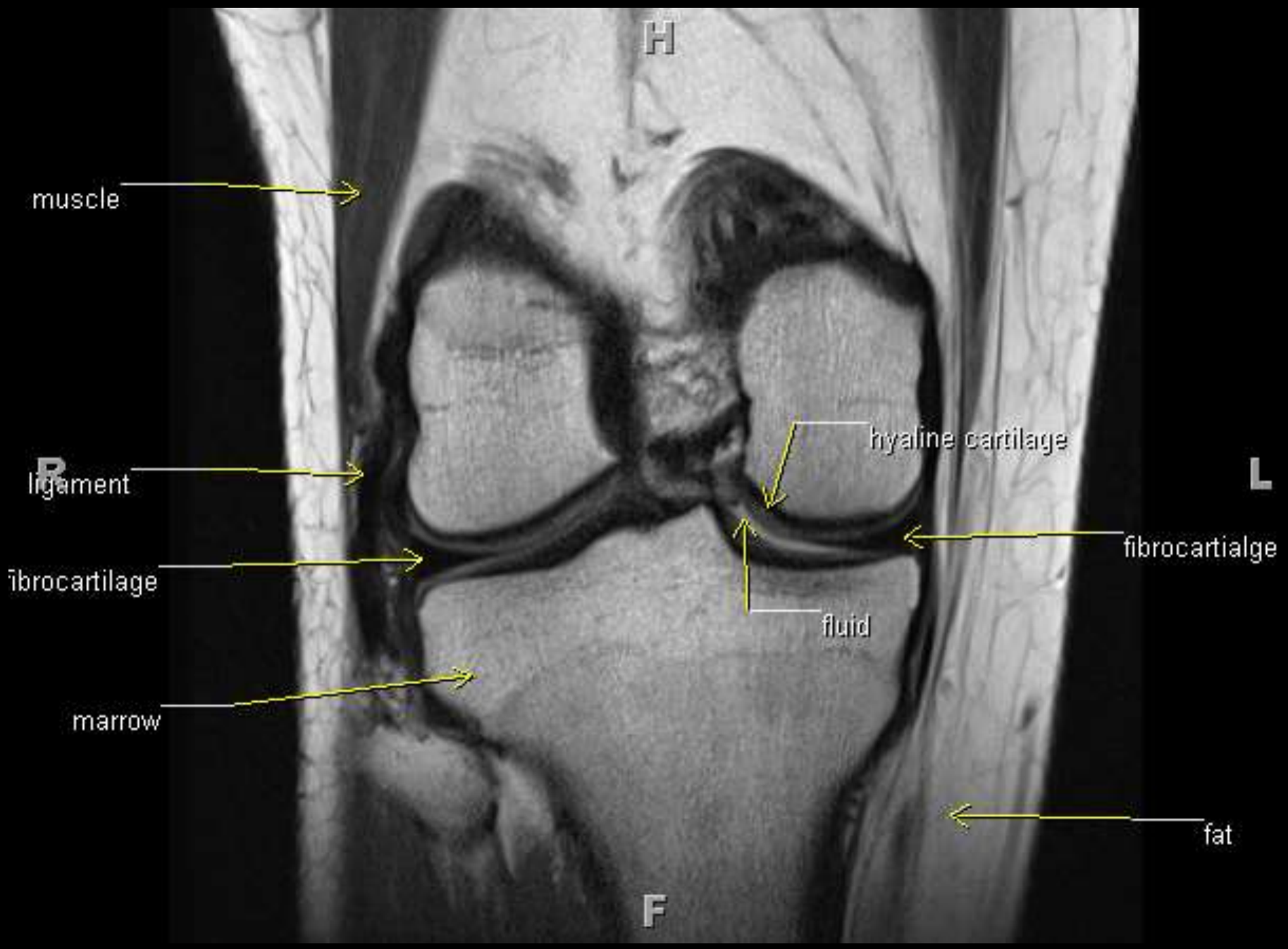

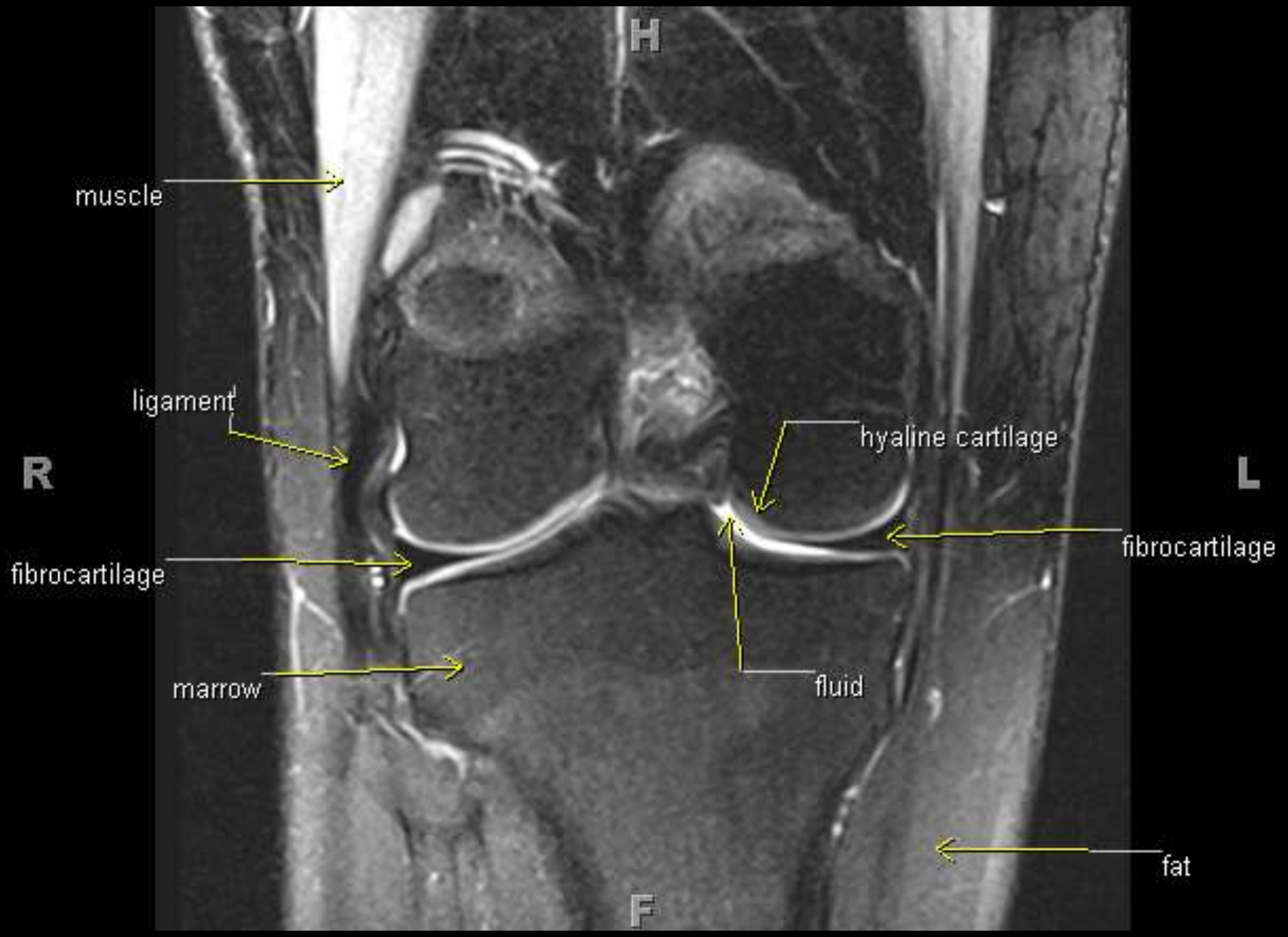

PD : high SNR

Fluid somewhat bright

fat bright unless fat sat

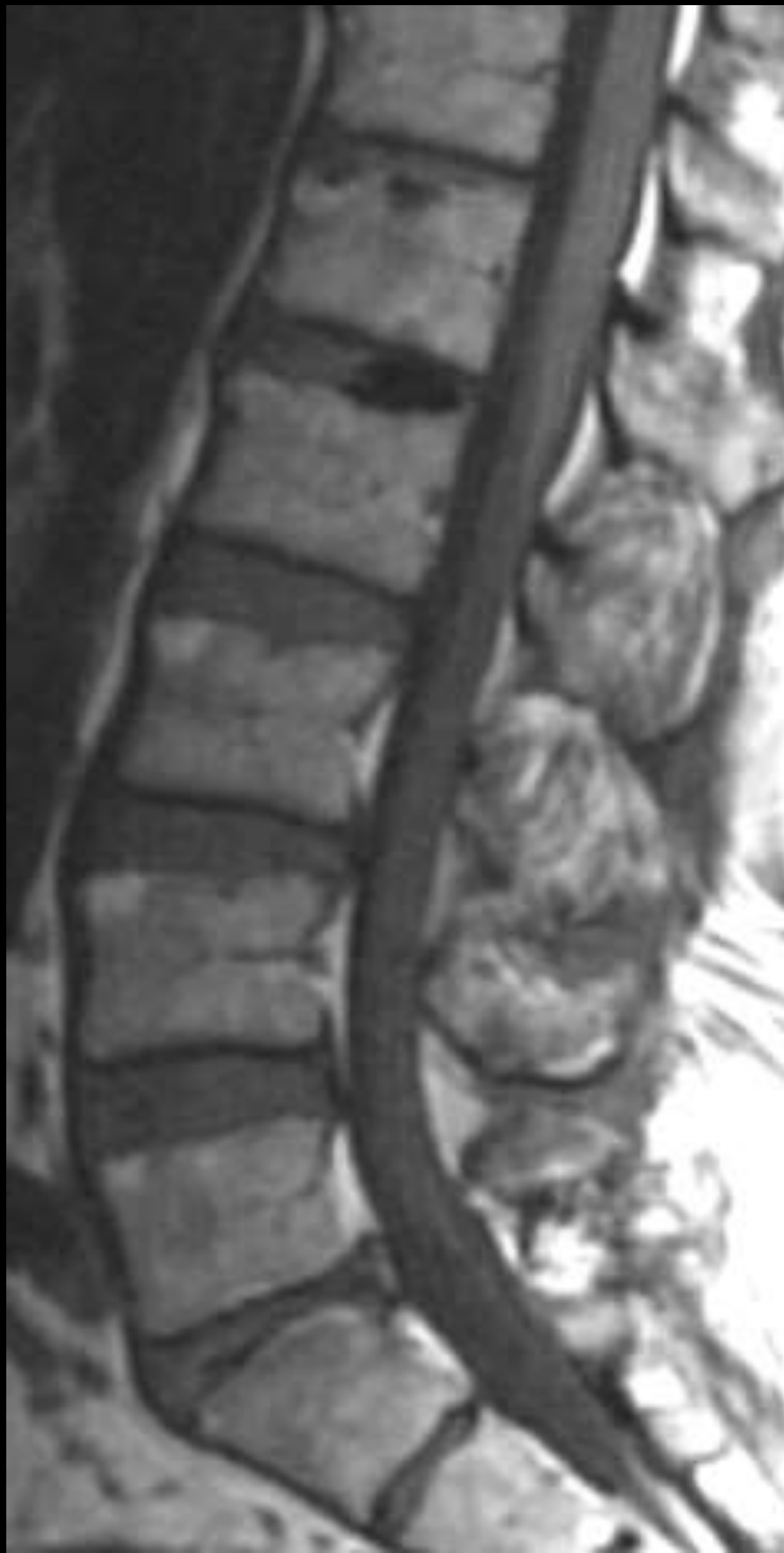

T1-WI

Signal Intensity

- Muscle → gray/intermediate all PS
- Fat → bright T1
- Water → dark T1, bright T2
- Cortex/Tendon/Lig → dark all PS

Contents

Occiput (C0), Atlas (C1), Axis (C2)

- Occipital condyles
- Atlas
  - Lateral masses
  - Stabilizing ligaments
  - Rotational motion
- Axis
  - Dens
  - Body
  - Articular pillars

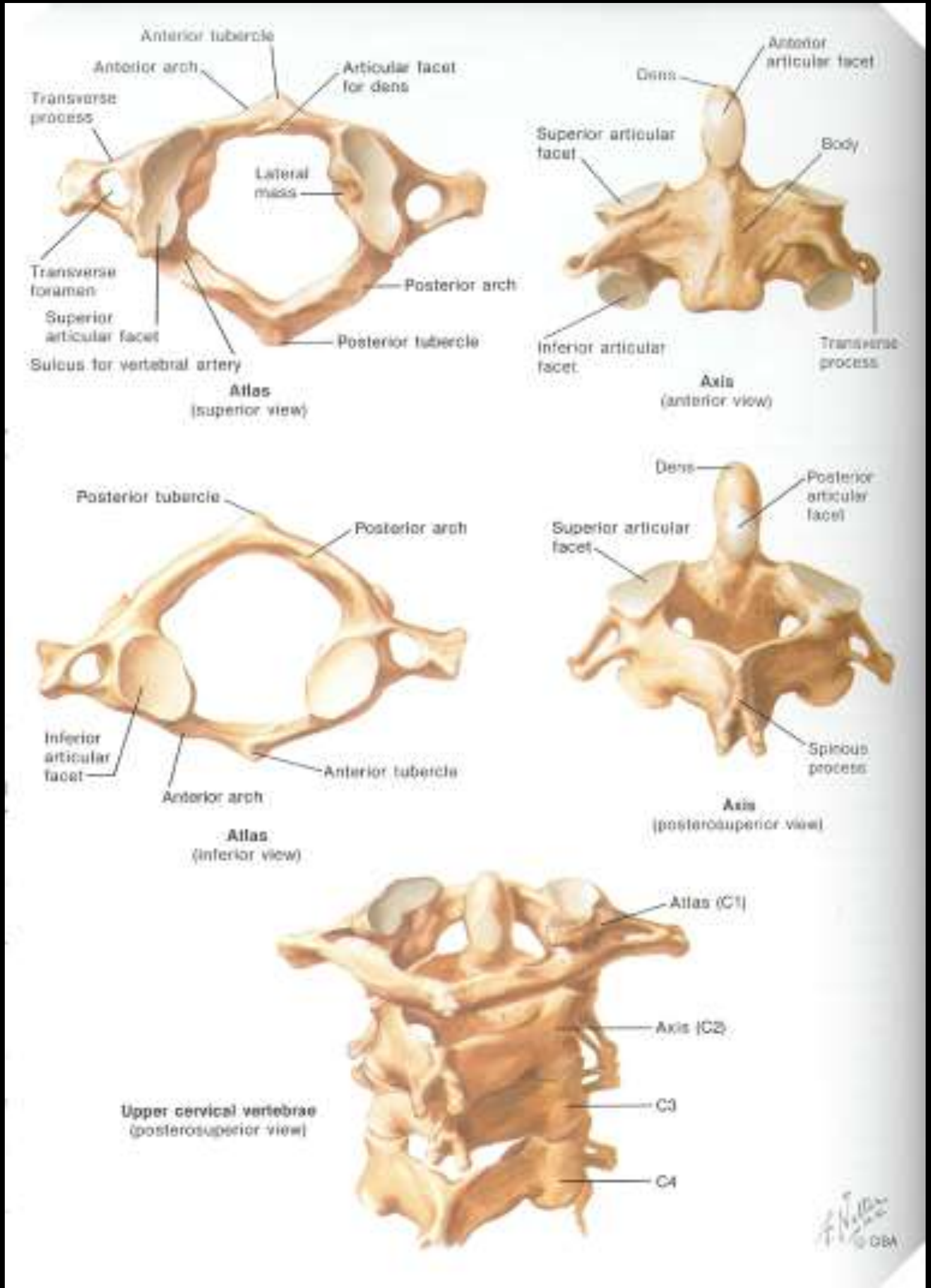

Skull Base

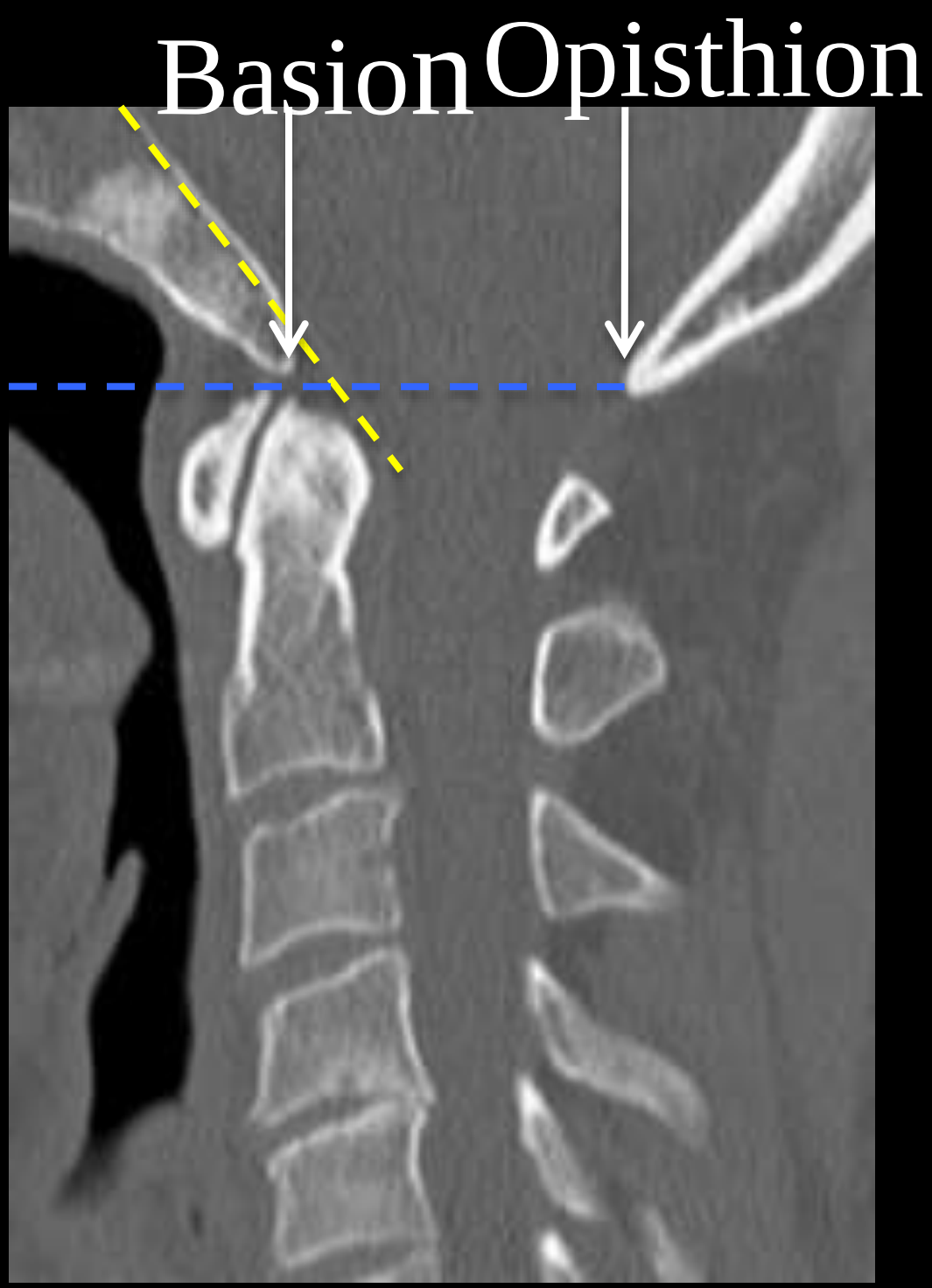

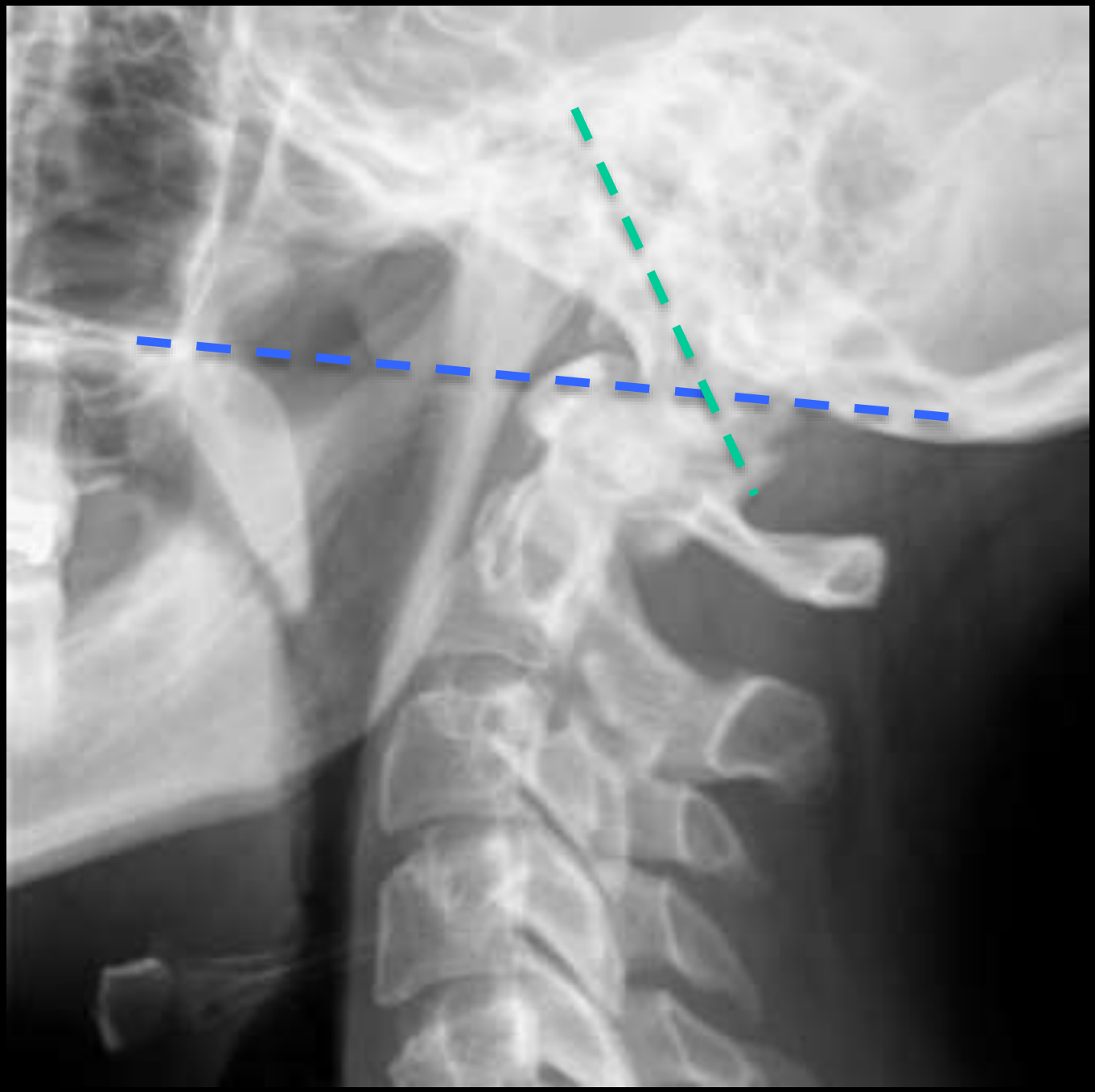

•Chamberlain's Line: Posterior hard palate to opisthion Tip of dens is at or below this line

•Wackenhein Clivus Base Line: Posterior margin of dens is tangent to, but not above this line   Smoker *Radiographics* 1994

Atlanto-Occipital Assimilation

- Failure of Segmentation b/w Skull and C1
  - Typically Associated with Basilar Invagination
- Characteristic comma-shaped appearance of basion

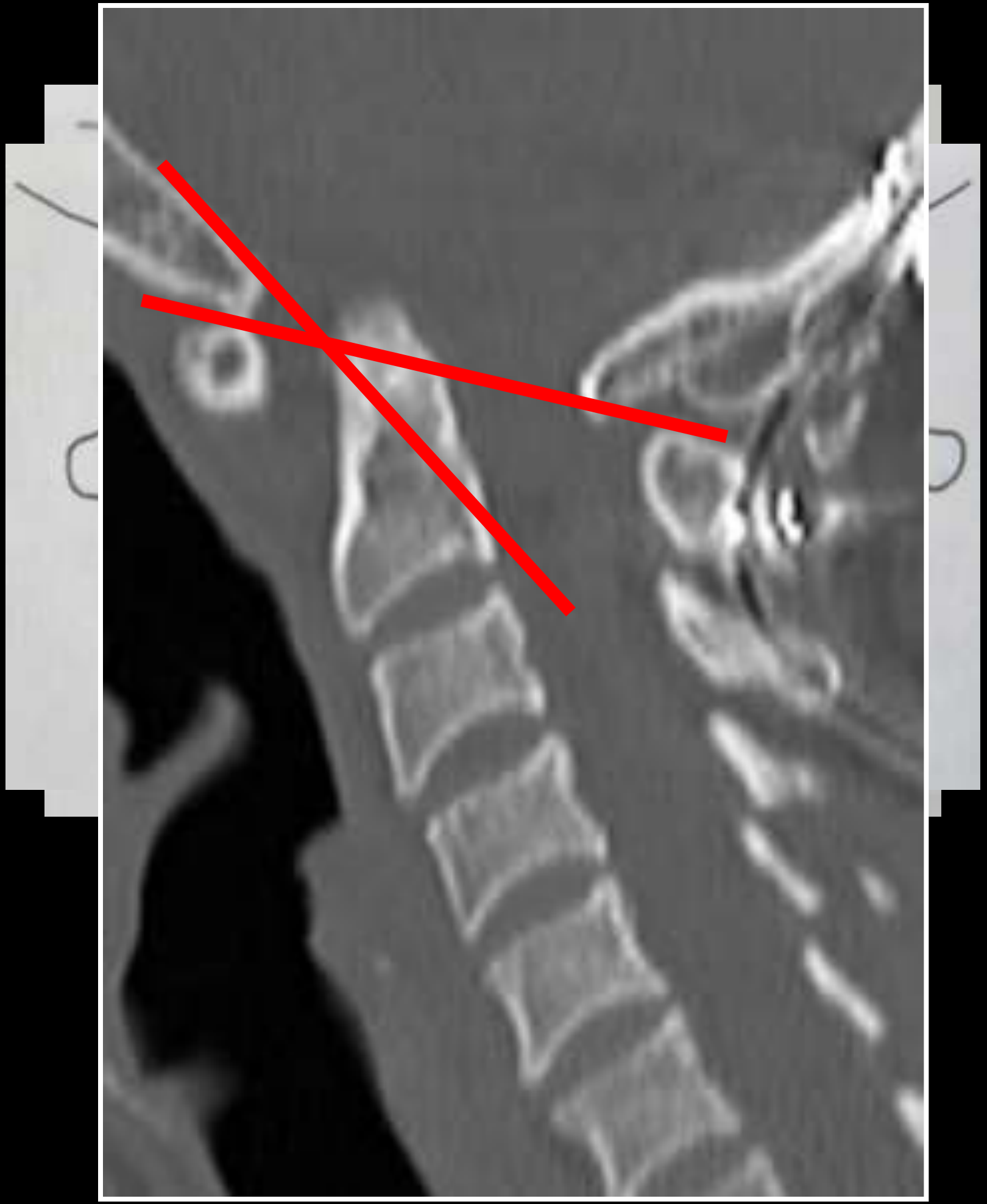

Atlas

- lacks a body
- two lateral masses
- short anterior arch
- longer posterior arch
- Grooves for vertebral Artery
- Foramen transversarium in transverse process

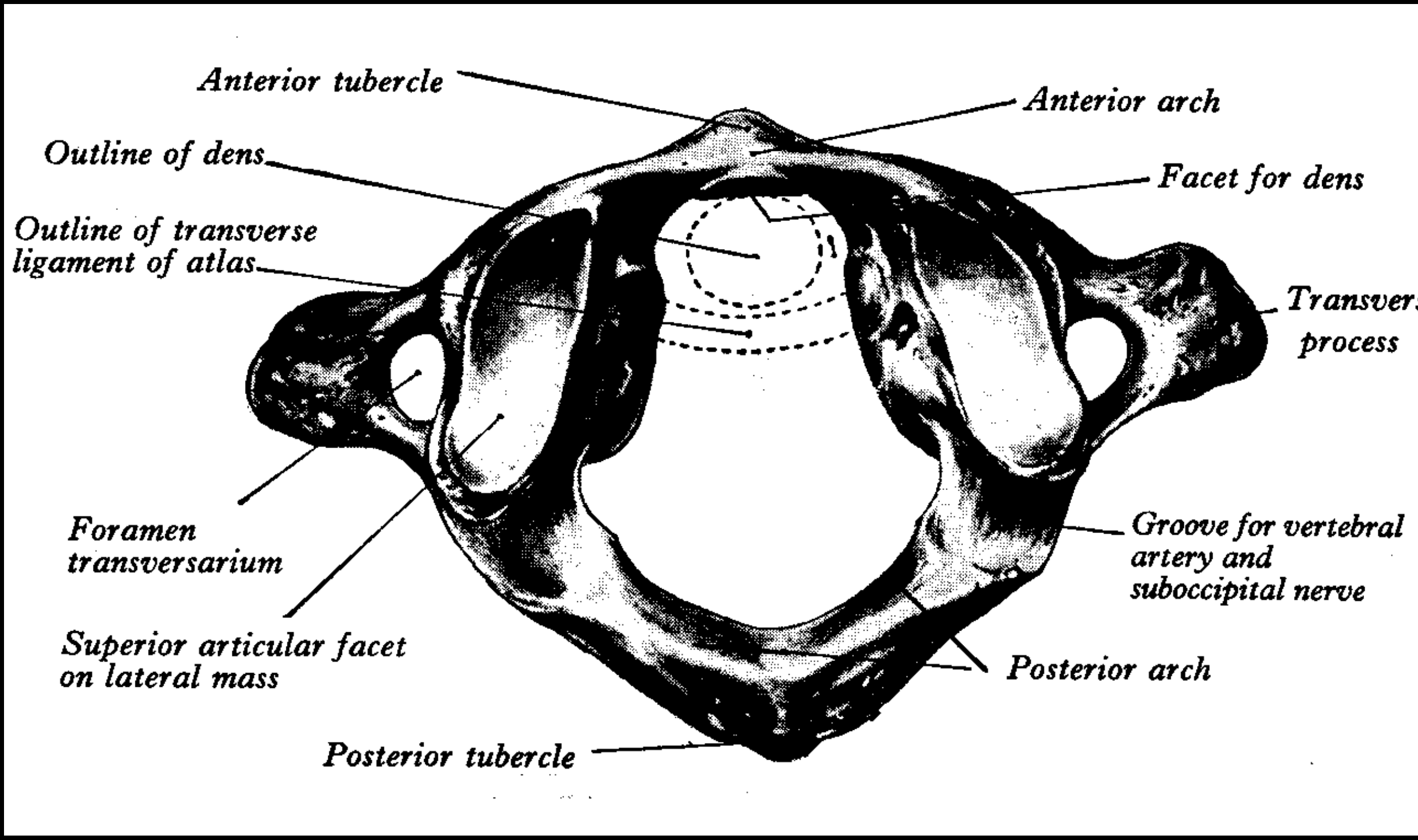

Henry Gray (1821–1865). Anatomy of the Human Body. 1918.

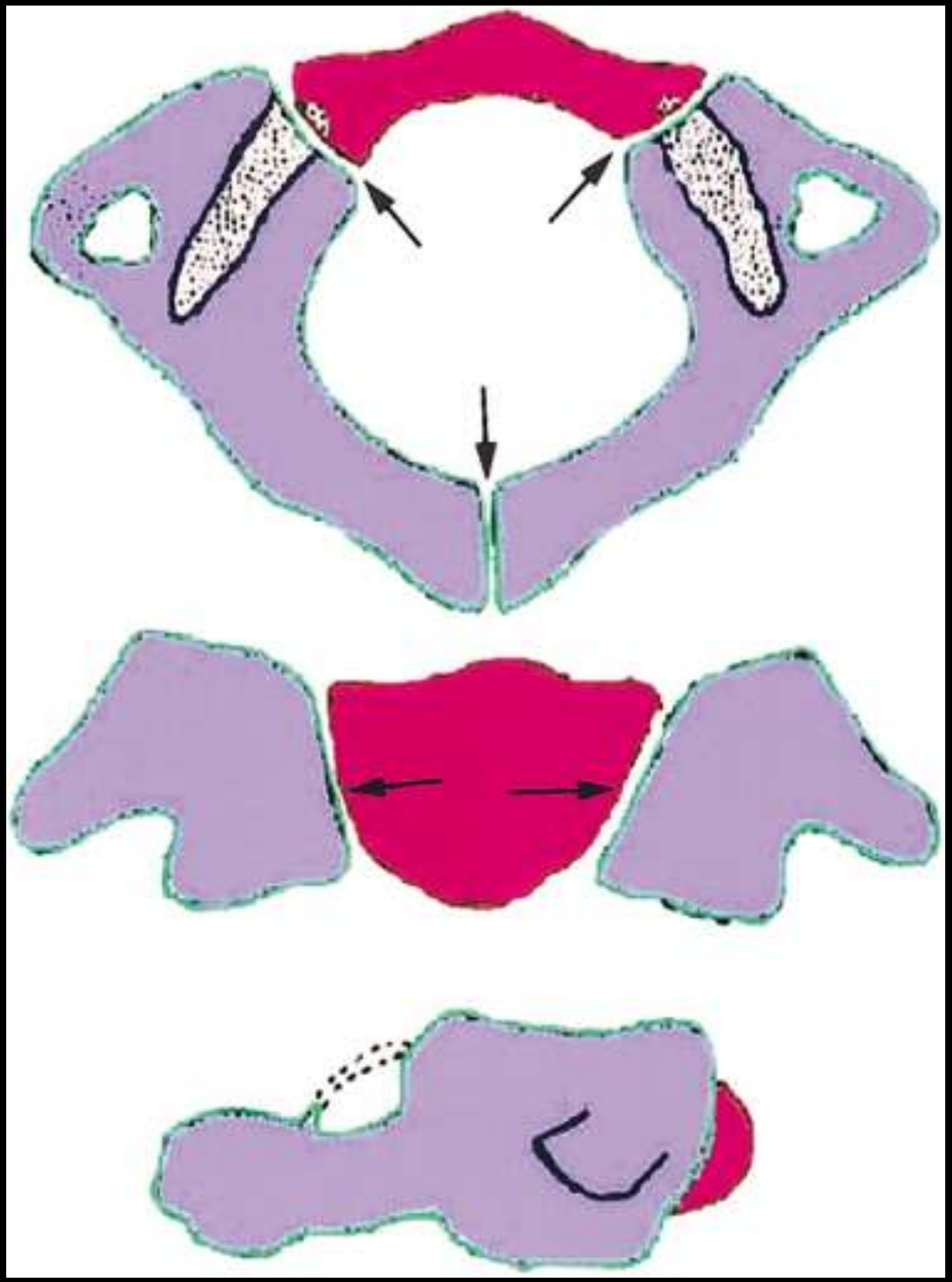

RadioGraphics

Incomplete Fusion C1 Posterior Arch

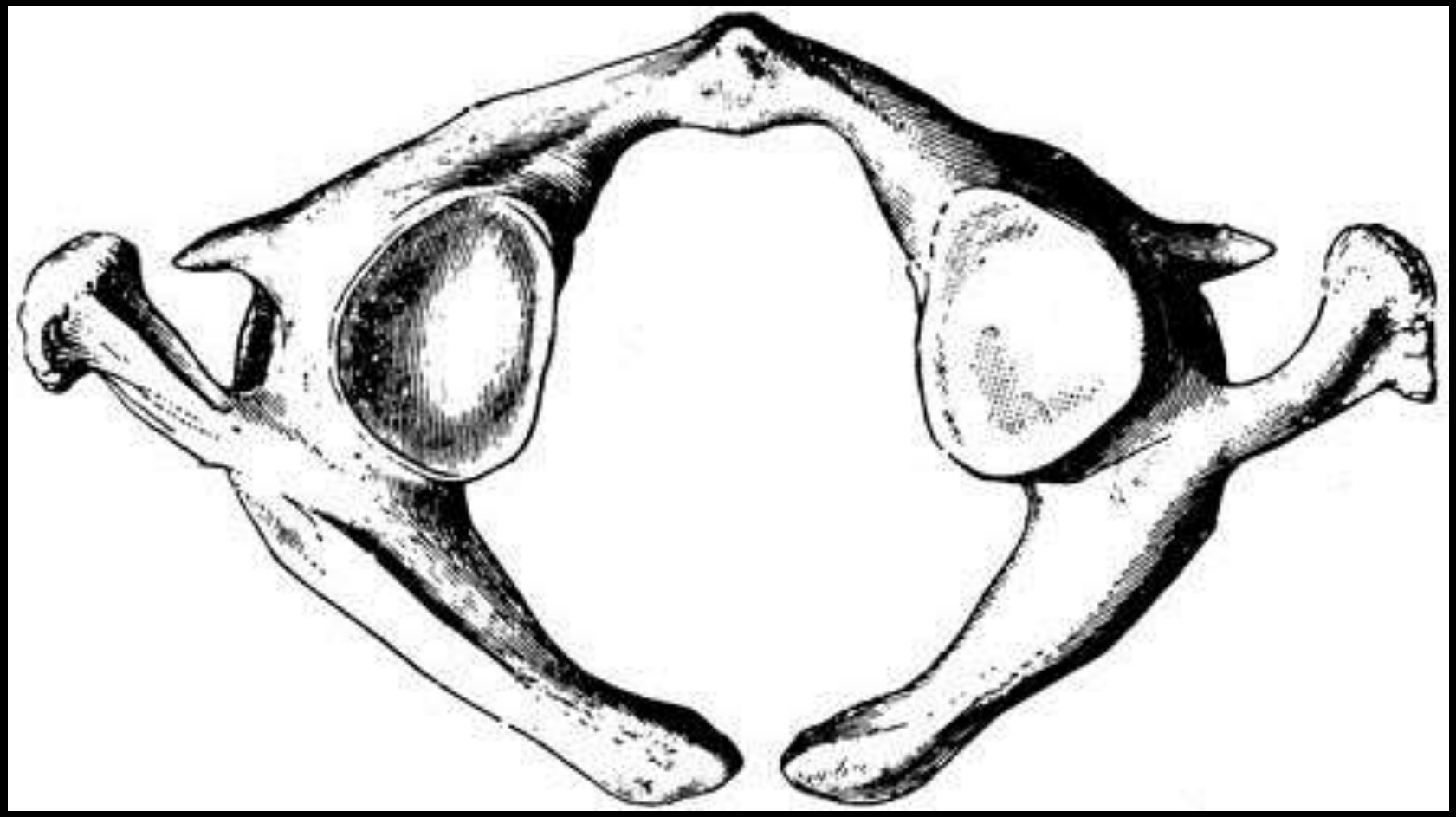

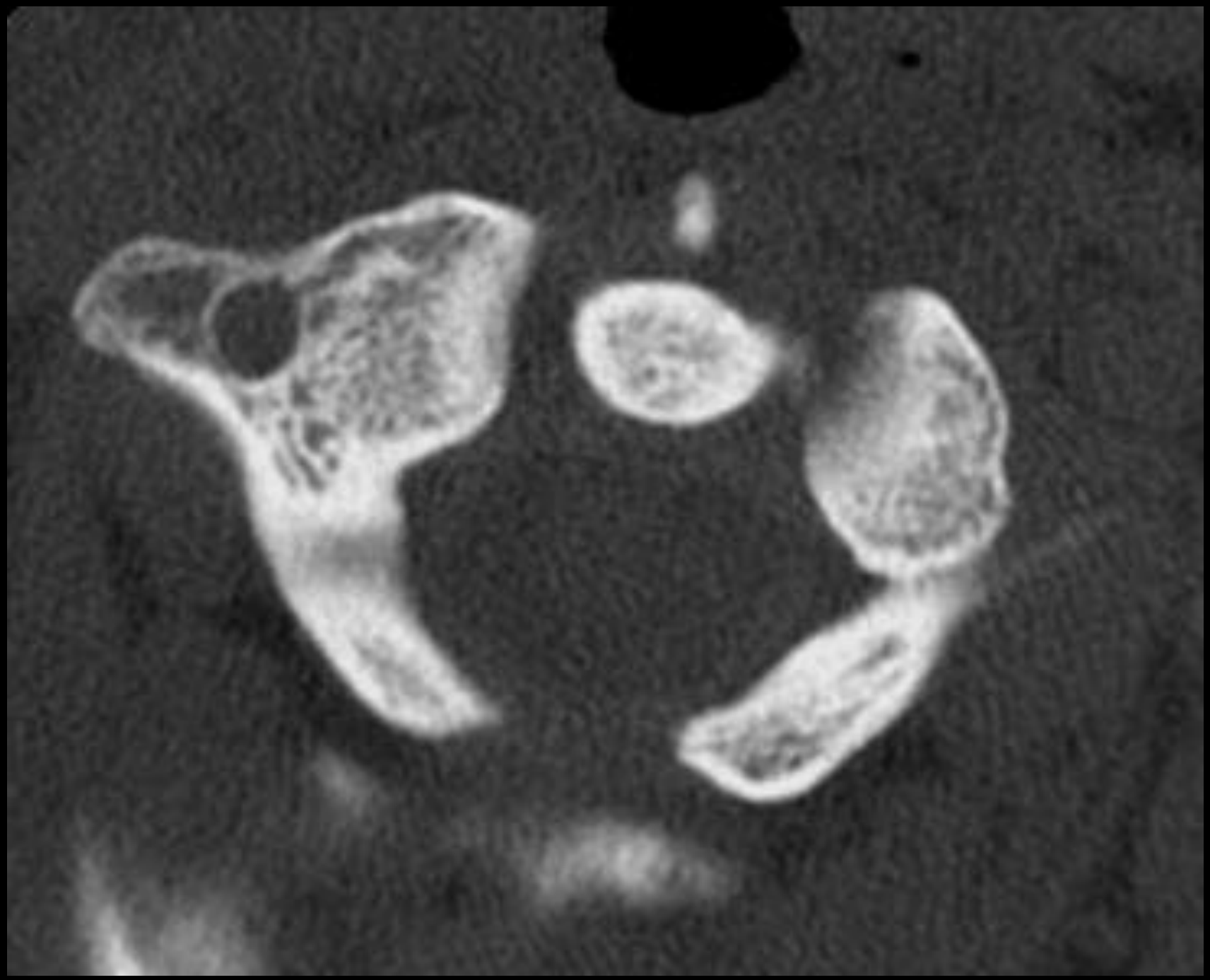

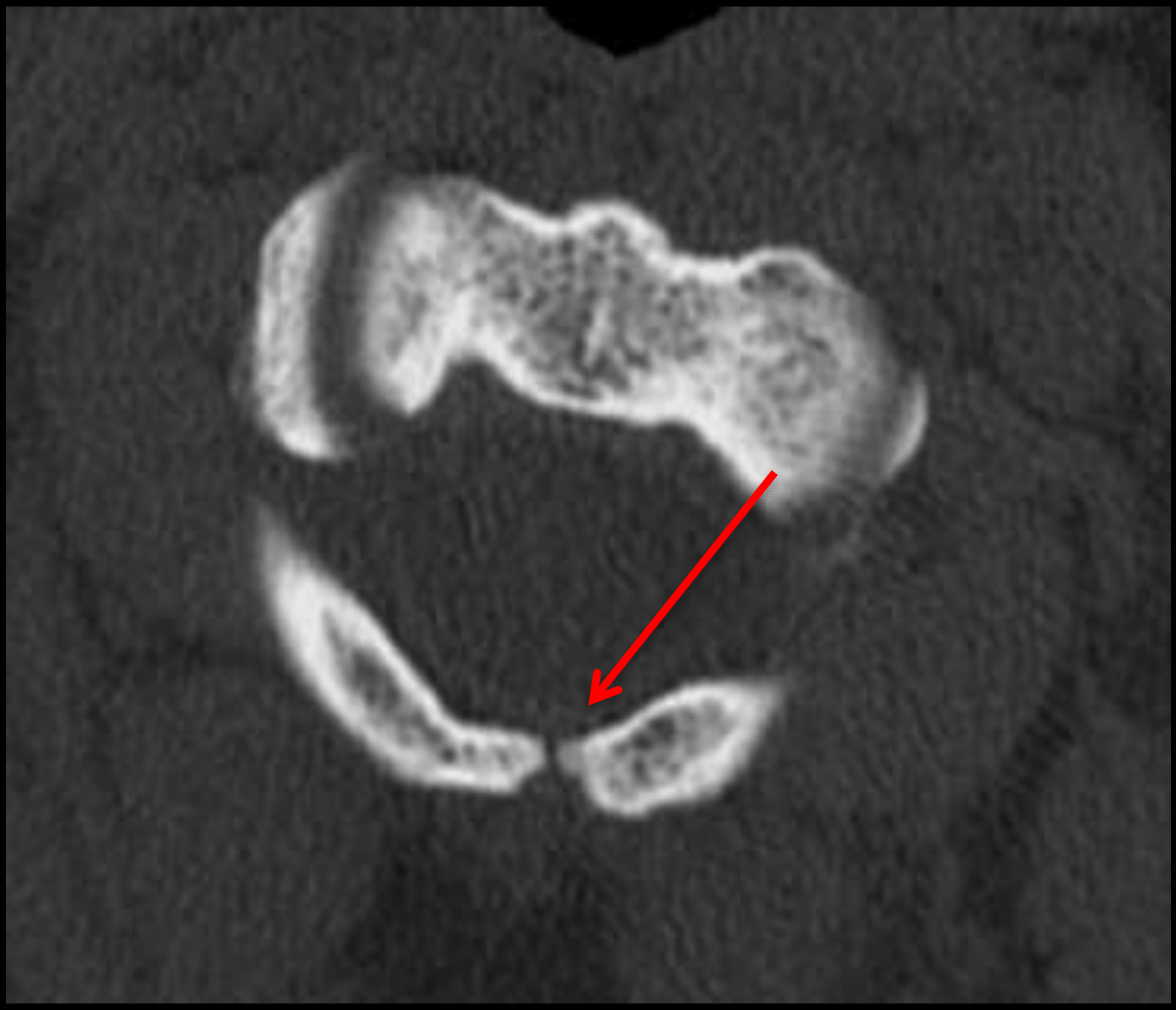

Incomplete Fusion Posterior Arch C1

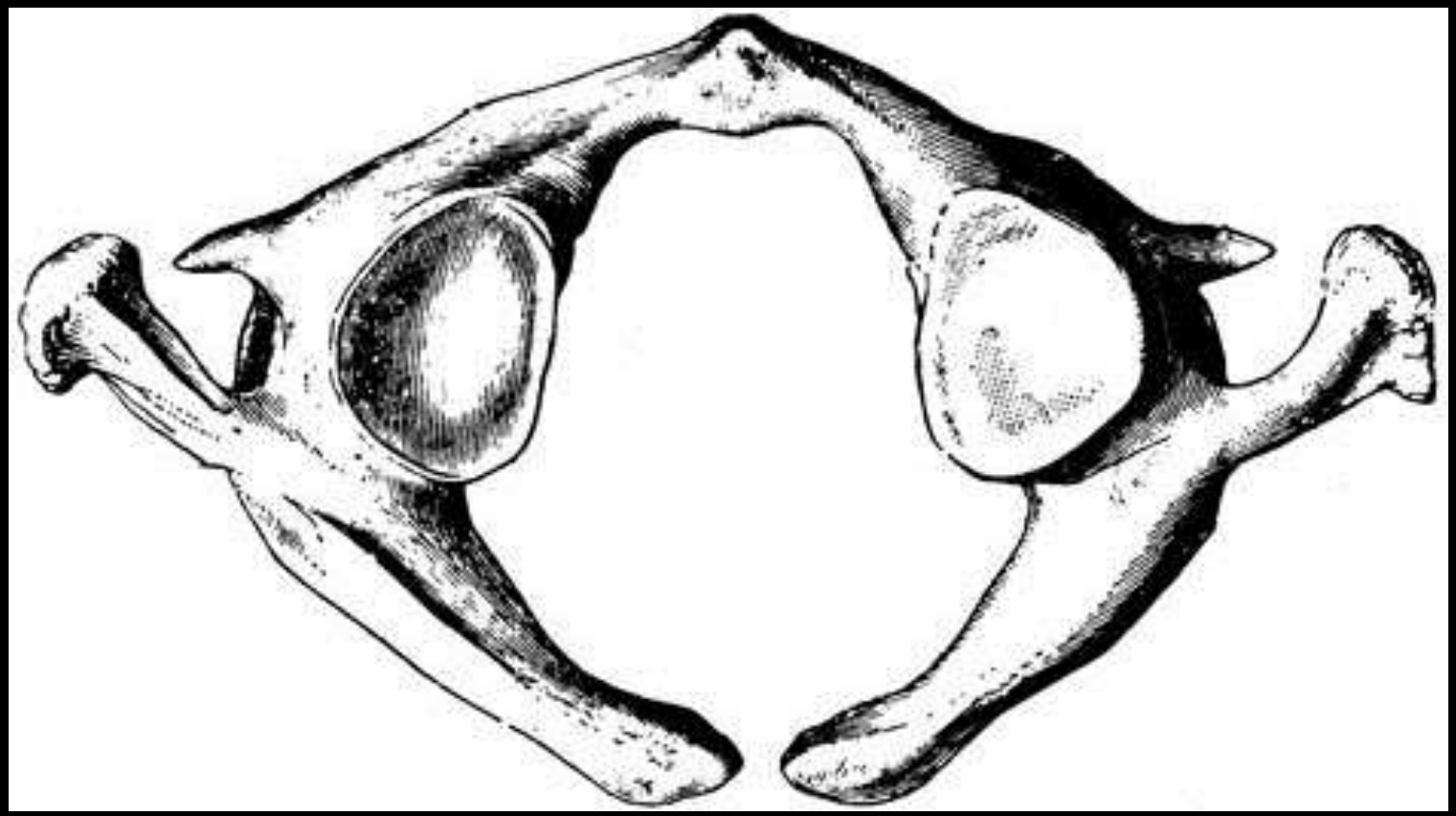

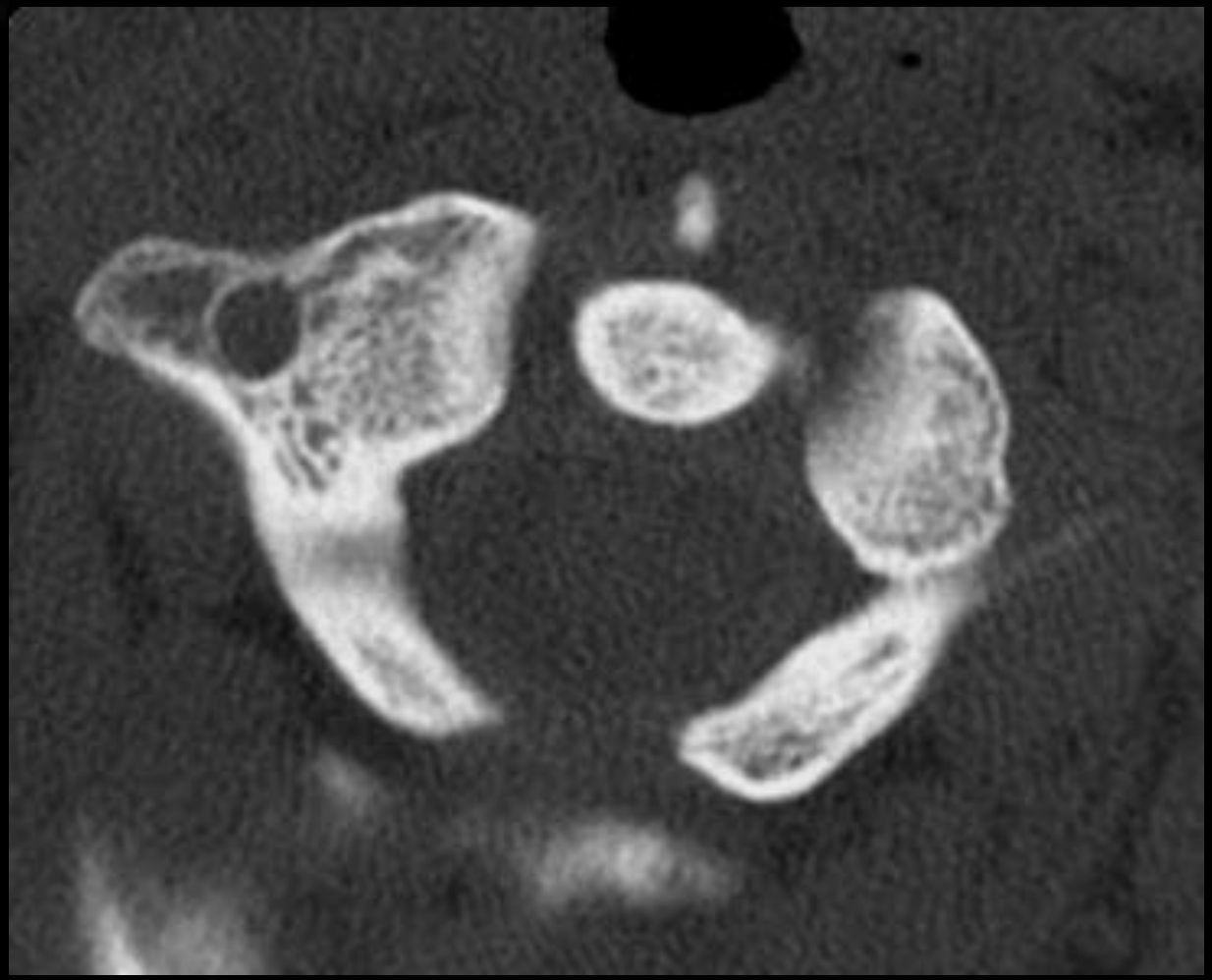

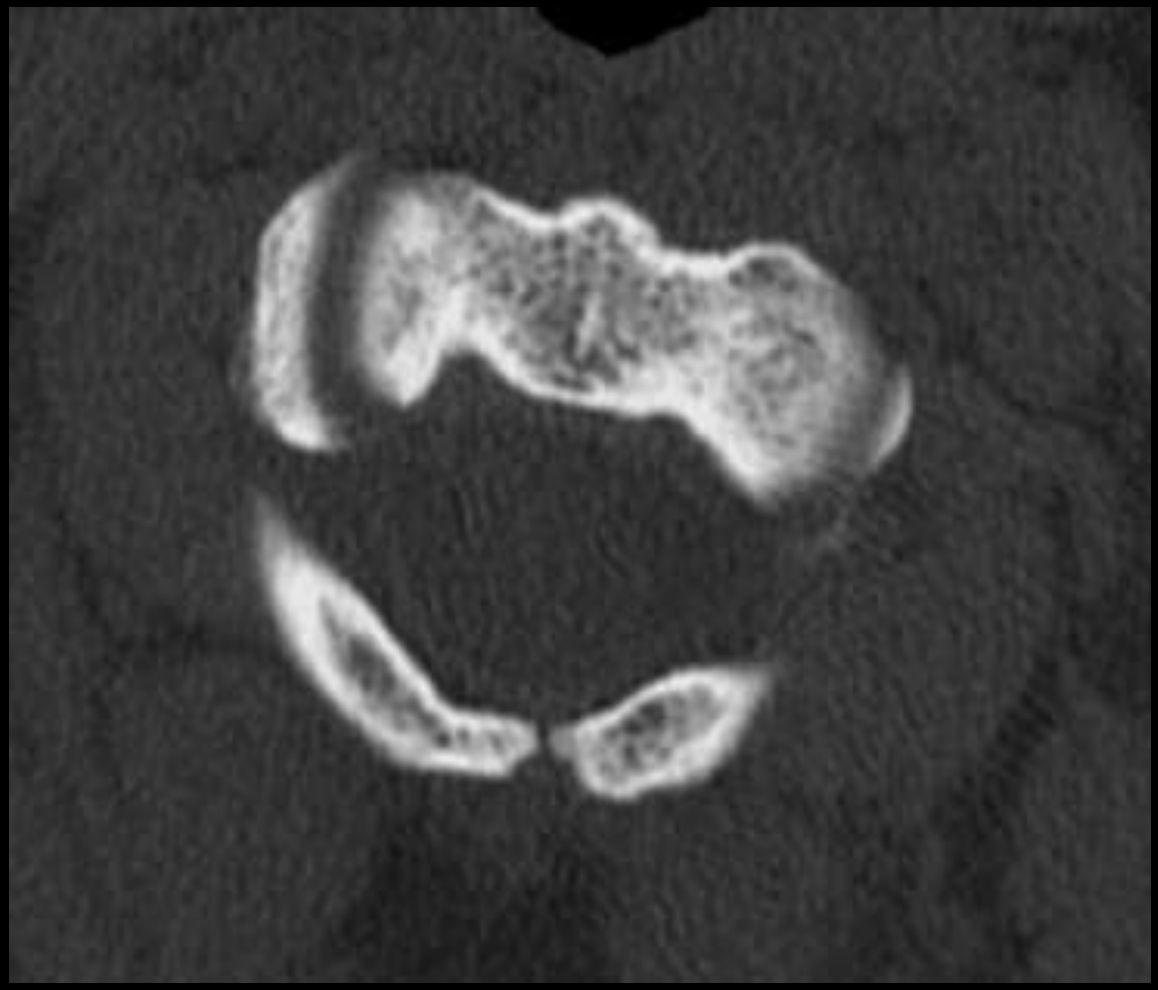

Axis

- Dens axis
- Attachments of alar ligaments
- Groove for transverse ligament
- Facet for anterior arch of atlas
- Foramen transversarium in transverse process

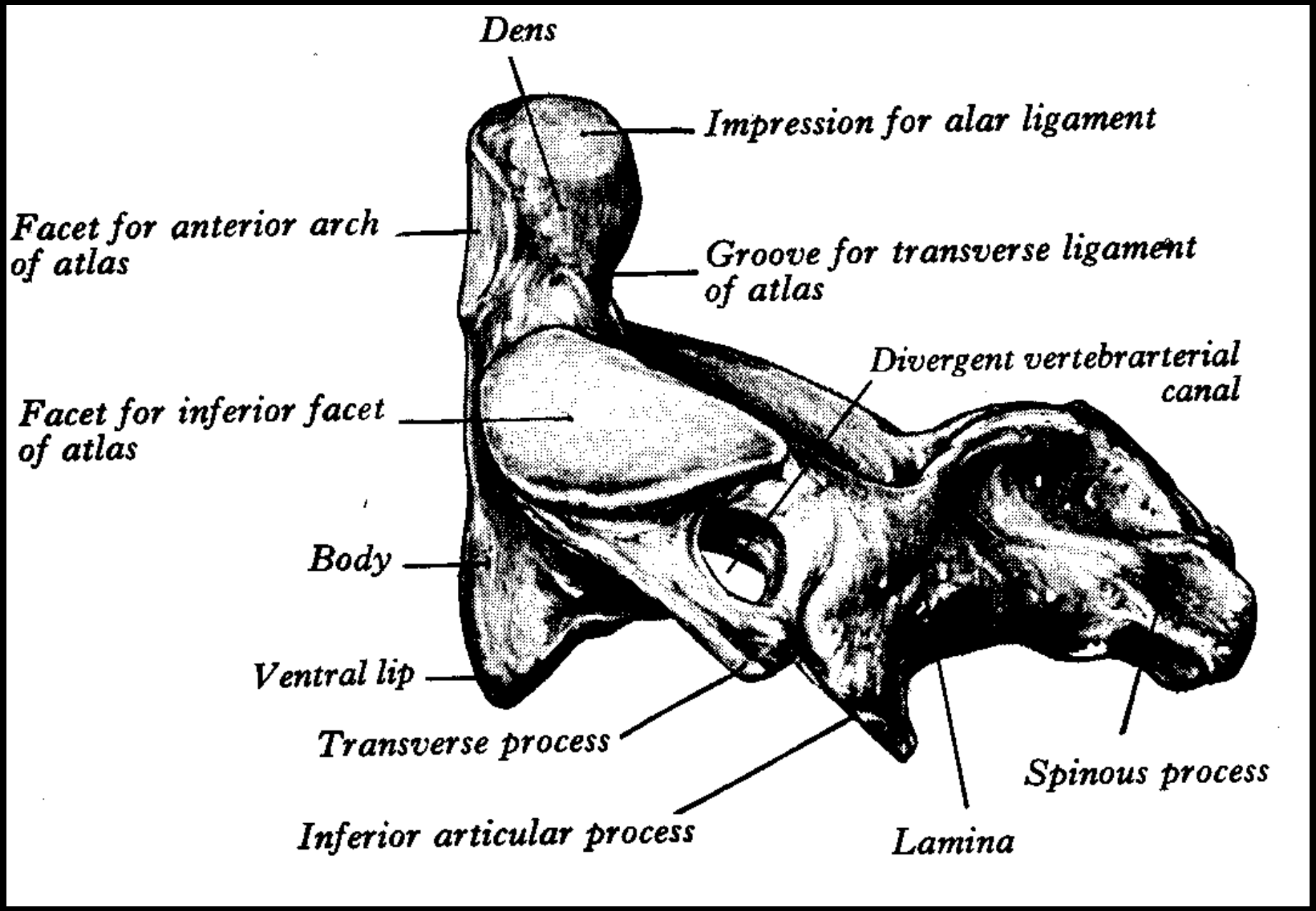

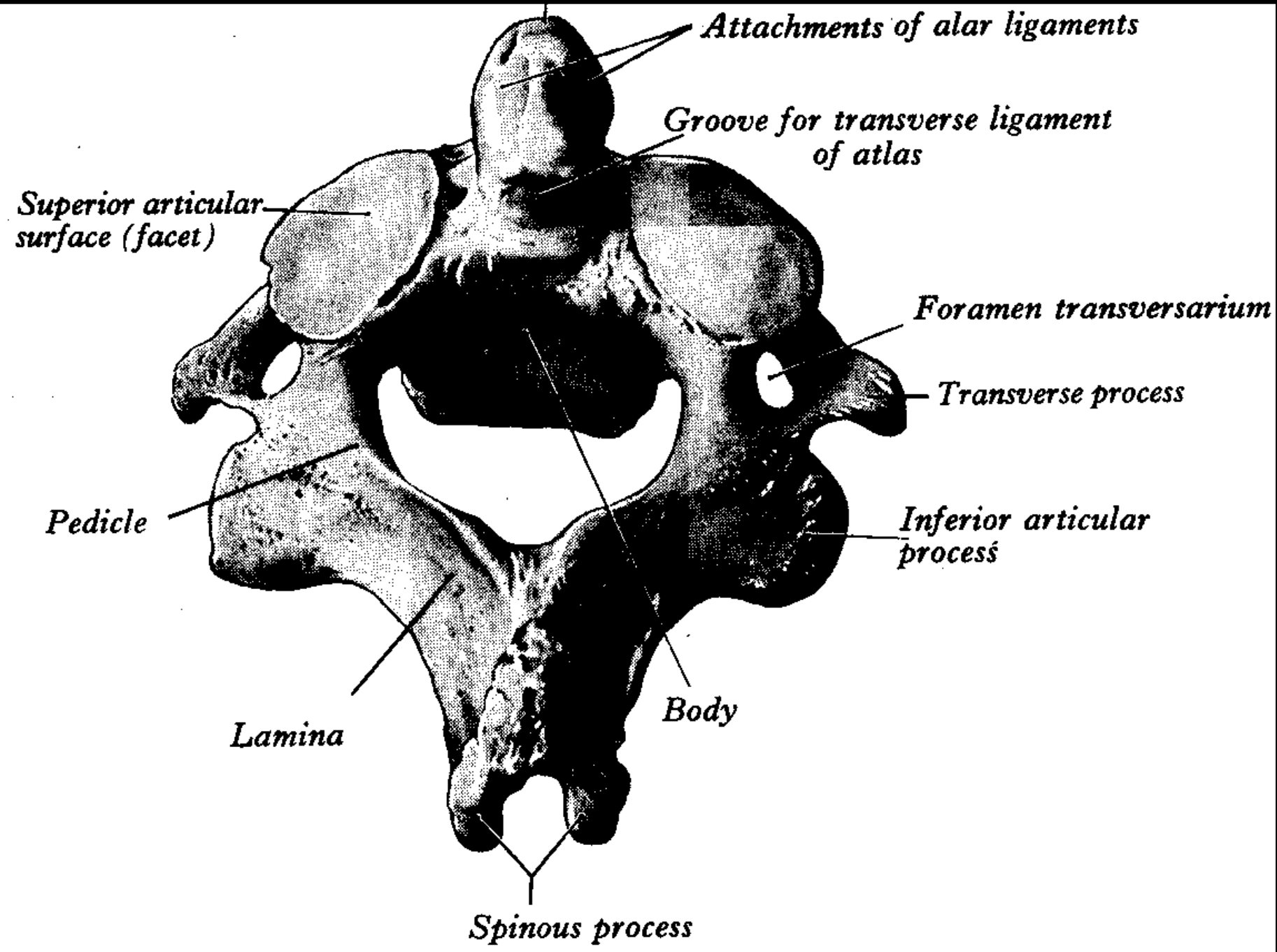

Henry Gray (1821–1865).

Anatomy of the Human Body. 1918.

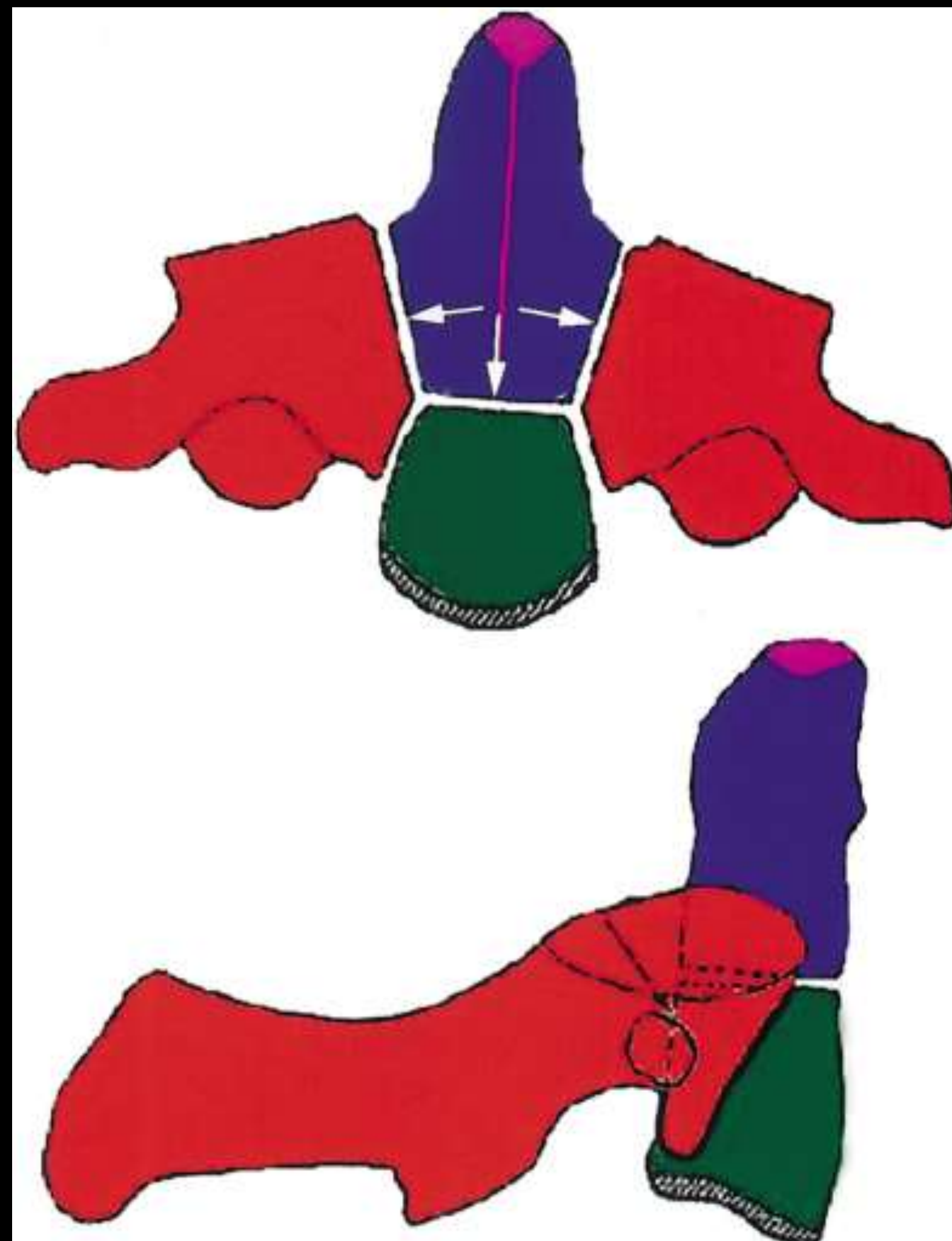

RadioGraphics

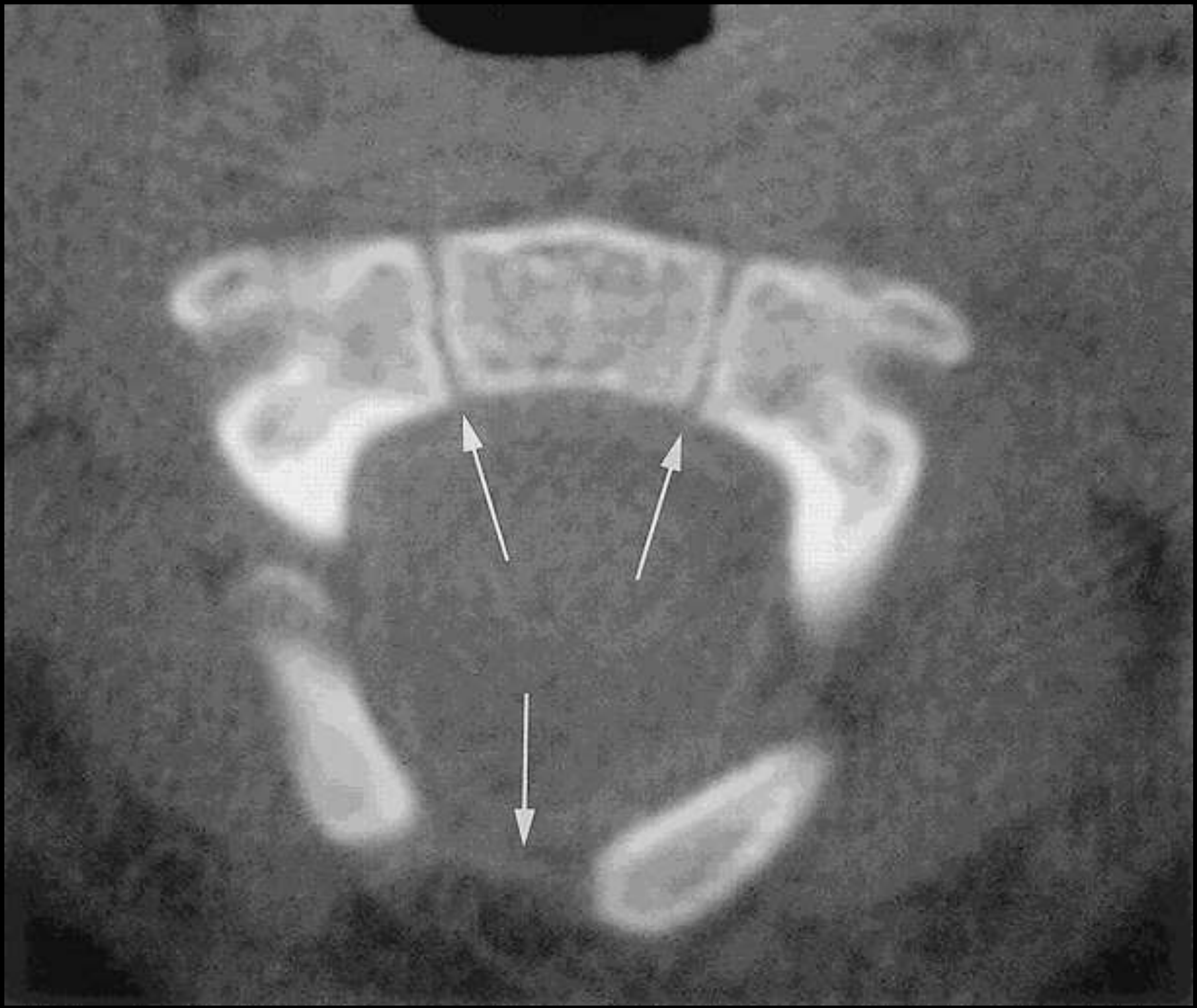

C1 Occipitilization

Atlas (C1), Axis (C2)

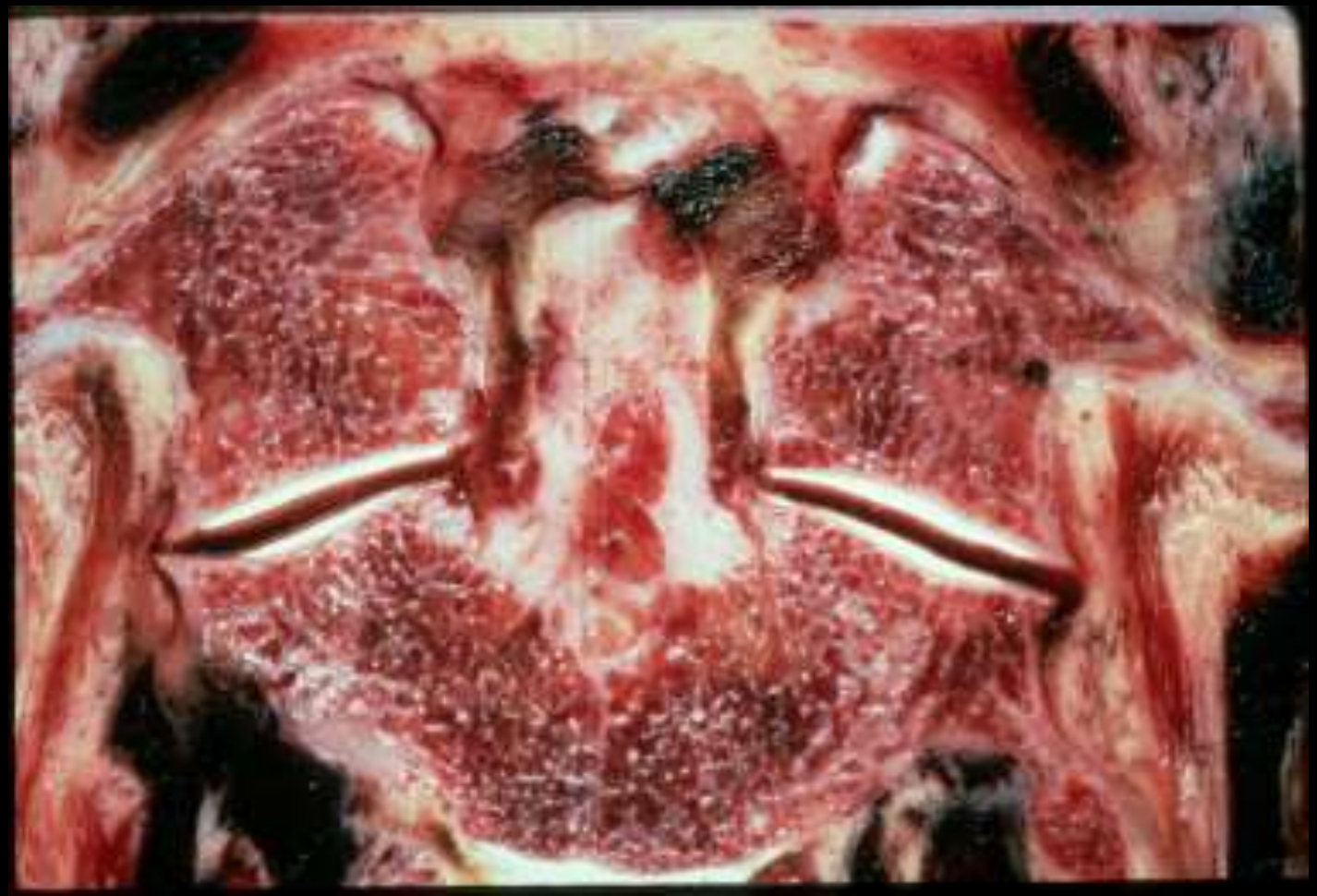

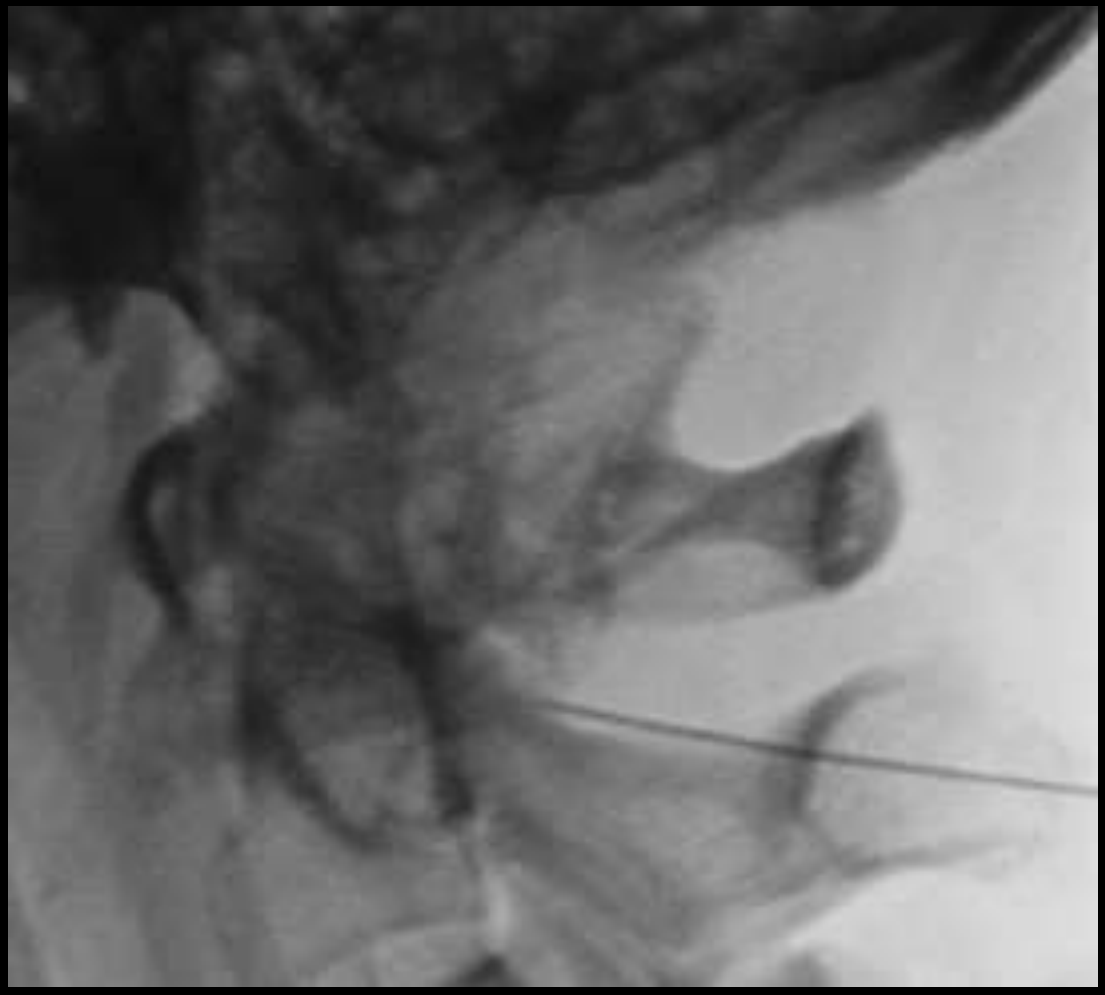

Vertebral body anatomy: CT

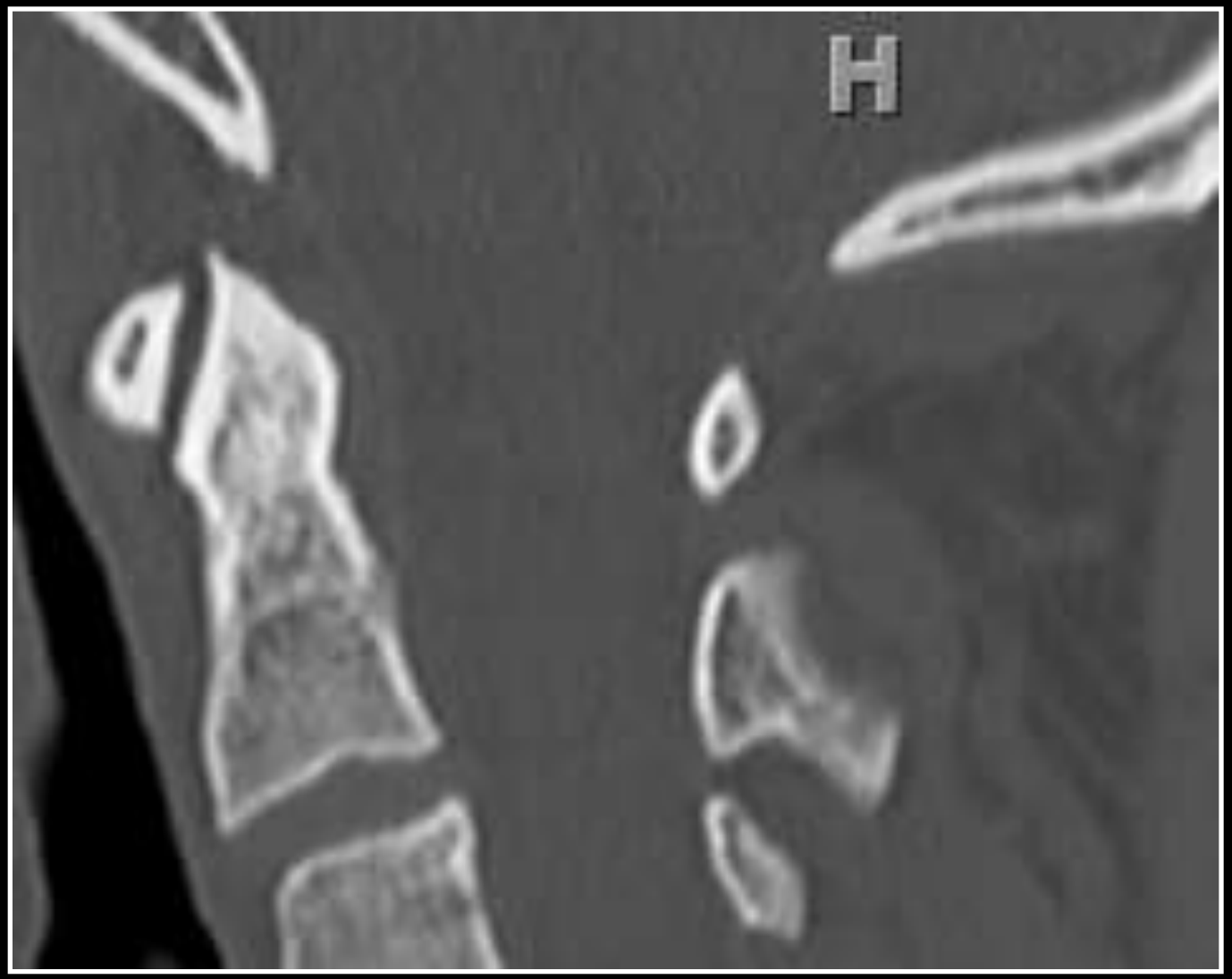

- Atlas and axis (C1 and C2)
- Unique vertebral bodies
- C1 has no spinous process or body
- C2 has a superior extension called the dens, or odontoid

Courtesy of Anna Nidecker and Ari Blitz

Vertebral body anatomy: CT

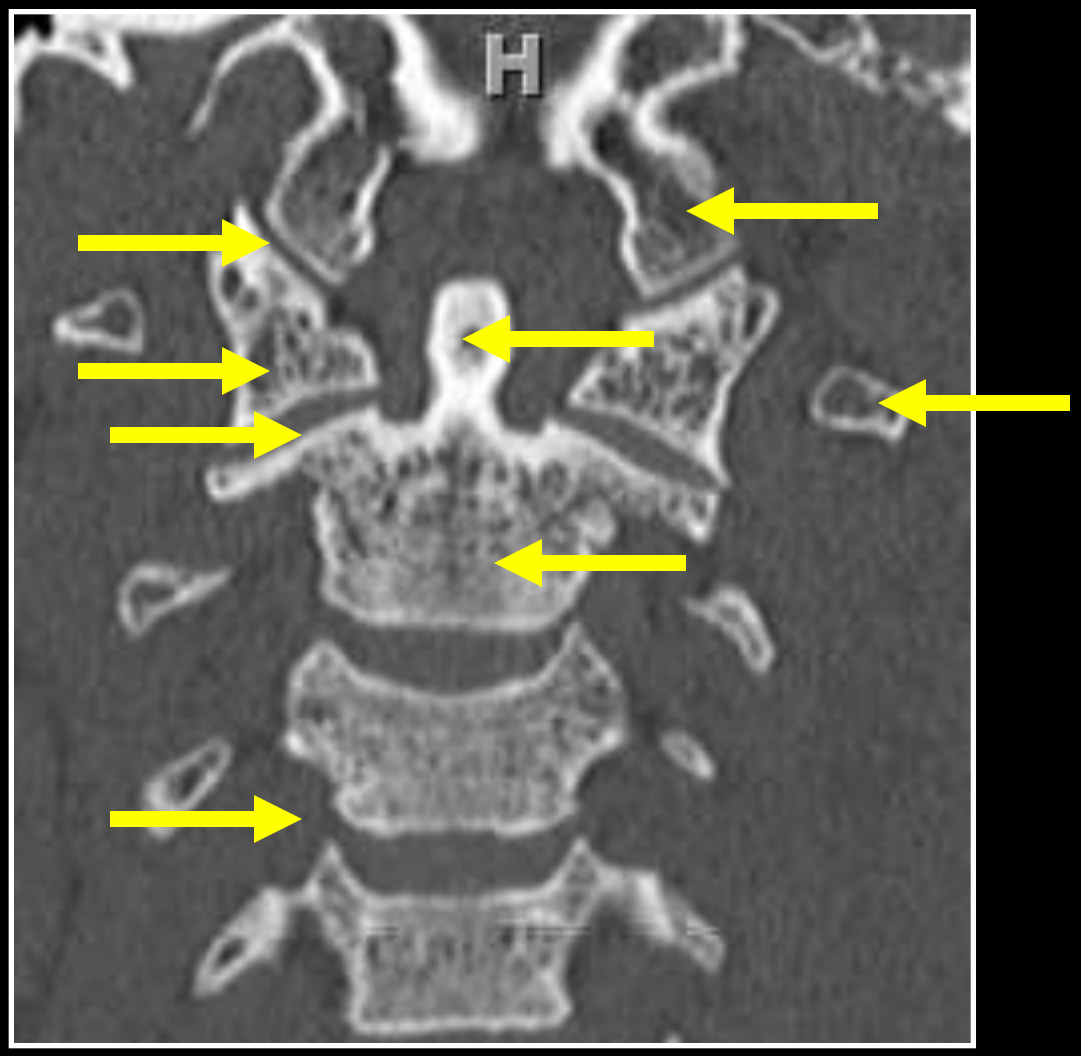

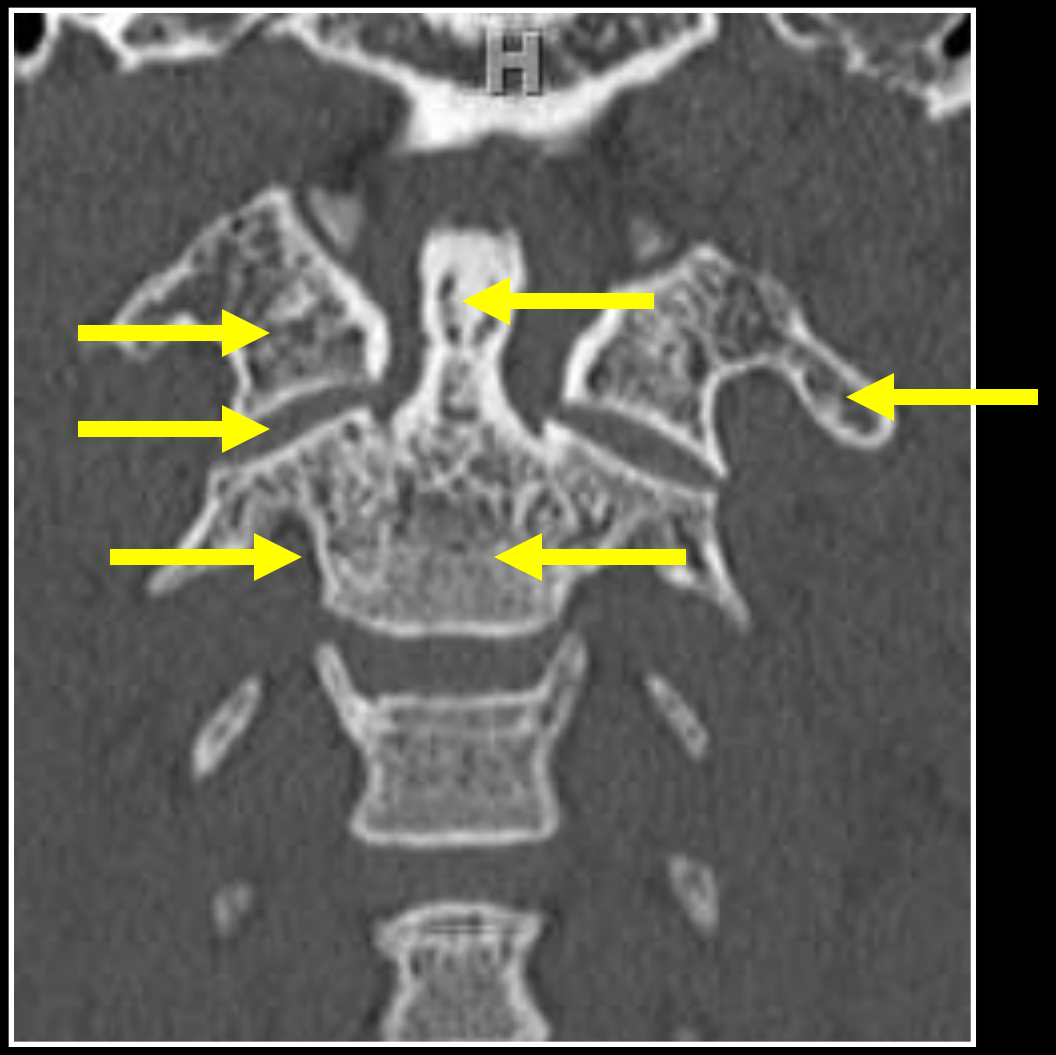

- Coronal: Axis and Atlas
  - Occipital condyle
  - Atlanto-occipital joint
  - C1 lateral mass
  - C1 transverse process
  - Dens/odontoid
  - Atlanto-axial joint
  - C2 vertebral body
  - Neural foramen

Courtesy of Anna Nidecker and Ari Blitz

Courtesy of Anna Nidecker and Ari Blitz

Vertebral body anatomy: CT

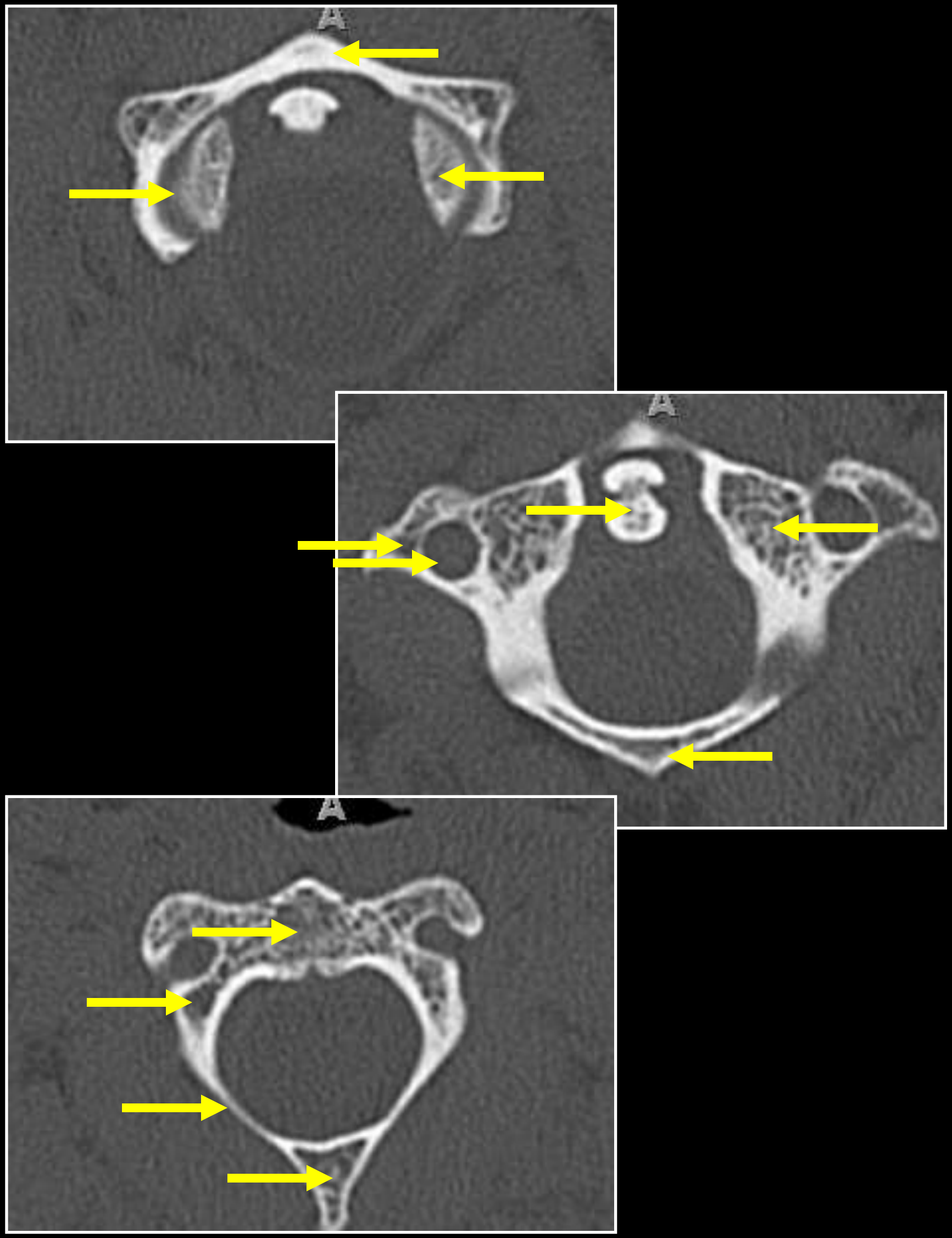

- Axial: Axis and Atlas
- Atlantooccipital joint
- Occipital condyle
- C1
  - Anterior arch
  - Lateral mass
  - Transverse process
  - Transverse foramen
  - Posterior arch
- C2
  - Dens/odontoid
  - Body
  - Pedicle, lamina, spinous process

Os Odontoideum

Anterior Arch Hyperplasia allows for Differentiation from Type II Odontoid Fracture

Associations:

- Down Syndrome, SED, Morquio’s, Klippel-Feil

Normal Variant: Os odontodium with pseudarthrosis and DJD

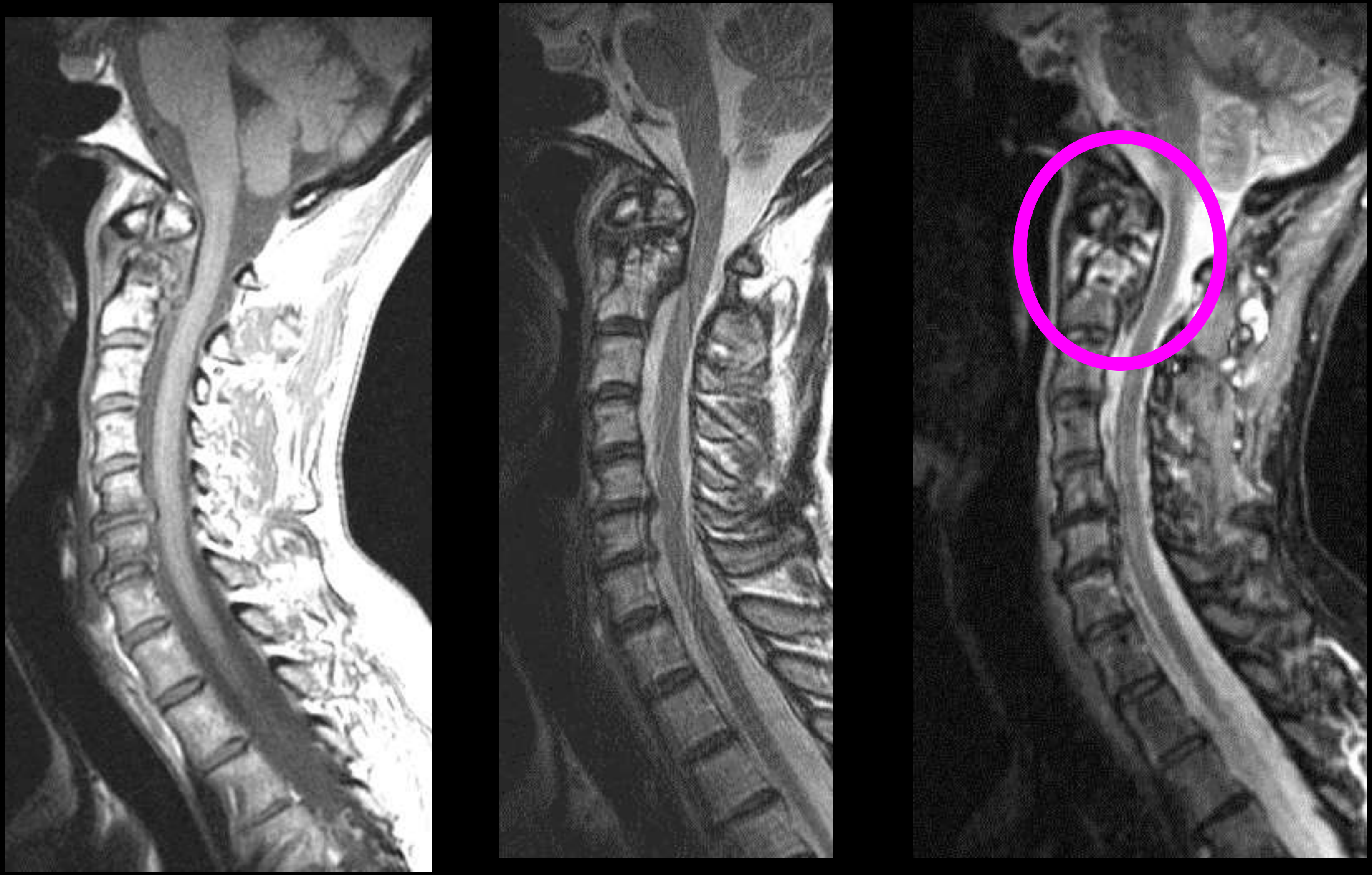

Chondrification centers

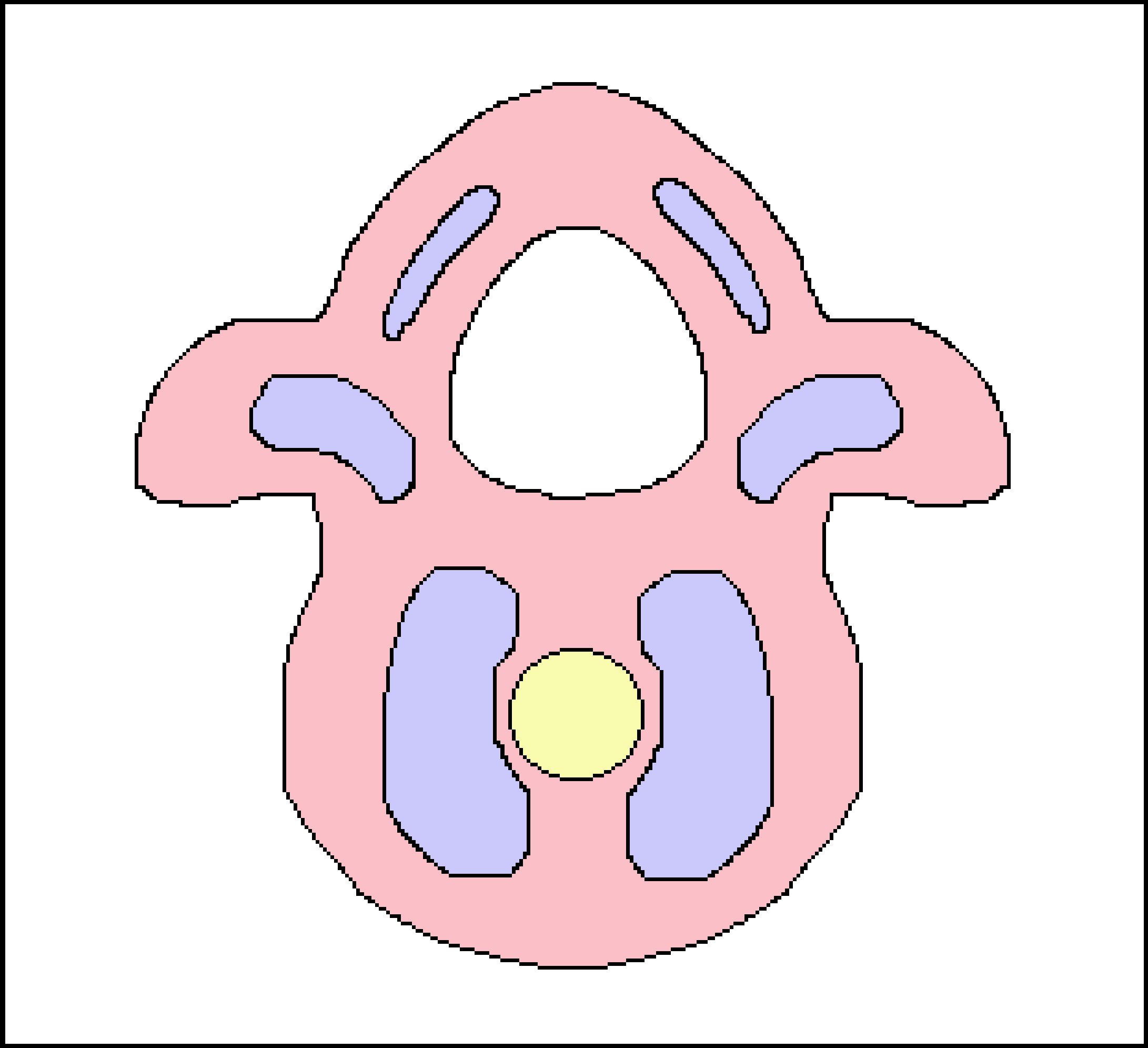

Ossification centers

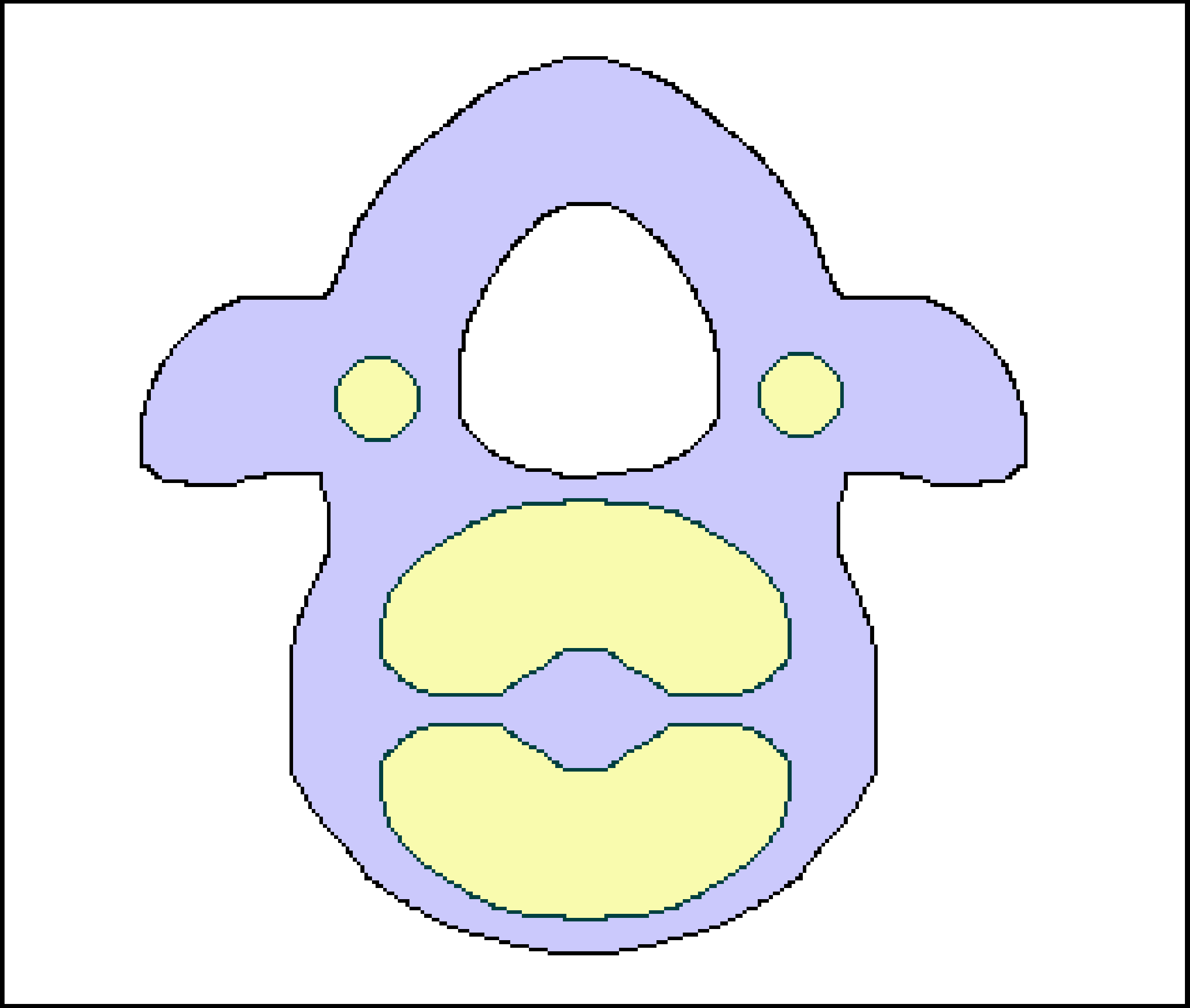

Primary ossification centers

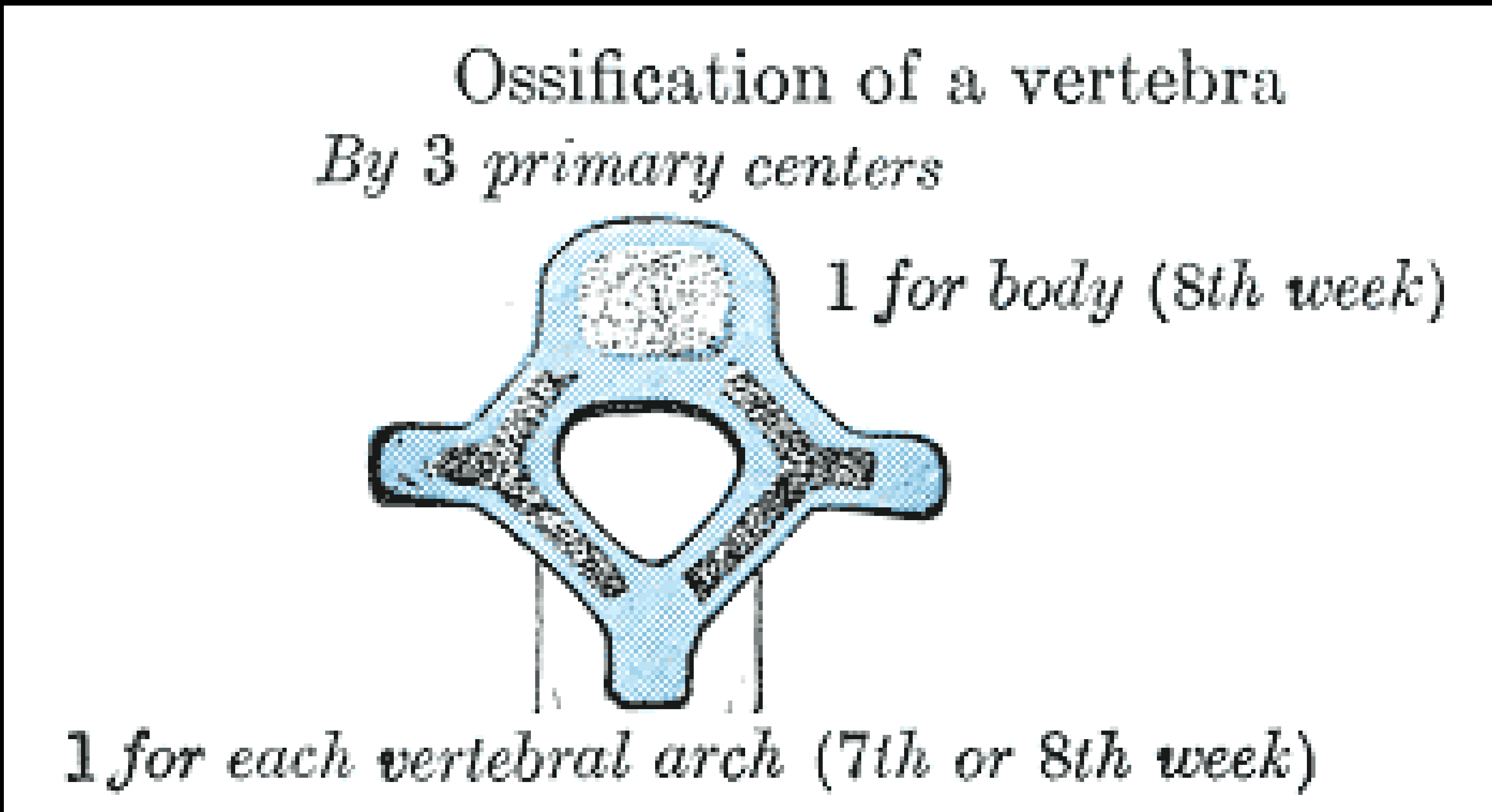

Henry Gray (1821–1865). Anatomy of the Human Body. 1918.

Secondary ossification centers

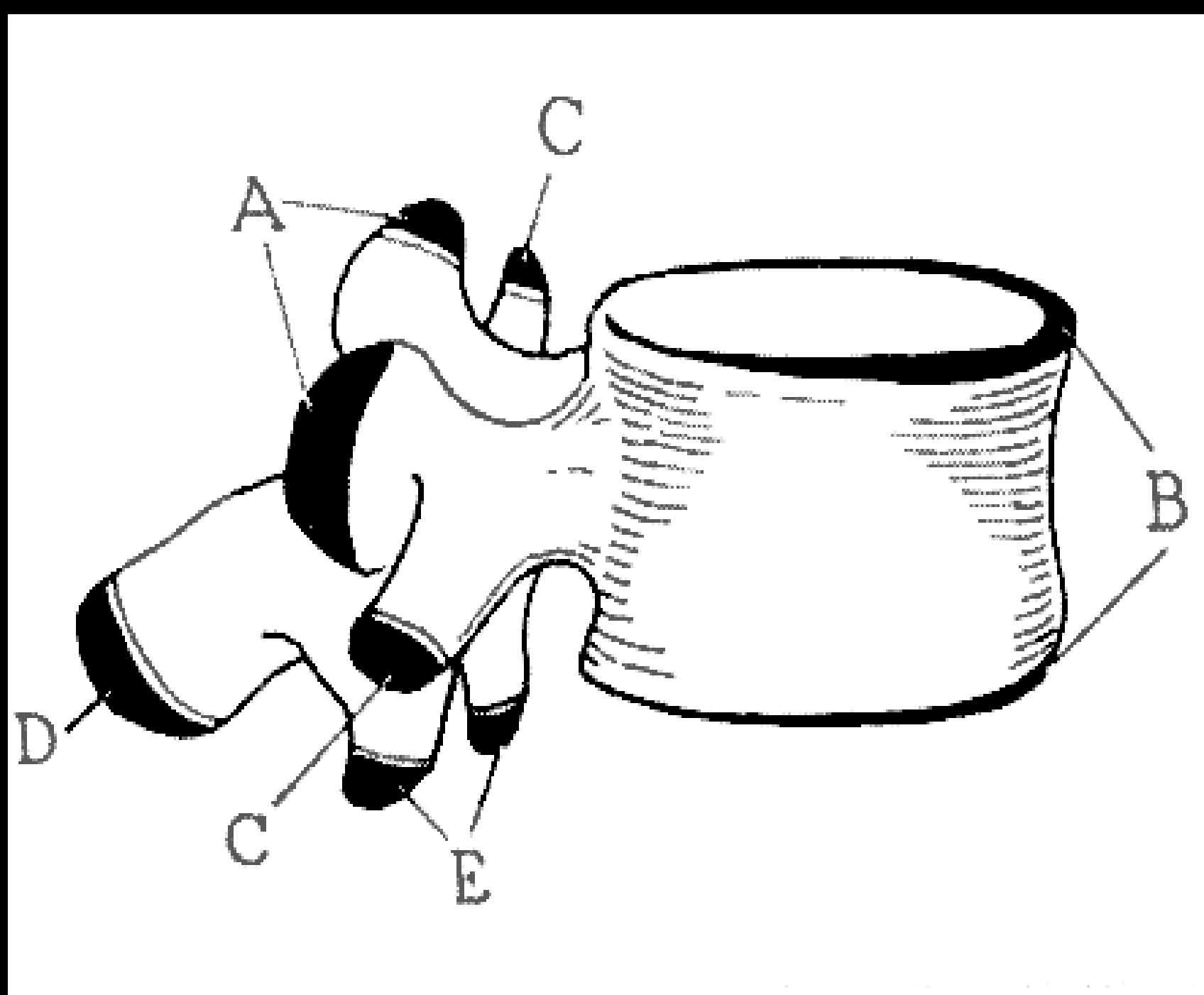

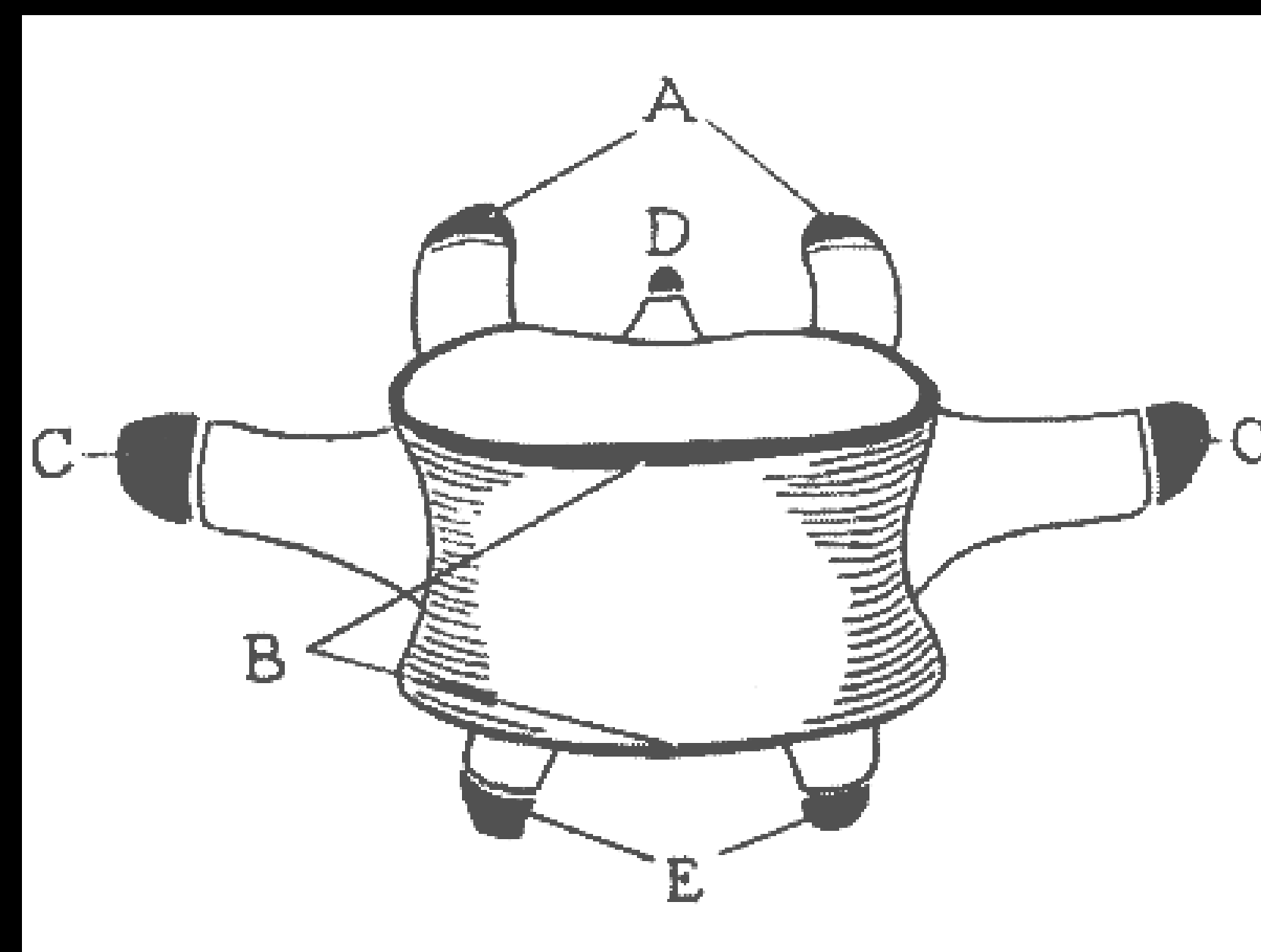

Longitudinal growth

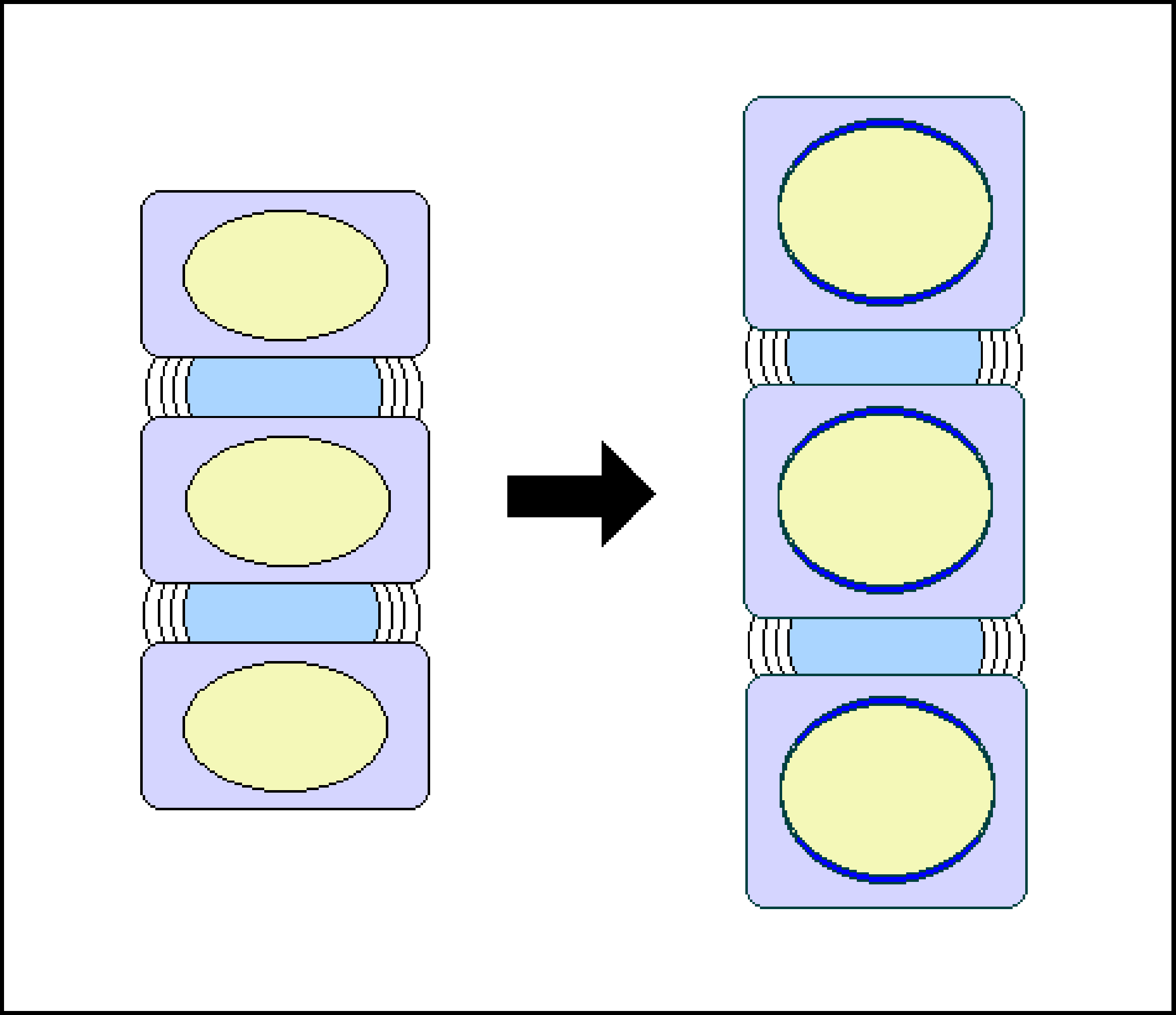

Sub -Axial Spine

C4

C7

Cervical Vertebrae (C3-7)

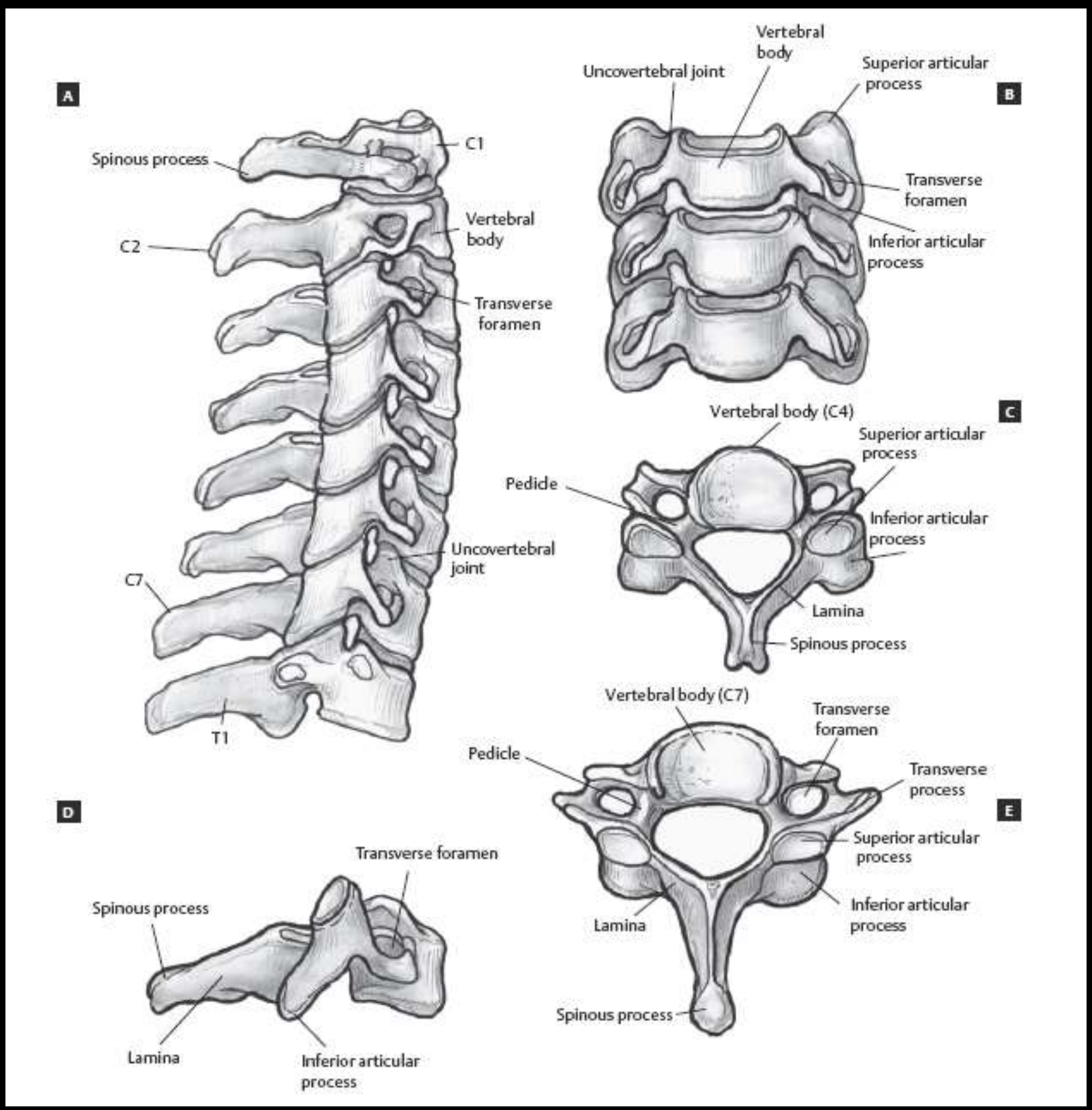

- Small but relatively broad bodies
- Large triangular vertebral foramen
- Raised lip on upper surface of body
- Ant. and post. tubercle of transverse process
- Foramen transversarium (C7 no vertebral artery !)
- Short bifid spinous processes

Khanna AJ, ed. MRI for Orthopaedic Surgeons. 2010.

Vertebral body anatomy: Radiography

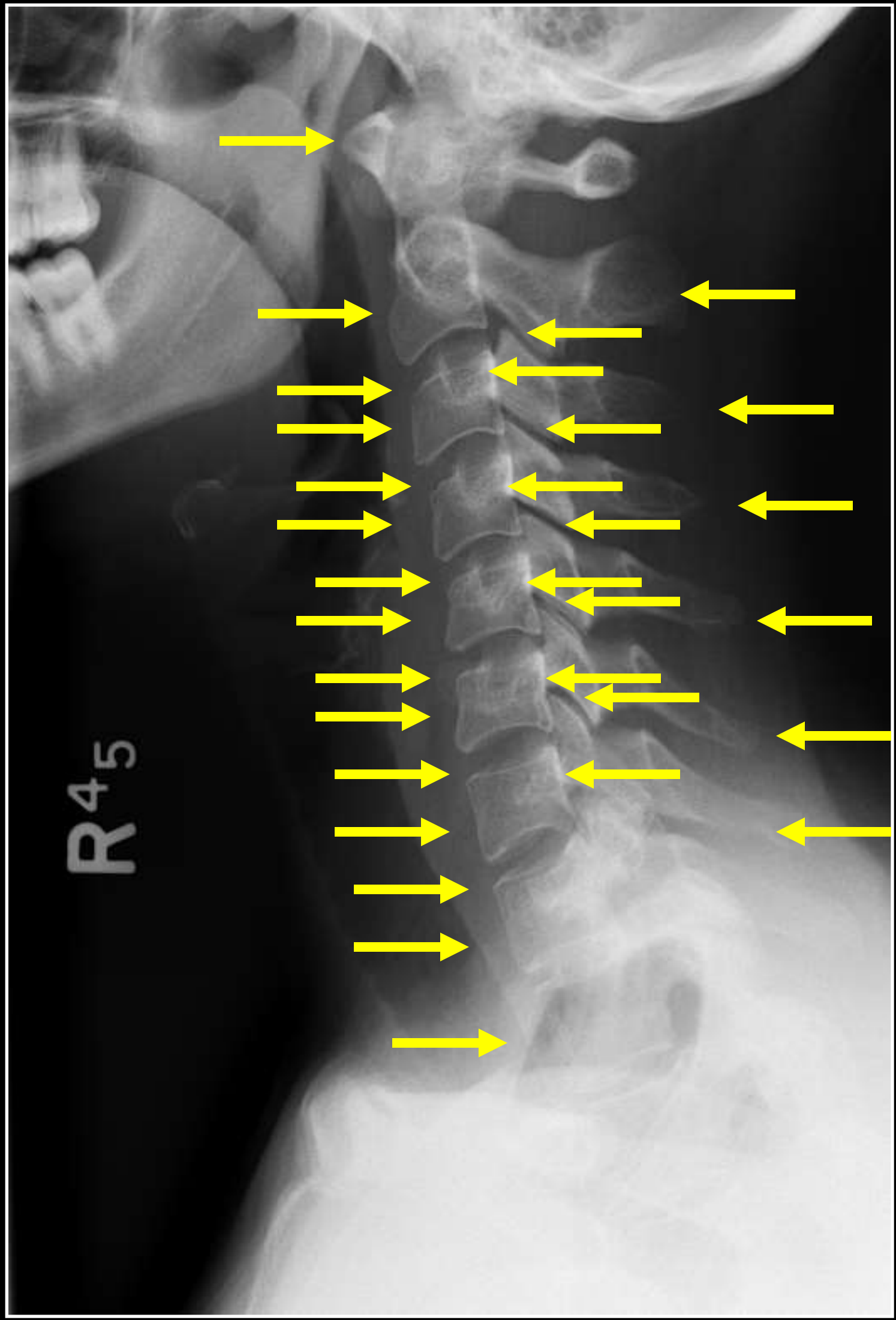

- Lateral:
  - Atlas
  - Axis (dens)
  - Vertebral bodies (Cervical)
  - Vertebral bodies (Thoracic)
  - Disc spaces
  - Facet joints
  - Spinous processes
  - Transverse process

Courtesy of Anna Nidecker and Ari Blitz

Cervical Vertebrae (C3-7)

- Uncinate process
  - Osseous projection off of the superolateral aspect of the vertebral body
  - Articulates with beveled inferolateral aspect of the supradjacent vertebral body to form the uncovertebral joint
- Uncovertebral joint(Joint of Luschka)
  - Unique to the cervical spine
  - Part of the disc, not a synovial joint
  - Frequent location of degeneration

Sub-Axial Cervical Spine: Uncinate Processess

Developmental Variants: C-spine

- Subdental synchondrosis
- Accessory ossicle of C1 arch
  - Ununited C1 apophysis
- Incomplete fusion C1 arch
  - anterior
  - posterior
- Occipitalization of C1 (Cervical occipital fusion)
  - C1 lateral masses fuse with occipital condyles
- Congenital block vertebrae
- Bifid spinous process

Congenital Block Vertebrae

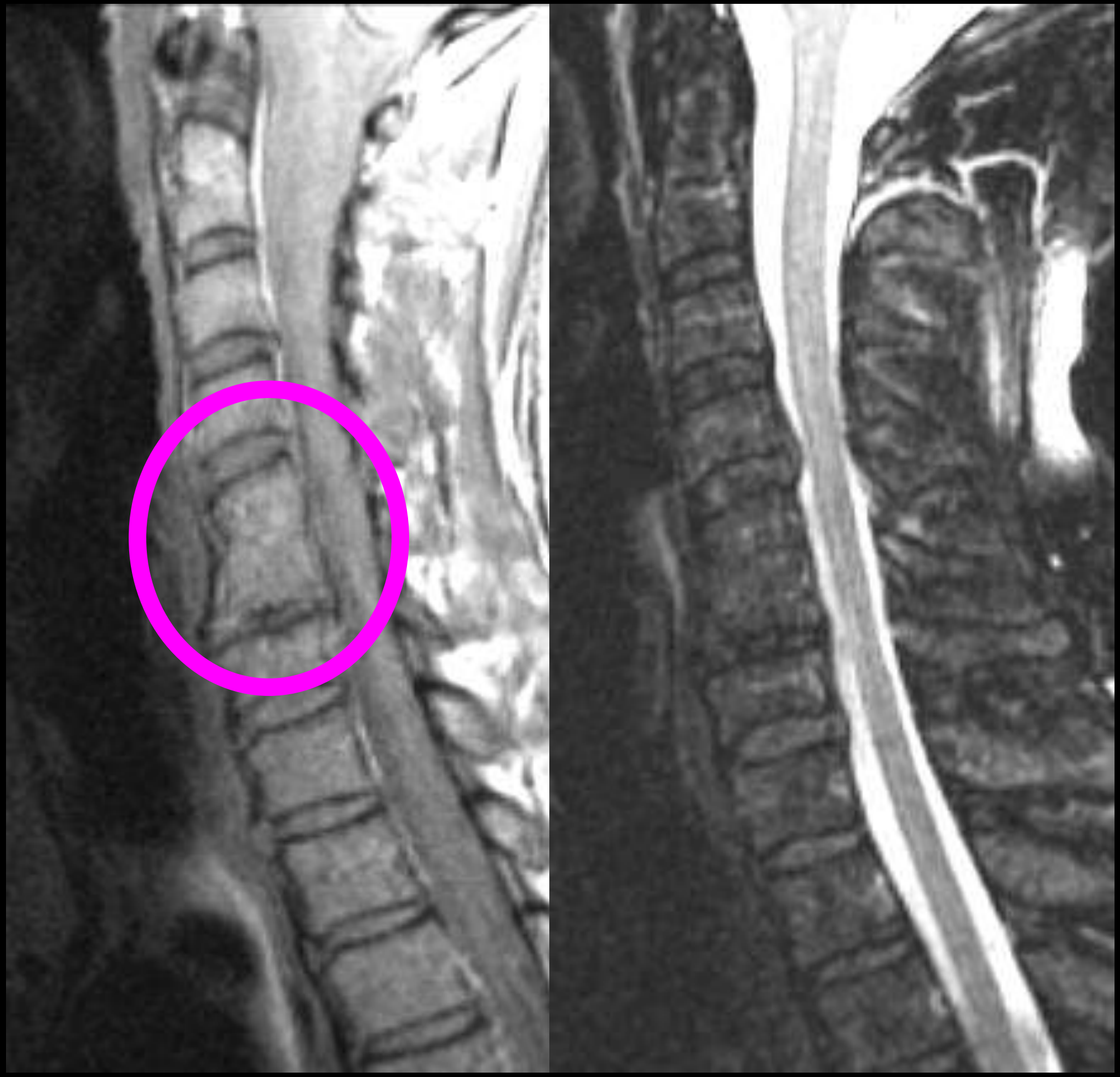

Bifid Spinous Process

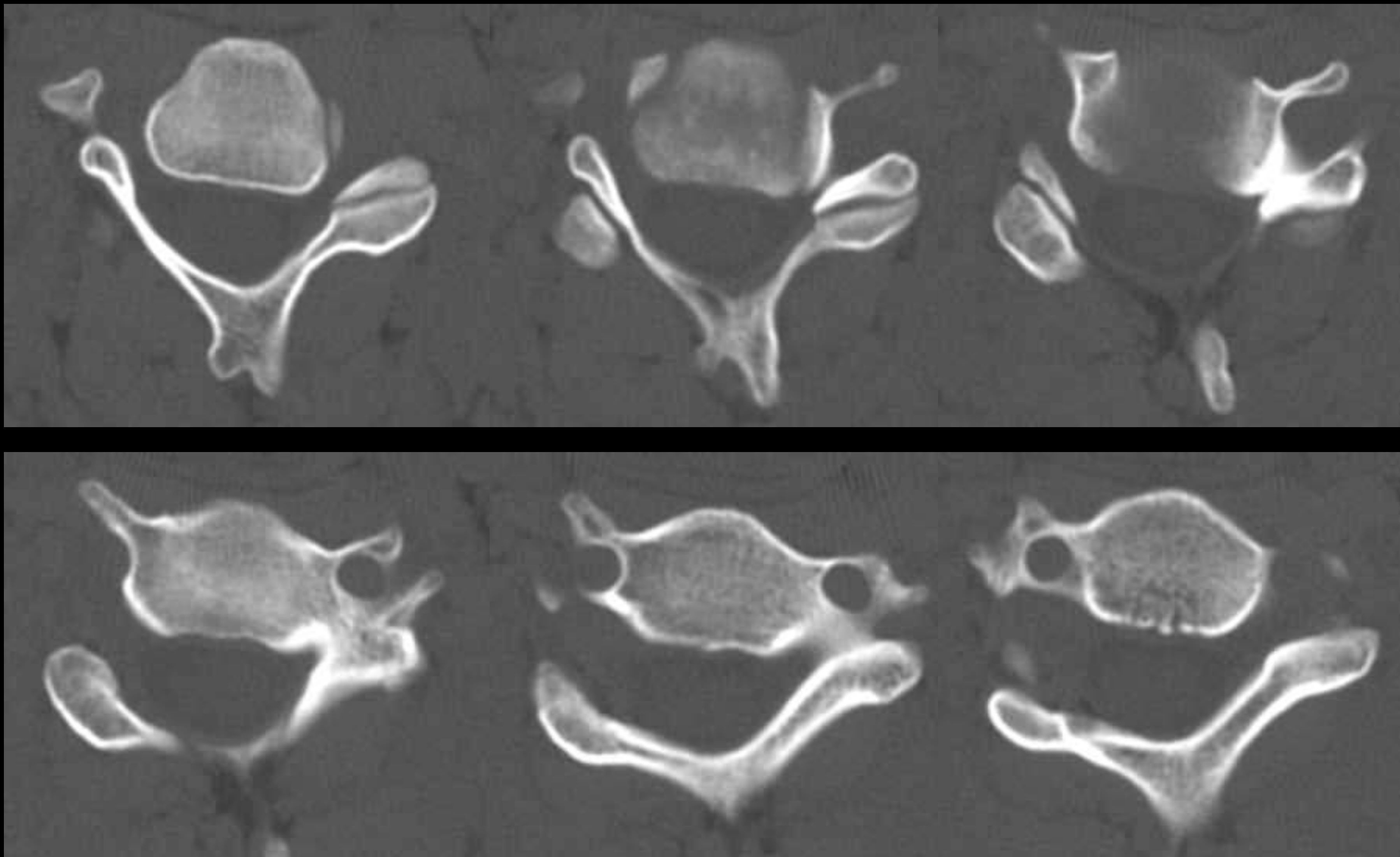

Congenital Pedicle Absence

Lumbar Vertebrae

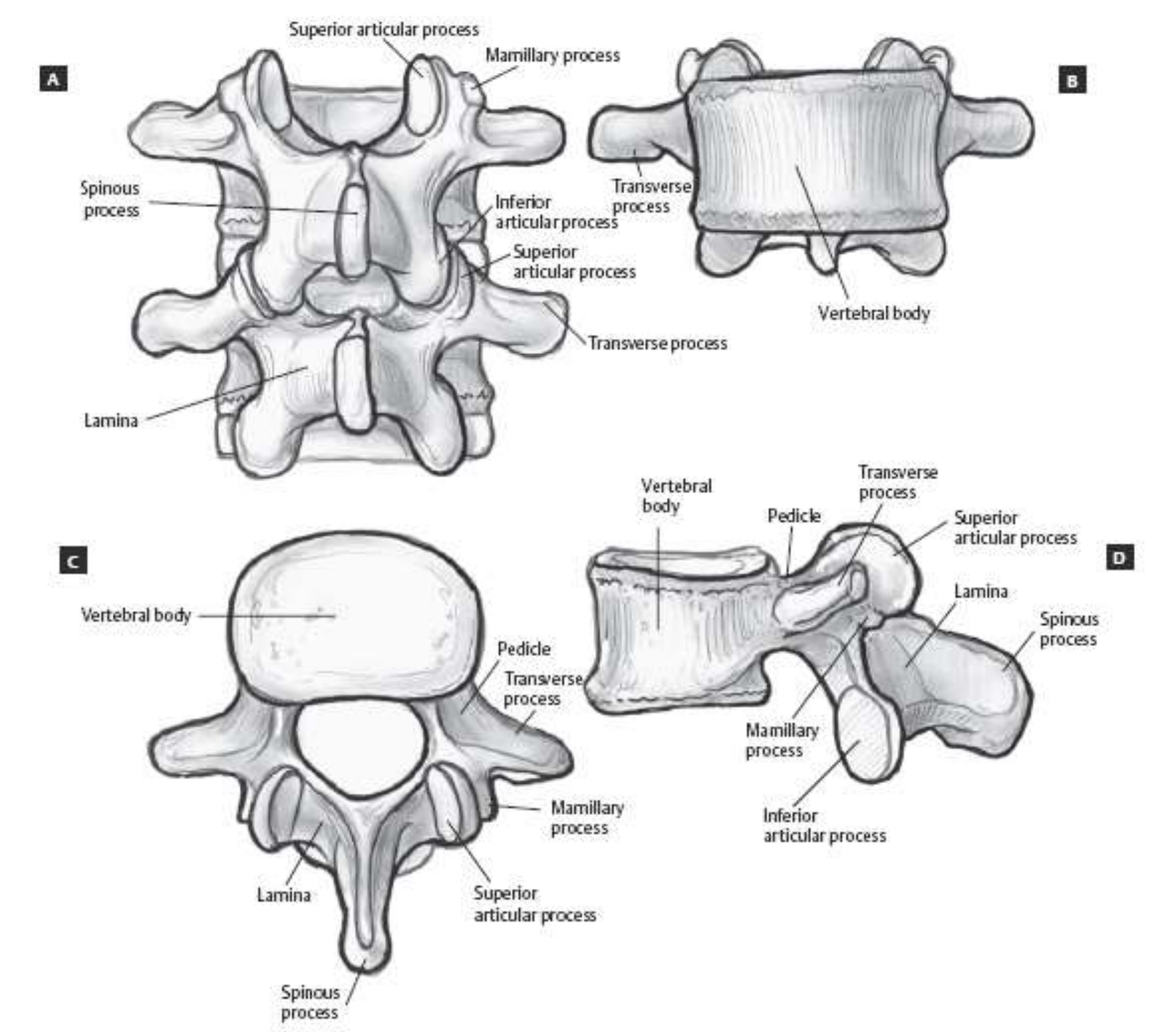

- Large bodies
- Most often triangular foramen
- Transverse processes thin and long
- Superior articular facets often concave
- Inferior articular facets often convex
- 5th. lumbar vertebra has largest body which is markedly deeper in front

Khanna AJ, ed. MRI for Orthopaedic Surgeons. 2010.

Vertebral body anatomy: Radiography

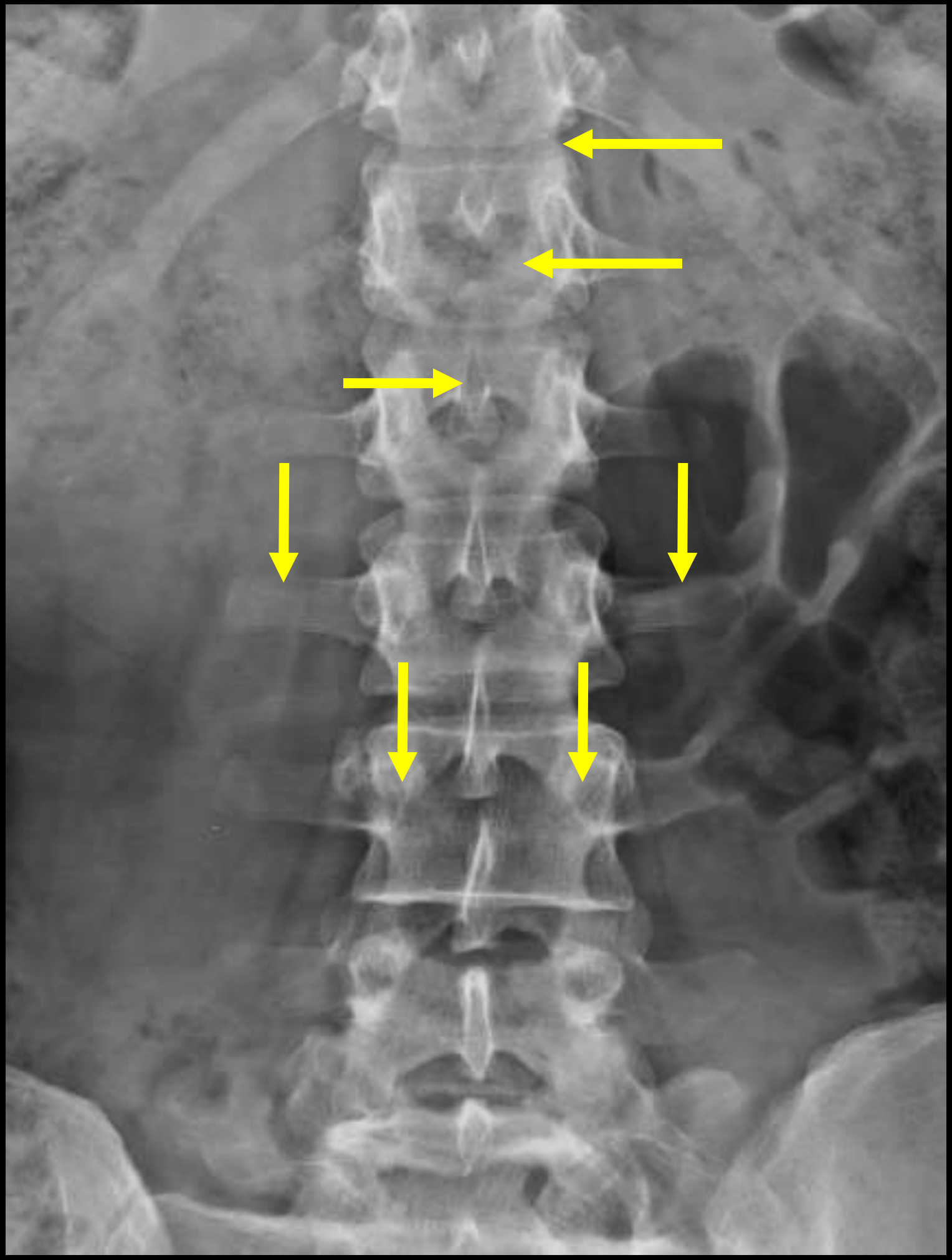

- AP:
  - Pedicles
  - Spinous process
  - Transverse processes
  - Vertebral body
  - Disc space

Courtesy of Anna Nidecker and Ari Blitz

Vertebral body anatomy: CT

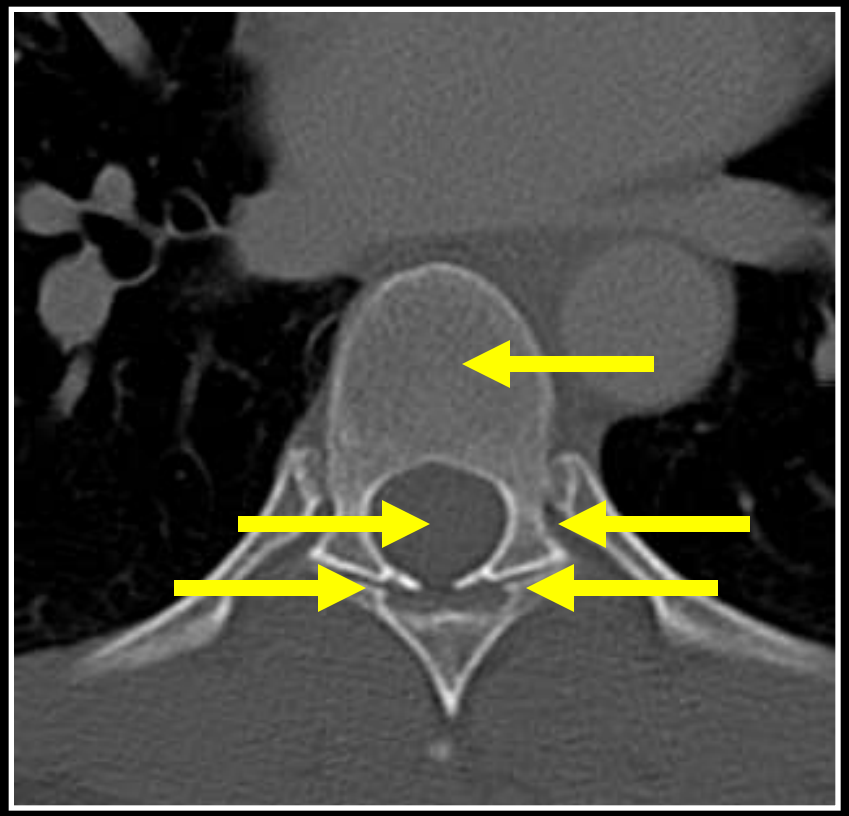

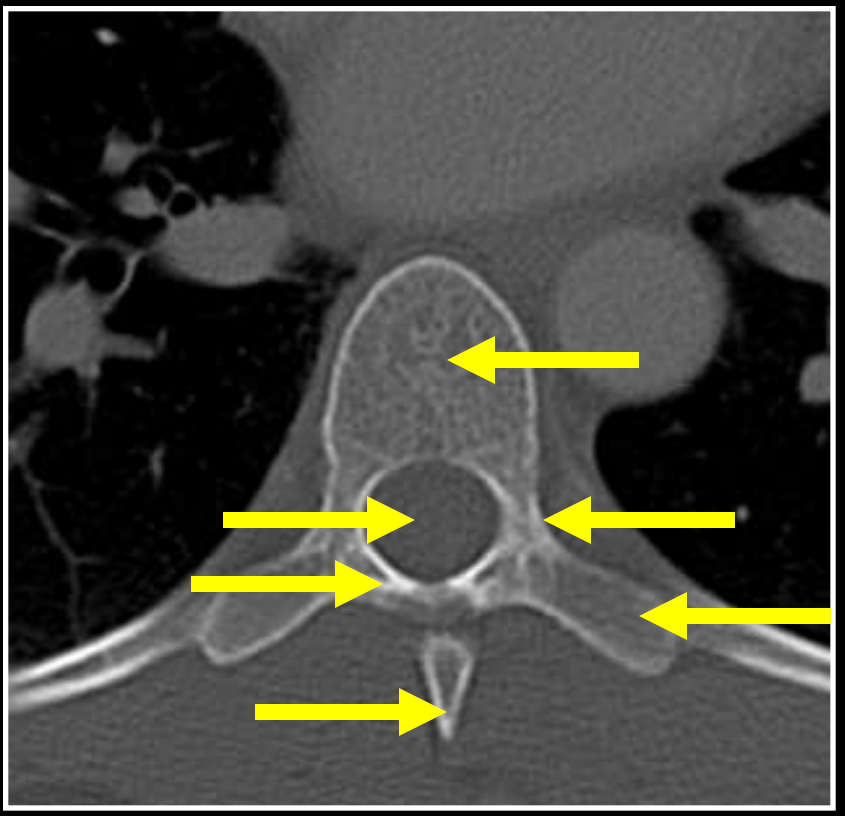

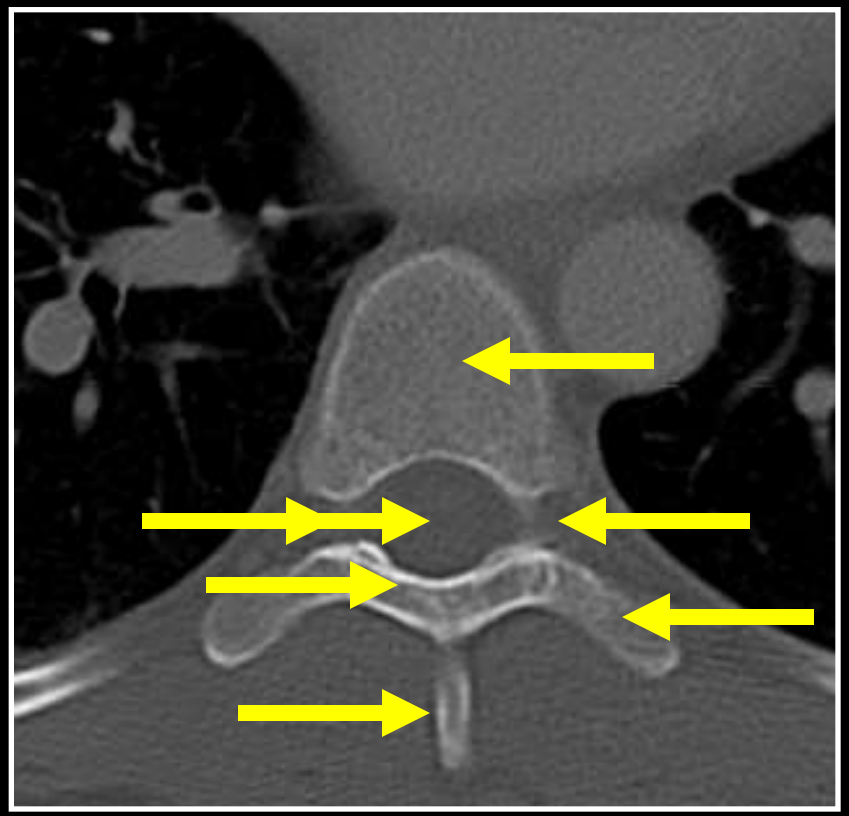

- Axial (thoracic spine)
- Vertebral body components:
  - Body
  - Pedicles
  - Transverse processes
  - Laminae
  - Spinous process
  - Facet joints
  - Central canal
  - Neural foramen

Courtesy of Anna Nidecker and Ari Blitz

Vertebral body anatomy: CT

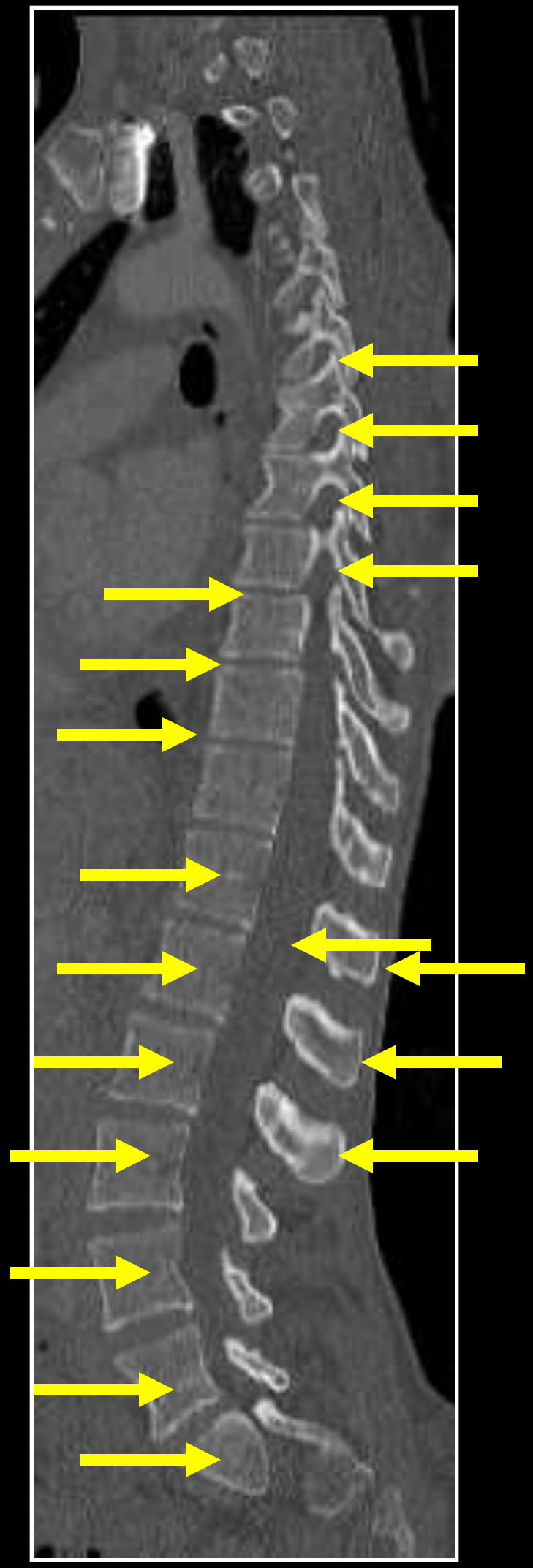

Courtesy of Anna Nidecker and Ari Blitz

- Sagittal (t and l spine)
- Vertebral components
  - – Bodies
    - Thoracic (T12)
    - Lumbar (L1-L5)
  - – Sacrum
  - – Discs
  - – Spinous process
  - – Facet joint
  - – Central canal
  - – Neural foramen

Vertebral body anatomy: CT

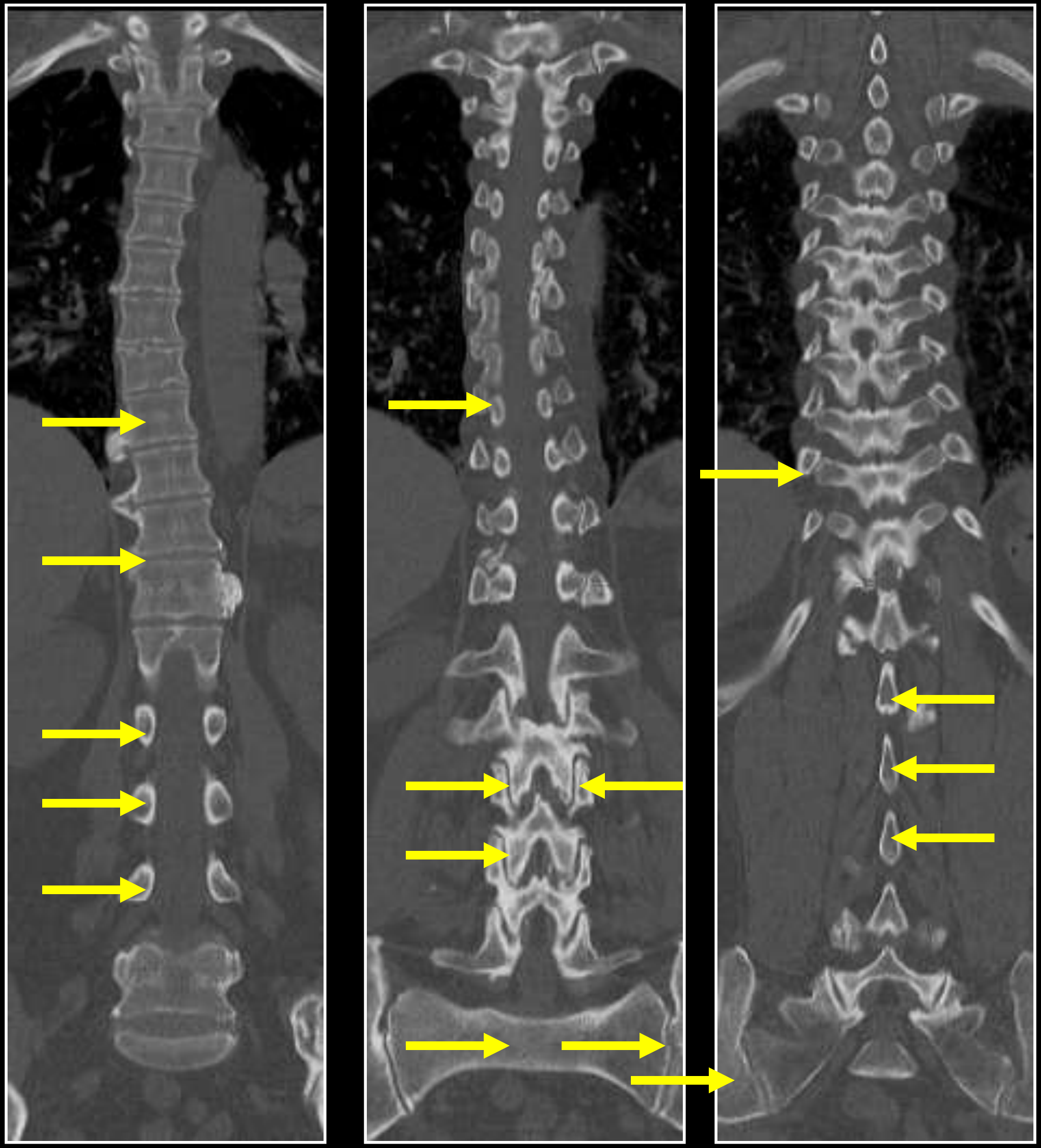

- Coronal (t and l spine)
- Vertebral components
  - Thoracic
    - Body, disc
    - Costovertebral joint
    - Costotransverse joint
  - Lumbar
    - Superior and Inferior articular facets
    - Facet joint
    - Pedicles
    - Spinous processes
  - Sacrum, Ilium, SI joint

Courtesy of Anna Nidecker and Ari Blitz

Ring Apophyses: MRI

- Need MRI

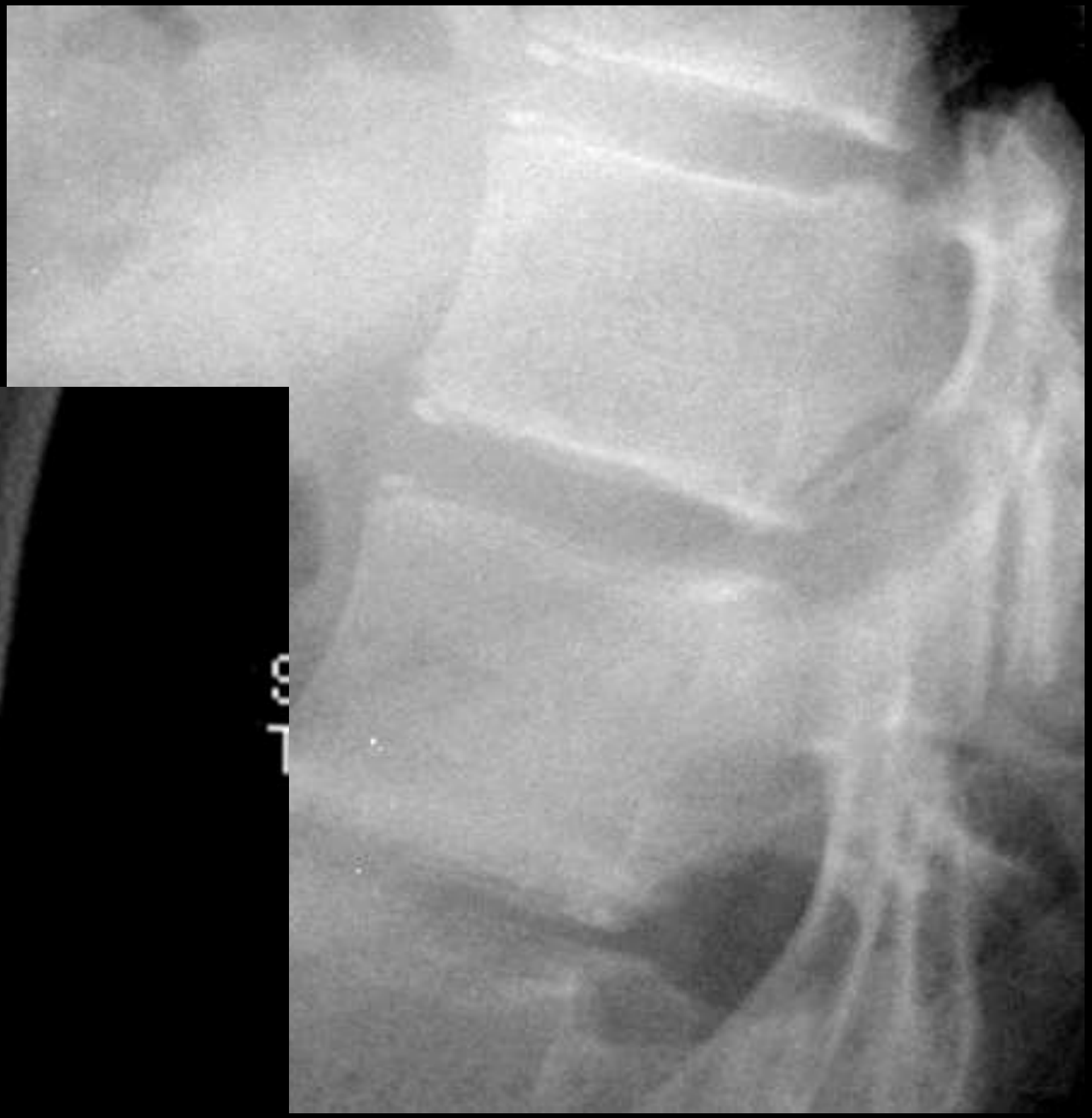

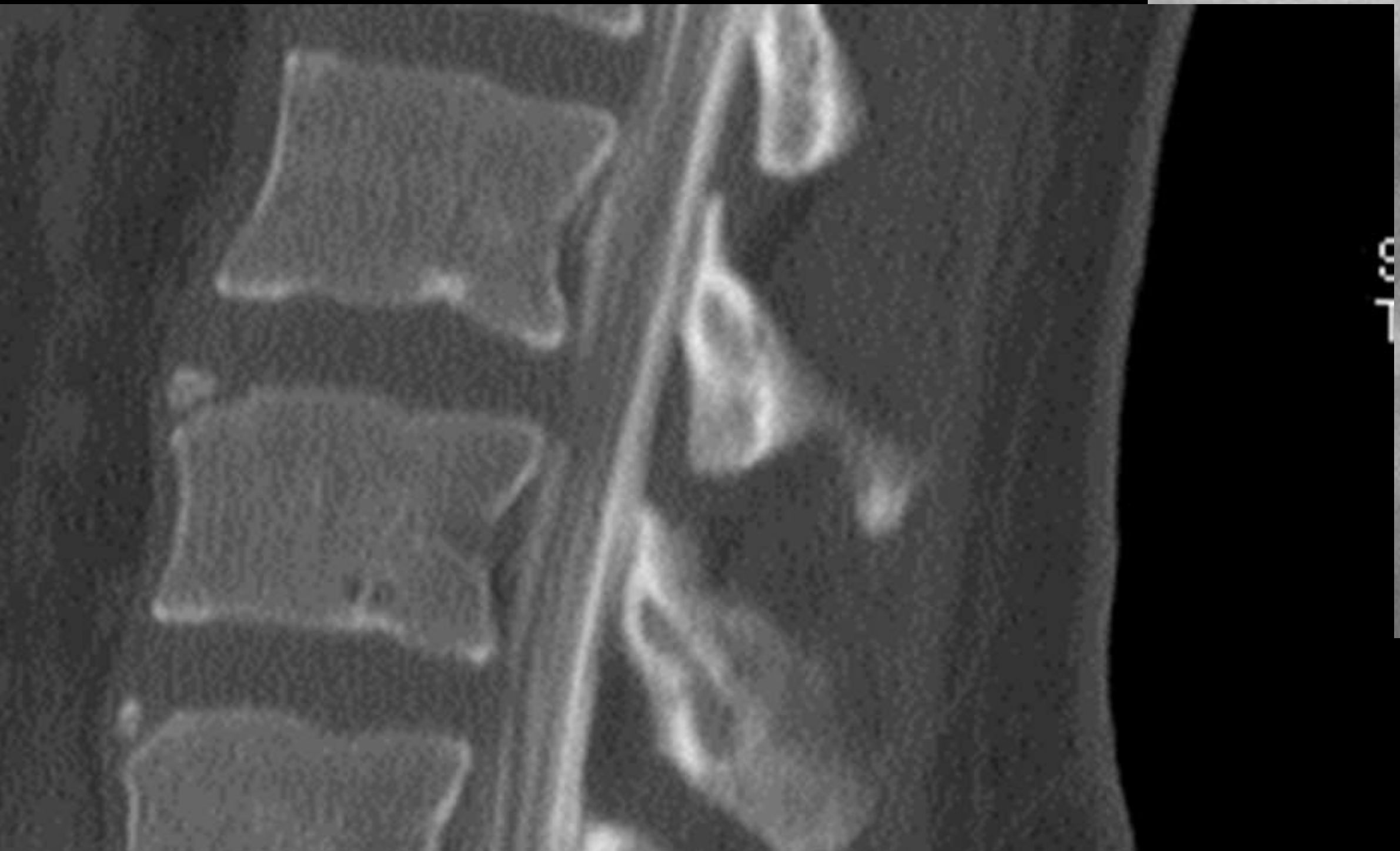

Limbus Vertebra

Limbus vertebrae

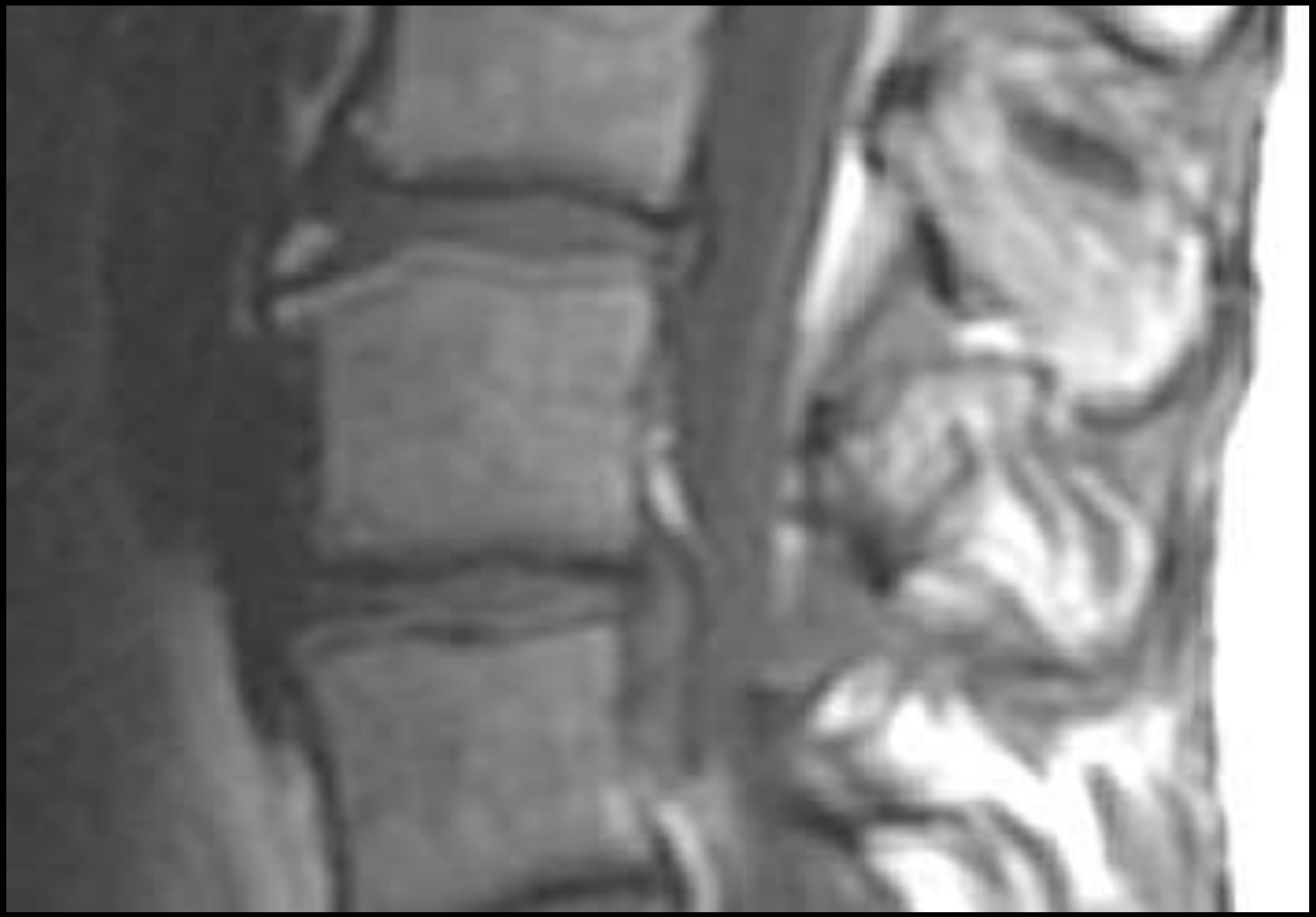

MARROW:
Normal MR Imaging

- Red (Hematopoietic)
  - T1 = muscle (except in neonates)
  - T2 > muscle & <fat
- Yellow (Fatty)
  - short T1 & long T2
  - isointense to sub-Q fat (< T2)
- **SI reflects composition**

	FAT	H2O	PROTEIN
Red(Hematopoietic)	40%	40%	20%
Yellow(Fatty)	80%	15%	5%

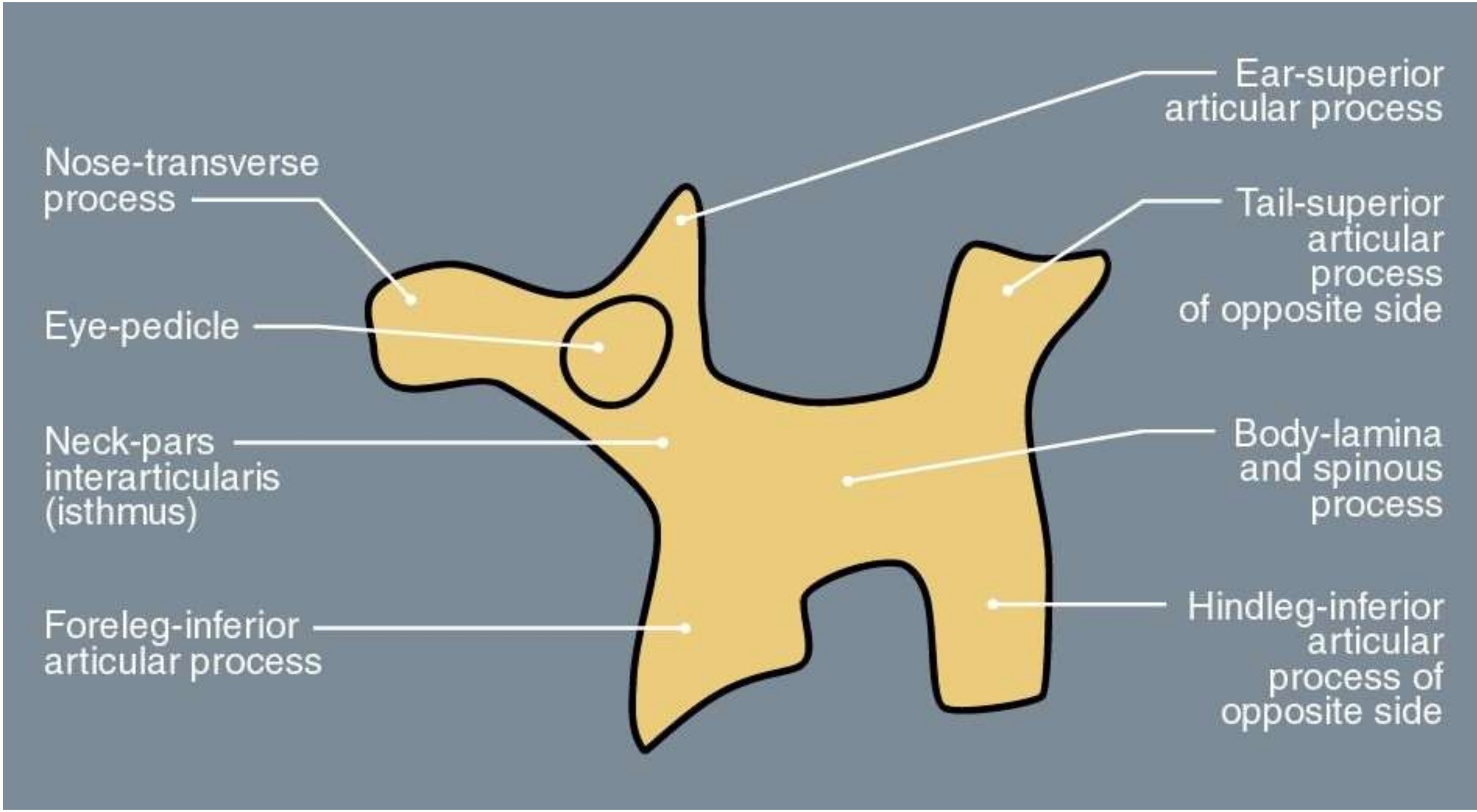

Ear-superior articular process
Nose-transverse process
Tail-superior articular process of opposite side
Eye-pedicle
Neck-pars interarticularis (isthmus)
Body-lamina and spinous process
Foreleg-inferior articular process
Hindleg-inferior articular process of opposite side

Lumbar Spi
“Scotty Dog

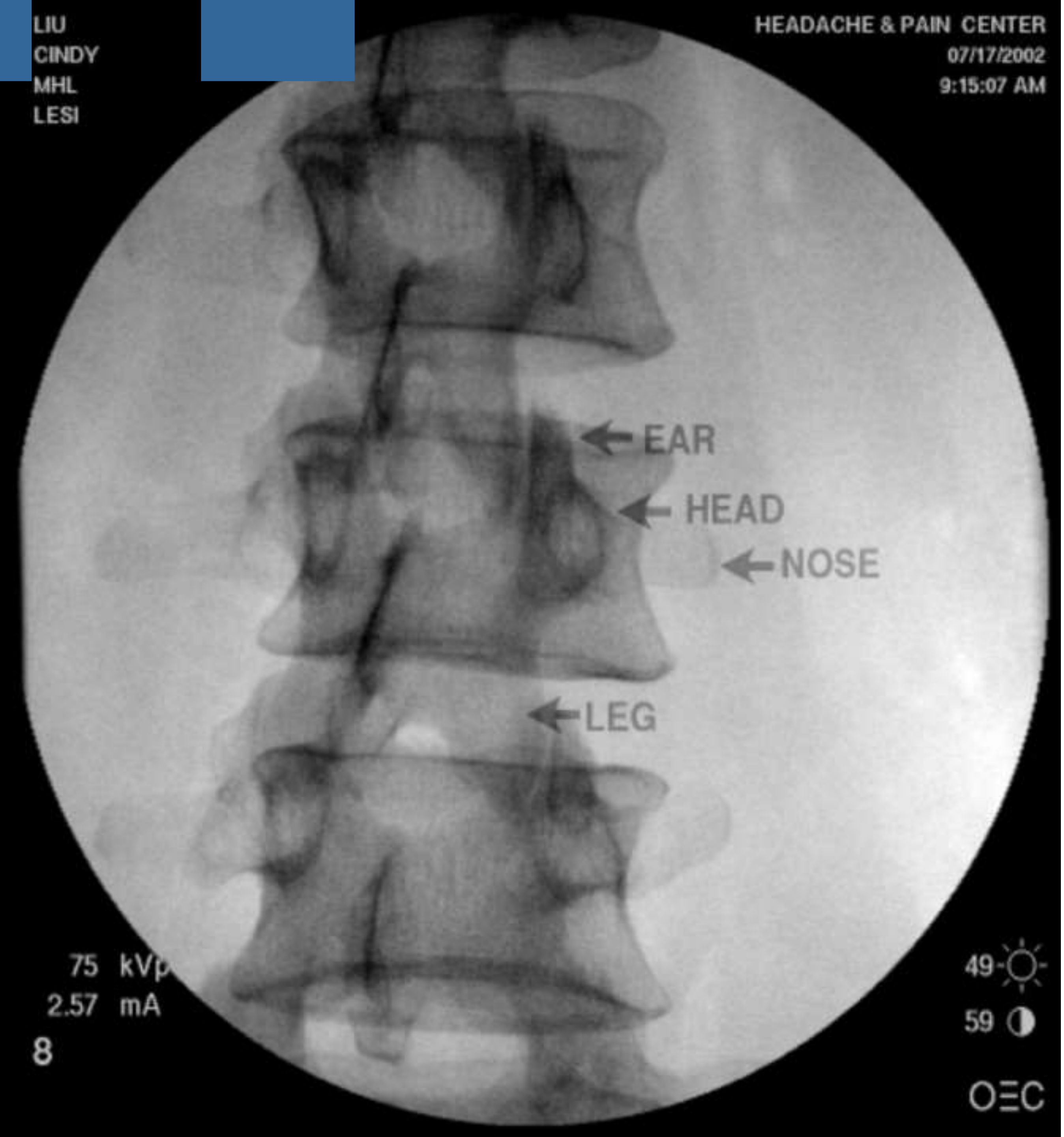

Lumbar Spi
Anatomy

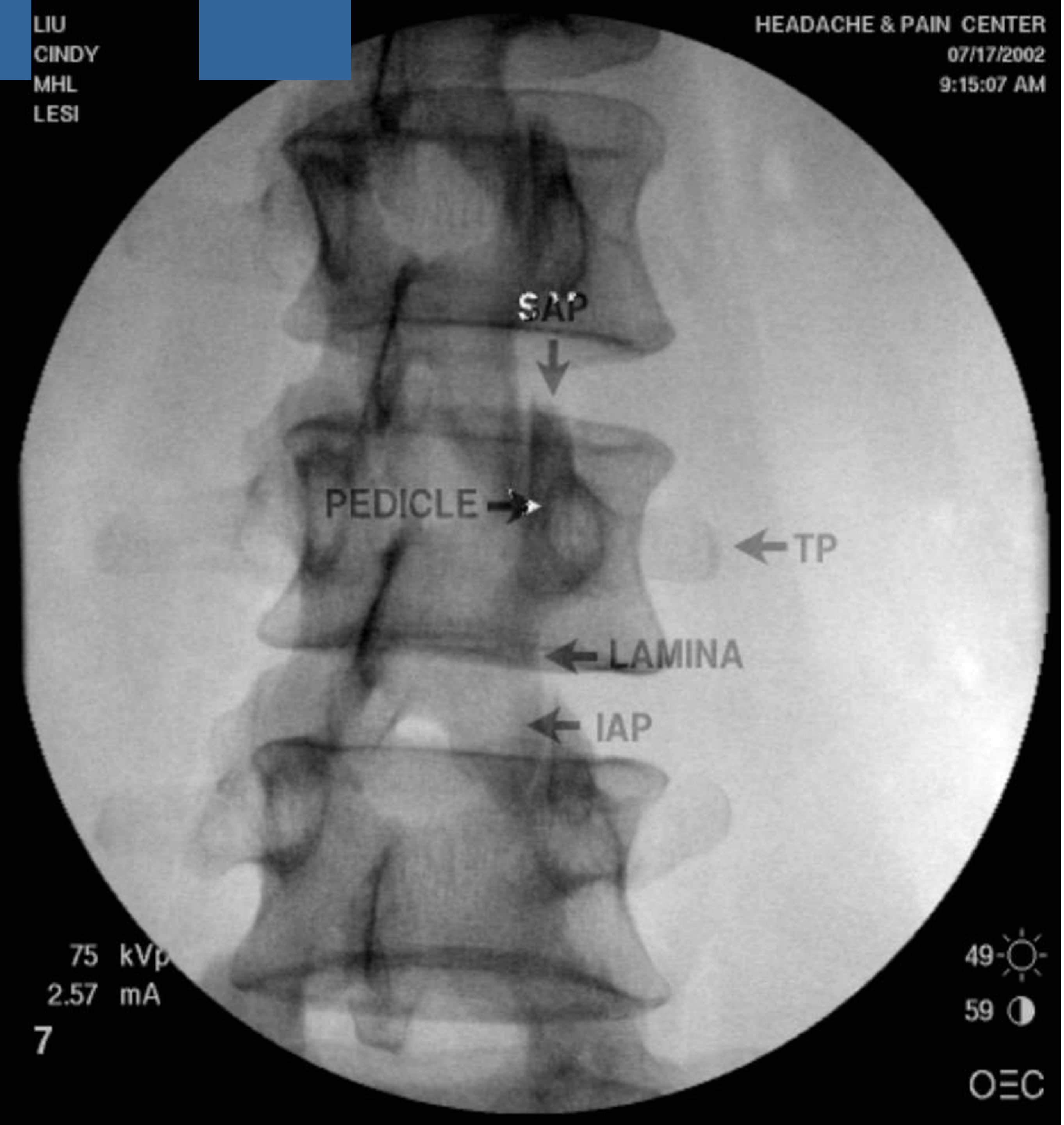

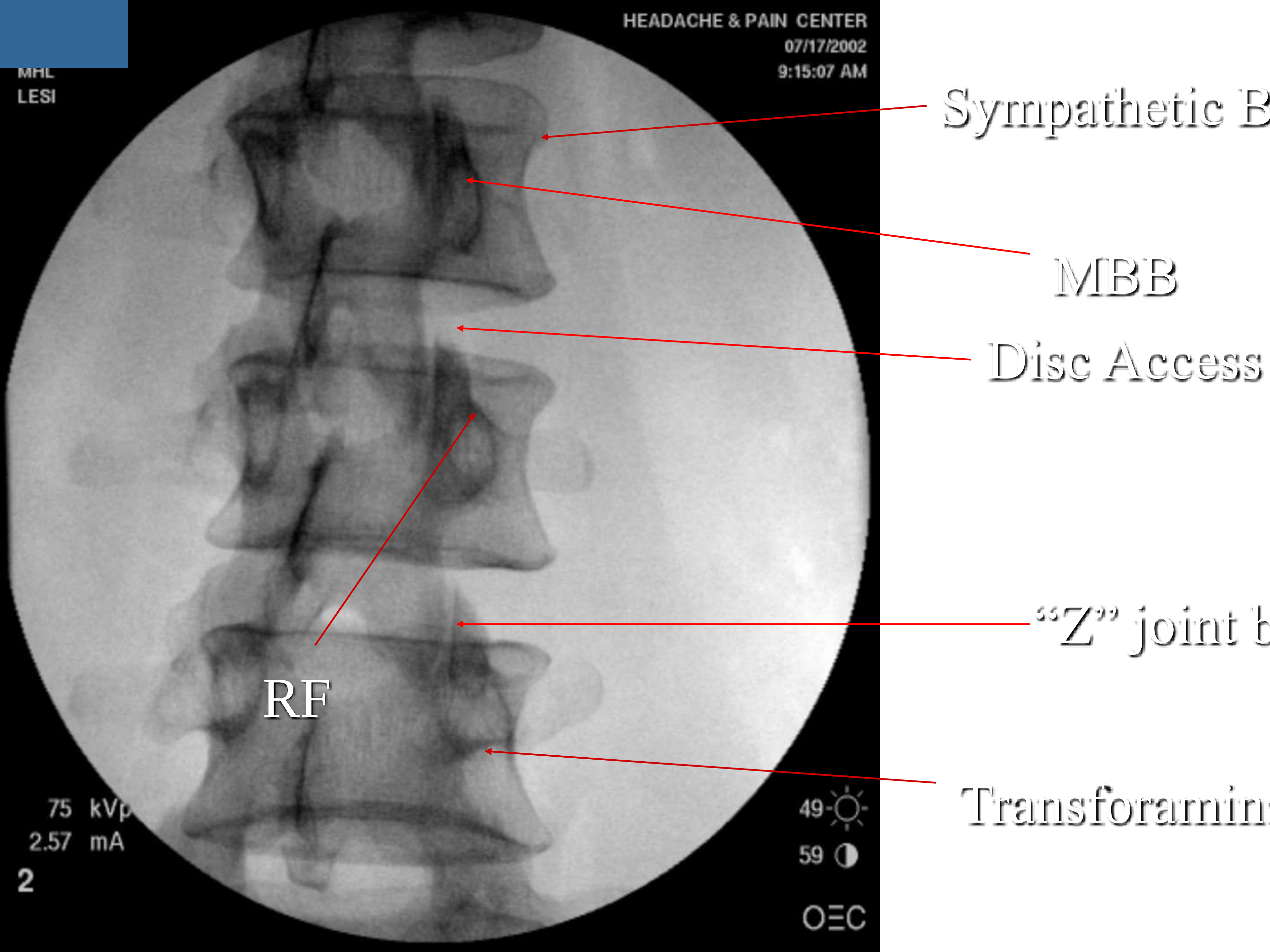
HEADACHE & PAIN CENTER
07/17/2002
9:15:07 AM
MHL
LESI
Sympathetic B
MBB
Disc Access
"Z" joint b
RF
Transforamin
75 kVp
2.57 mA
2
49
59
OEC

Sacrum

- block of bone at base of vertebral column
- Support spine → transmit load
- Triangular shape (broad cephalad → tapers)
- Foramina (anterior and posterior)

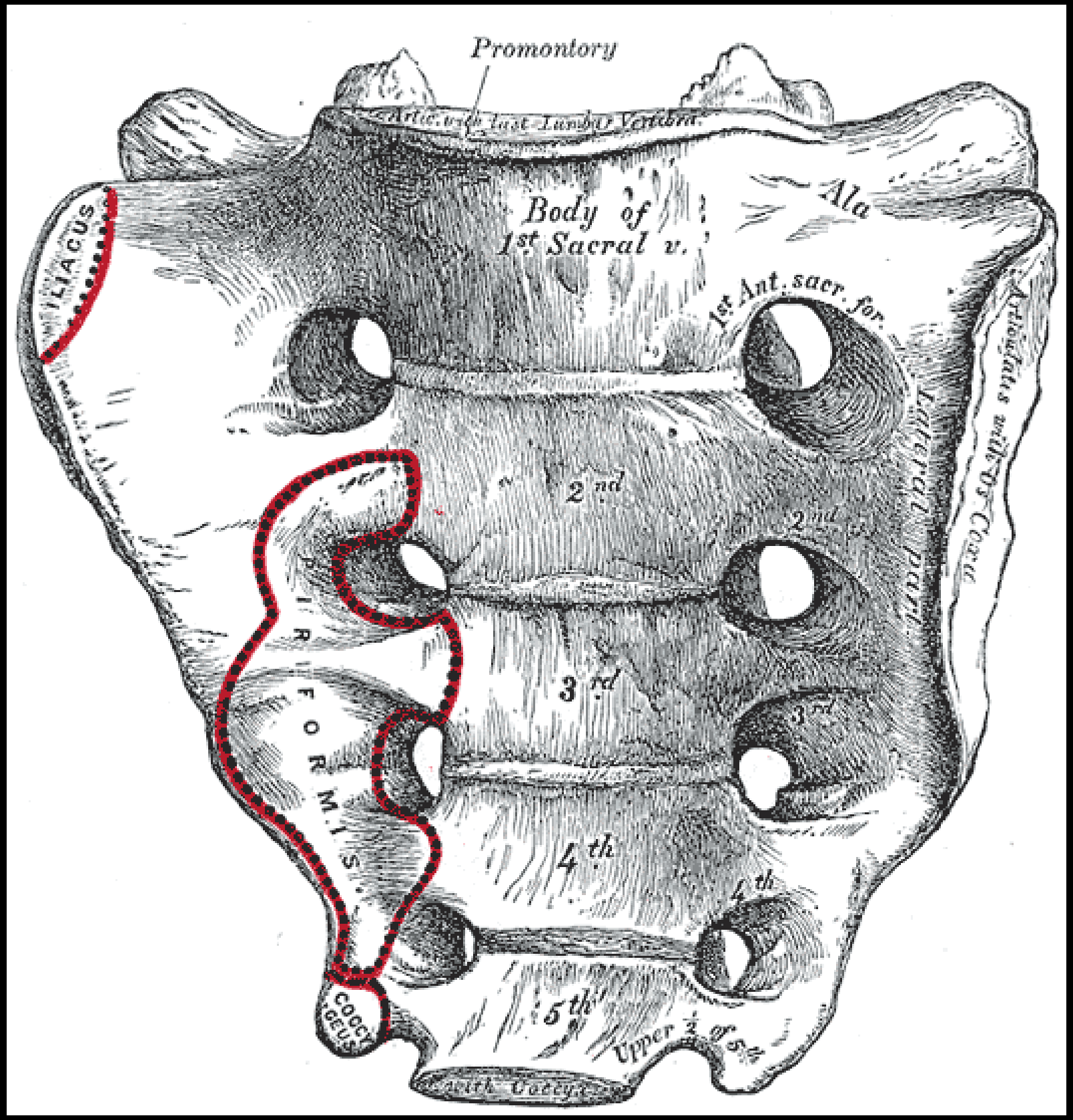

Sacrum

– Fusion of S1-5, the largest vertebral element

Coccyx

– Fusion of four rudimentary vertebrae

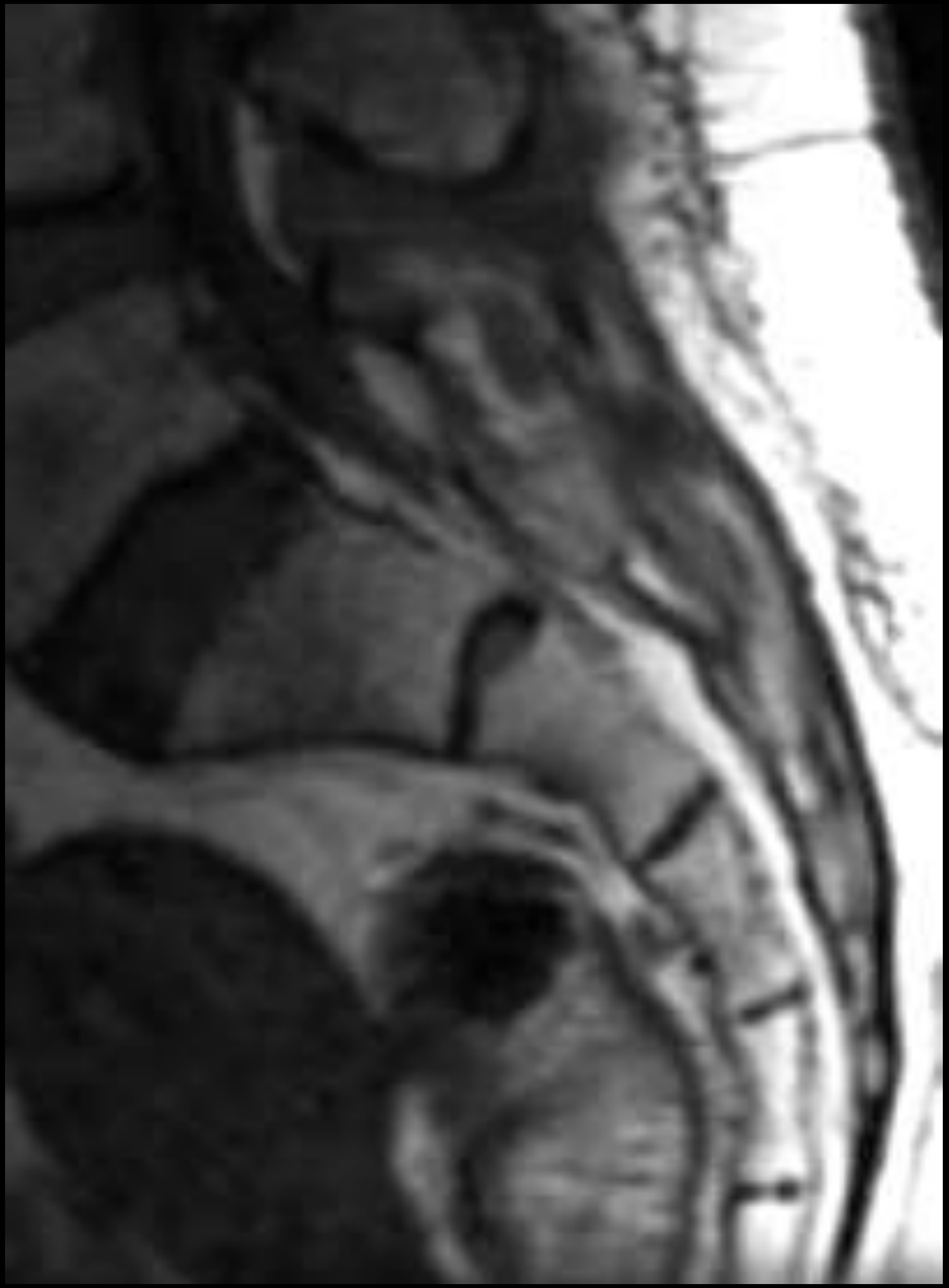

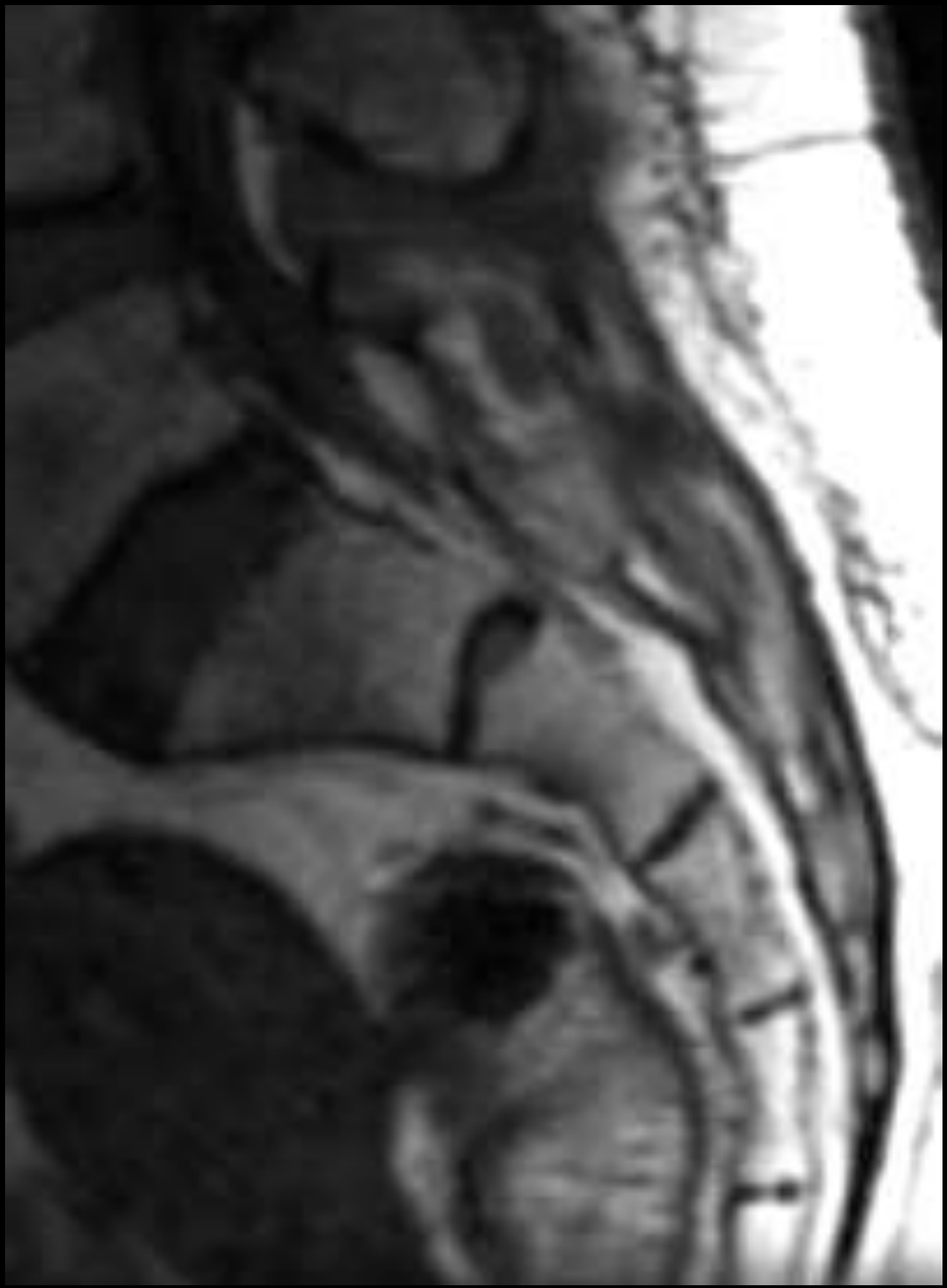
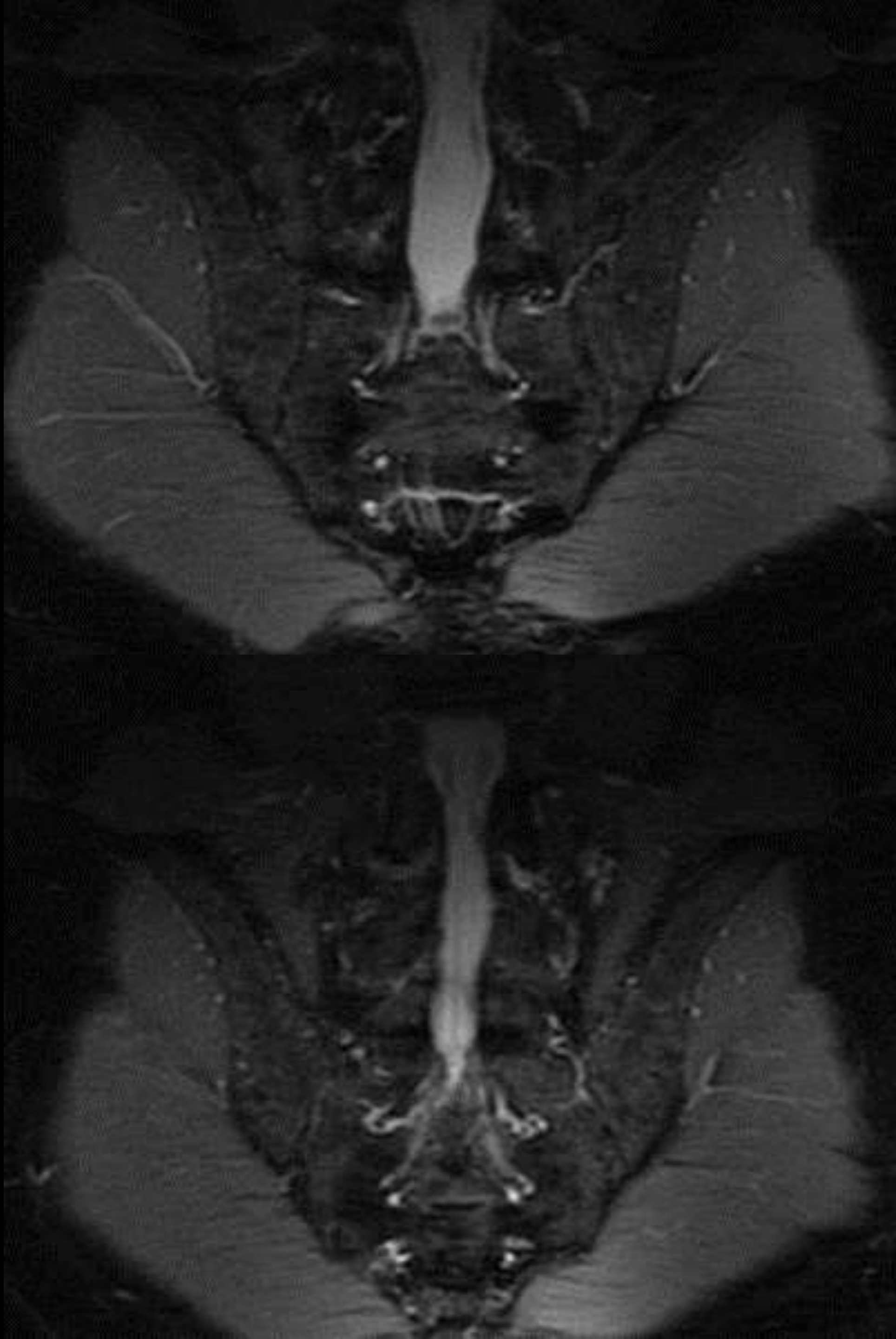

Sacrum

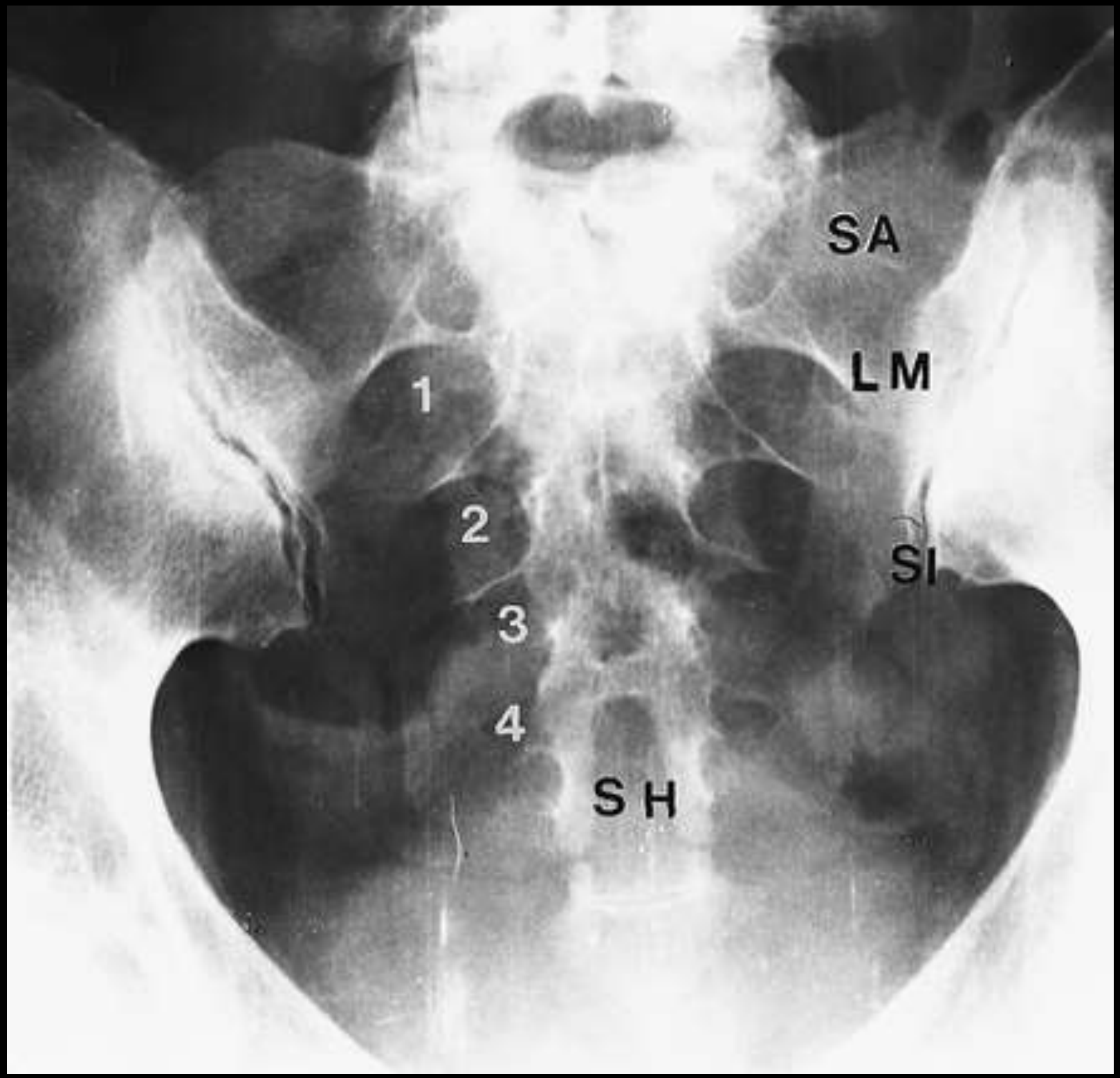

- Largest vertebral element (5 fused vertebrae)
- Sacral Alae (SA)
- Lateral Mass (LM)
- Sacral Hiatus (SH)
- Where spine meets the pelvis (SI Joint)

"Holy bone" (hieron osteon)

Sacrum

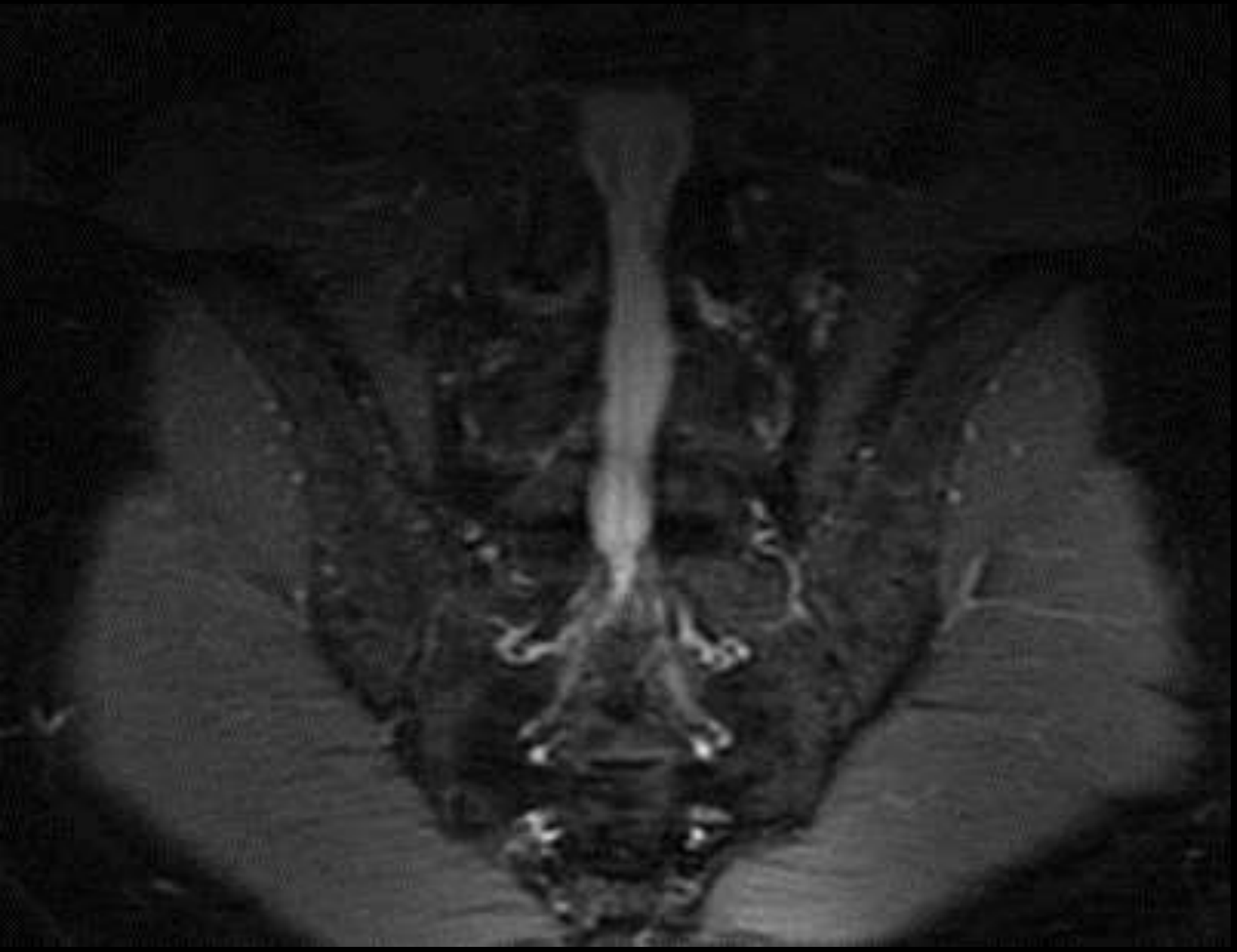

- “Holy bone”
  - hieron osteon
- Largest vertebral element (5 fused vertebrae)
- Sacral Alae (SA)
- Lateral Mass (LM)
- Sacral Hiatus (SH)
- Where spine meets the pelvis (SI Joint)

Vertebral Enumeration

Background

- There is relative paucity of information about the frequency and spectrum of vertebral level variants in the current published literature

- Variant spinal segment anatomy has several important clinical implications
  - Accurate localization of vertebral segments is essential prior to surgery or intervention
  - Important for communication between health providers
  - Variant anatomy may explain clinical symptoms

Thoracolumbar Spine Variability

1. Non-typical distribution of segments (homeotic variations)

2. Anomalous total number of vertebrae (meristic variations)

3. Transitional Situation
   - ThoracoLumbar Transitional Vertebrae (TLTV)
   - LumboSacral transitional vertebrae (LSTV)

Transitional Situations

A transitional vertebra retains partial features of the segment above and the segment below

Wigh RE. The thoracolumbar and lumbosacral transitional junctions. Spine (Phila Pa 1976). 1980 May-Jun;5(3):215-222.

Spinal Column

C-spine shows morphological stasis (n=7)

T and L spine are variable

Total number of vertebrae above the sacrum (presacral)

- 23
- 24
- 25

Kier EL. Some Developmental and Evolutionary Aspects of the Lumbosacral Spine. In Brain Anatomy and Magnetic Resonance Imaging; Gouaze A, Salamon G, eds. Springer-Verlag: Berlin Heidelberg, 1988.

Narita, Y., and Kuratani, S. Evolution of the vertebral formulae in mammals: a perspective on developmental constraints. J. Exp. Zool. (Mol. Dev. Evol.) 2005; 304B: 91–106.

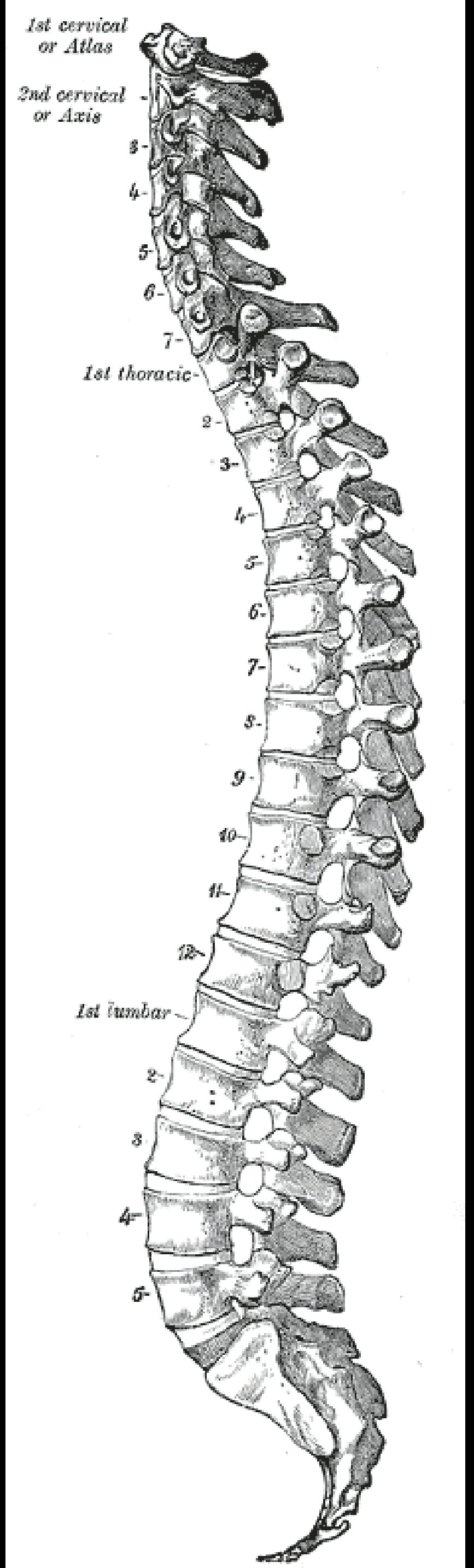

--Midline automated spine survey iterative scan technique (ASSIST) localizer images show variant vertebral anatomy

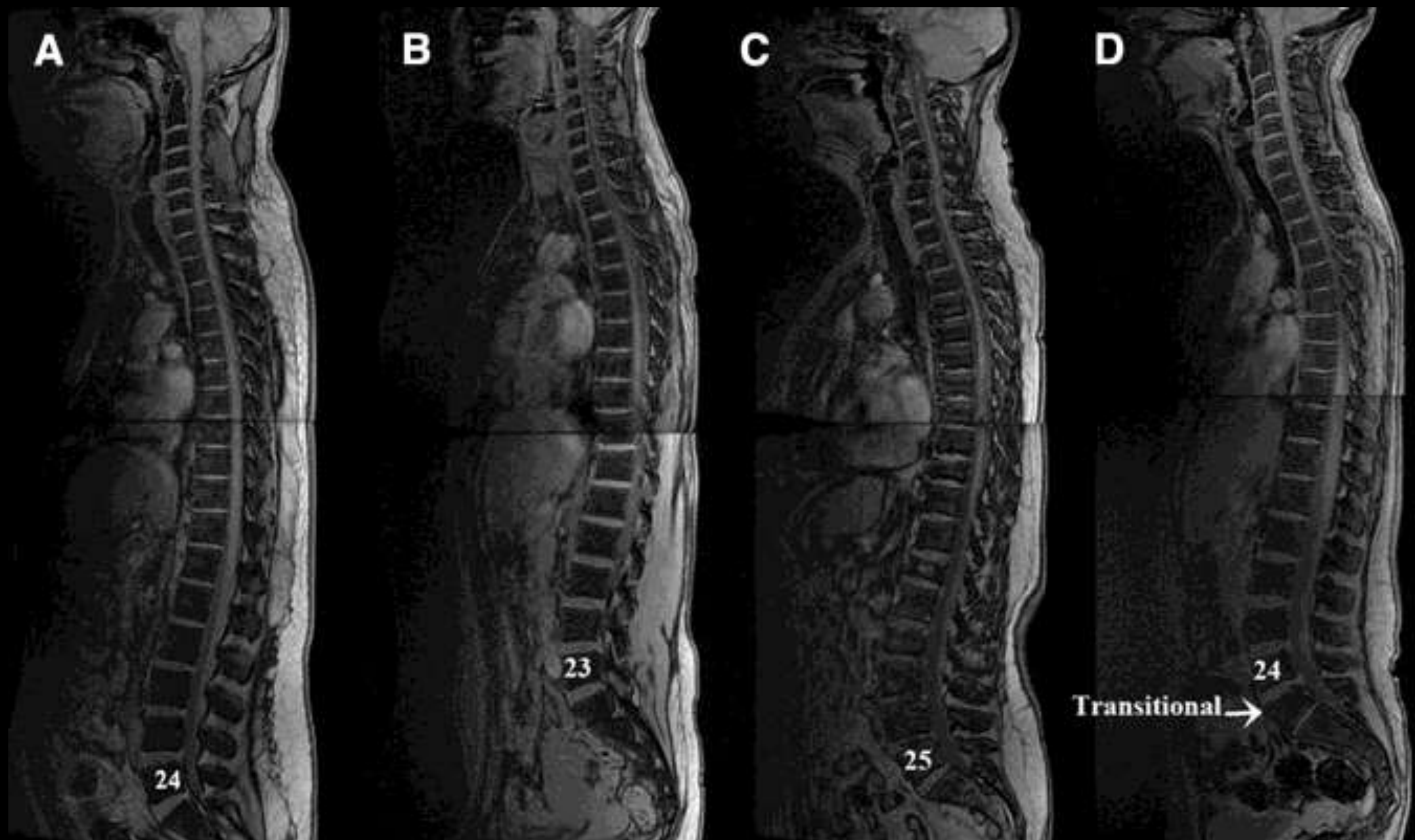

Results

Subjects- 300

- 171 males, 129 females
- Age mean - 30 years
- Age range – 18-45 years

Total presacral* segment distributions-

- 23 in 2.3% (7/300)
- 24 in 91.7% (275/300)
- 25 in 6% (18/300)

*Presacral = total number of vertebral segments above the sacrum

Results

Segmental vertebral distributions-

- C7/T12/L4 = 0.3% (1/300)
- C7/T12/L5 = 89.7% (269/300)
- C7/T12/L6 = 3.7% (11/300)
- C7/T13/L4 = 2.3% (7/300)
- C7/T11/L5 = 0.3% (1/300)
- C7/T11/L6 =0.7% (2/300)
- C7/T13/L5 = 2.7% (8/300)
- C7/T13/L6 = 0.3% (1/300)

Virgules (/, slashes) denote different segments

Cervical Rib

Criteria to identify the presence of a cervical rib:

- The rib must abut the 7th cervical vertebral transverse process
- The rib must have no connection with the manubrium sterni, although it may form a synostosis with the 1st rib
- The cervical rib must be separate from, but articulate with the transverse process of C7

Brewin J, Hill M, Ellis H. The prevalence of cervical ribs in a London population. Clin Anat. 2009 Apr;22(3):331-6.

A
1 2 3 4 5 6 7 8
B
1 2 3 4 5 6 7 8 9
C
1 2 3 4 5 6 7 8 9 10 11
D
7 8 9 10
E
9
F
G
24
H
22 23 24 25 26
I
24 25 26 27 28
J
25 26 27 28 29 30 31 32 33
K
26 27 28 29 30 31 32 33 34 35
L
29 30 31 32 33 34 35 36 37

Cervical Rib

Figure：Coronal CT image of cervical spine shows a cervical rib on the right side

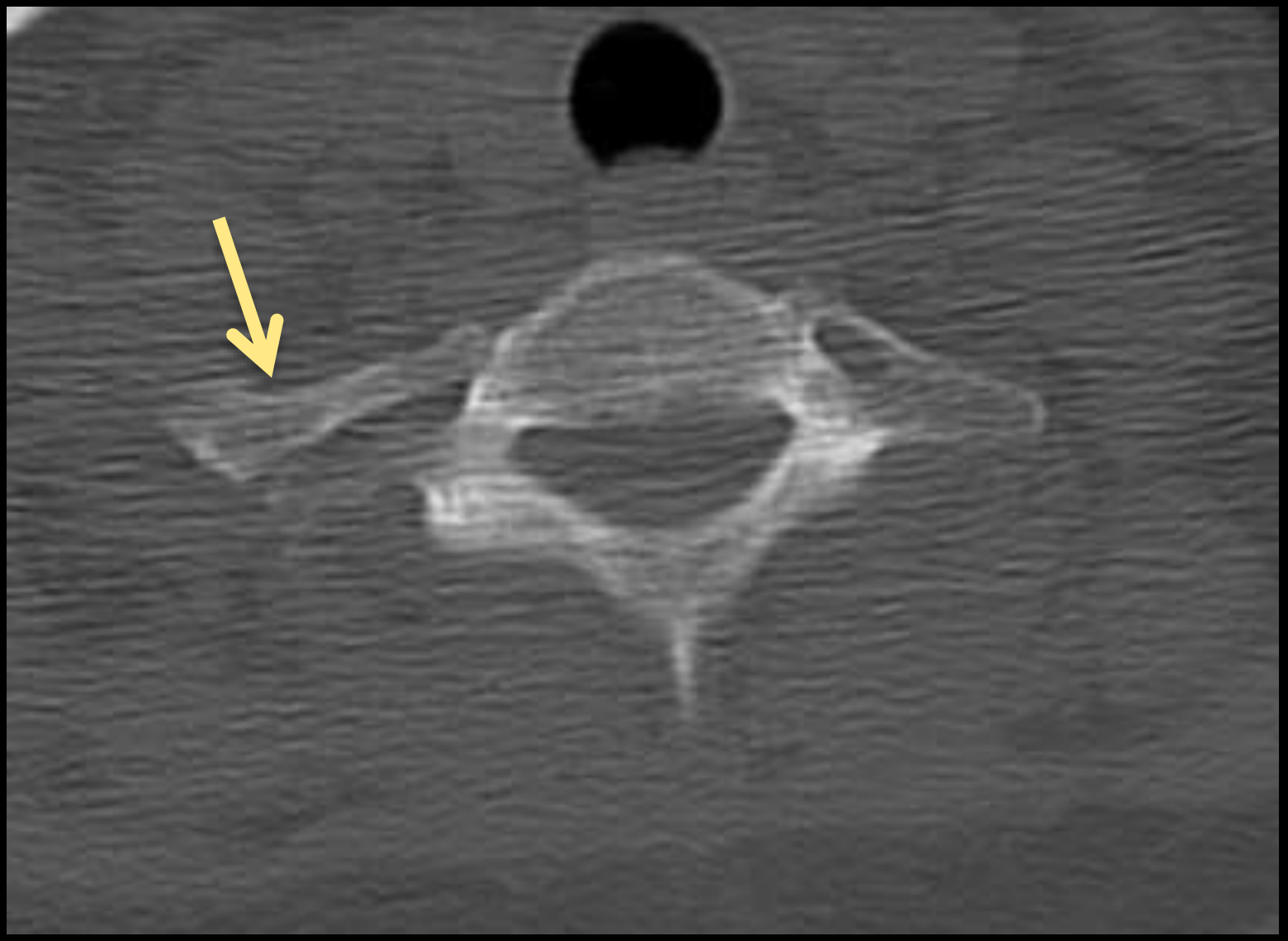

Figure： Axial CT image of cervical spine shows a cervical rib on the right, articulating with the transverse process of C7

Cervical Rib Variant

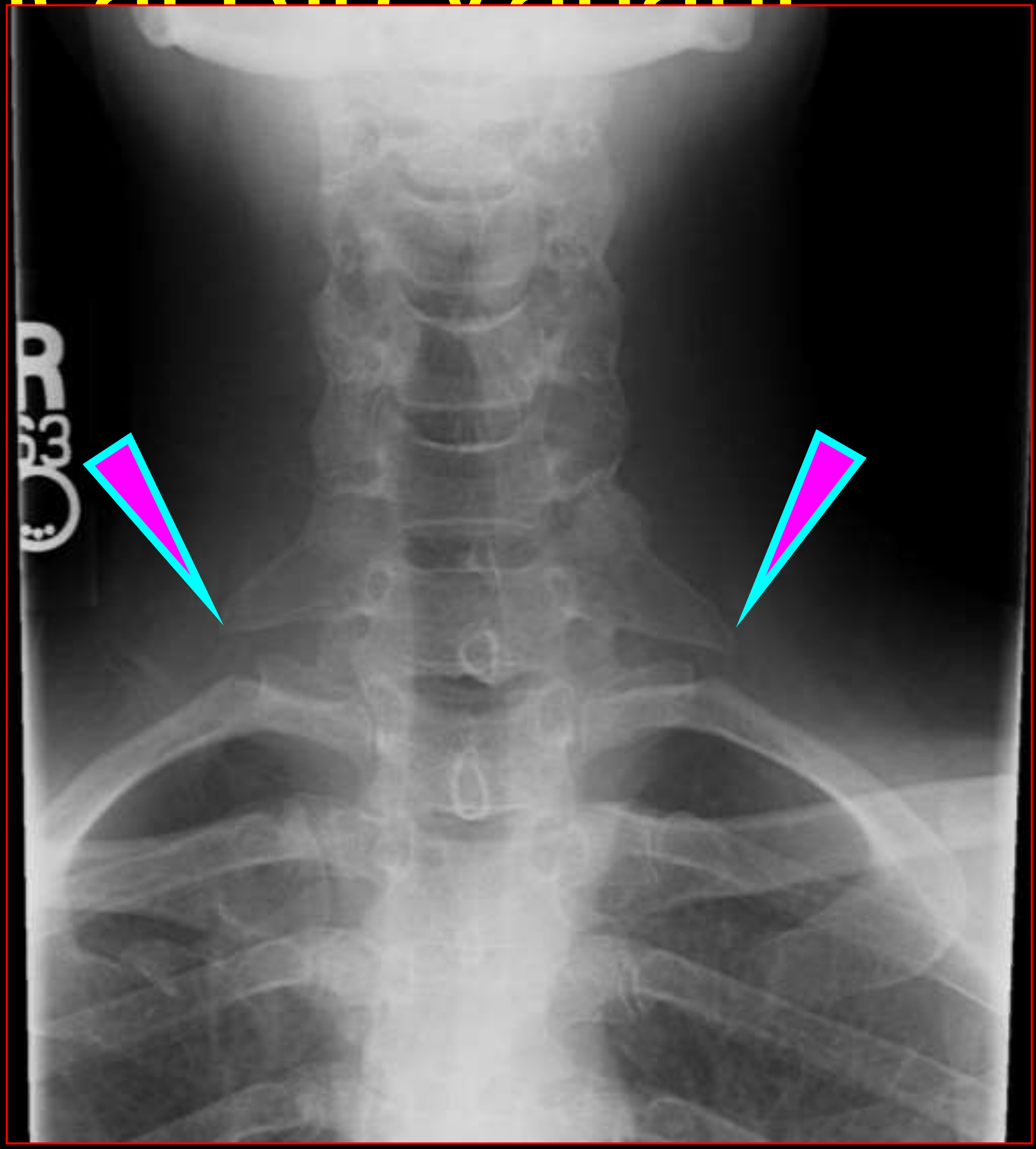

TOS: cervical rib fibrous band

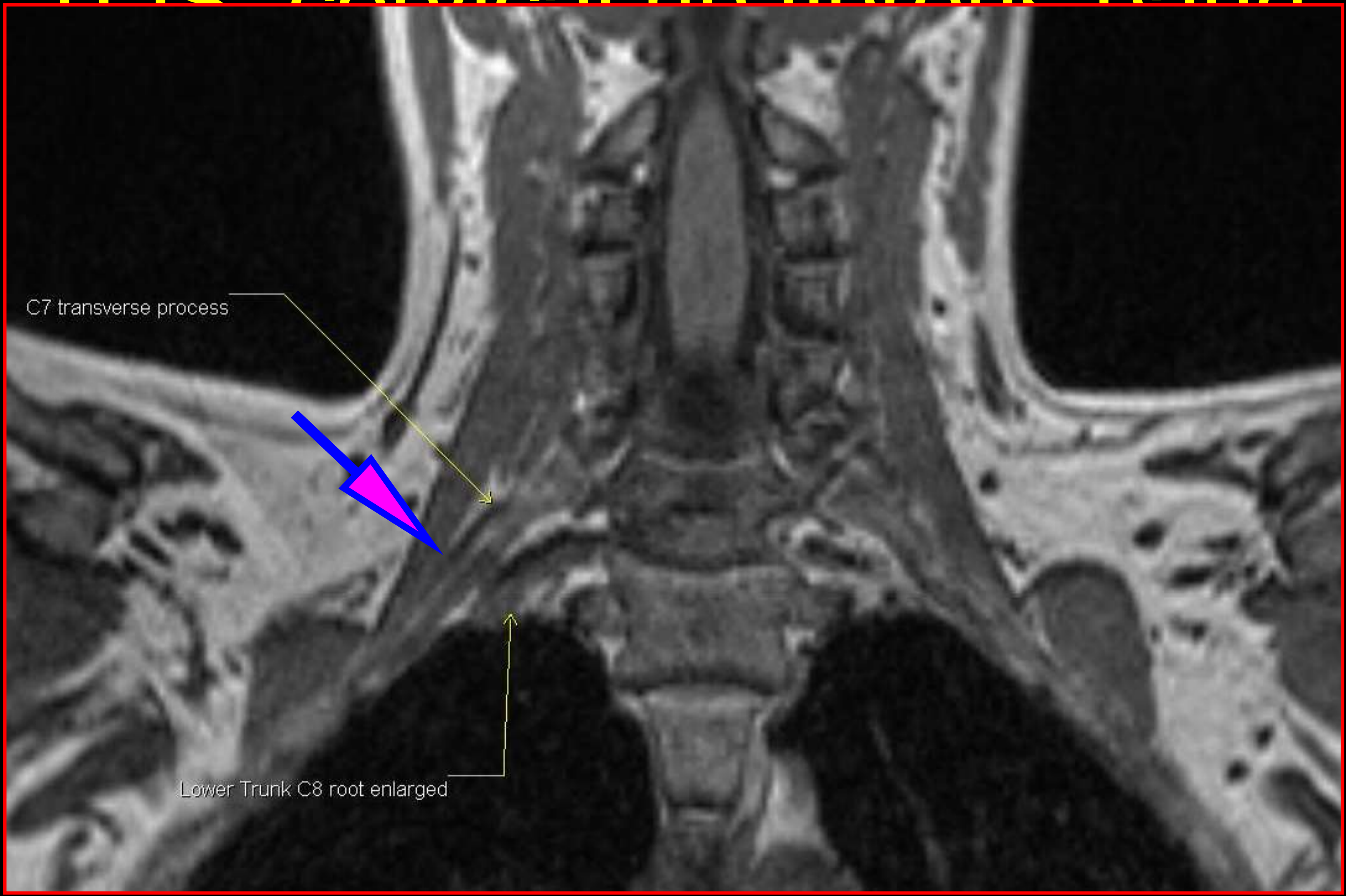

Thoracolumbar Transitional Vertebra

- Anomalous lowest rib bearing segment
- Consists of a diminutive or short rib on at least one or both side
- Short rib was defined as a rib with length of 38 mm or less

Wigh RE. The thoracolumbar and lumbosacral transitional junctions. Spine (Phila Pa 1976). 1980 May-Jun;5(3):215-222.

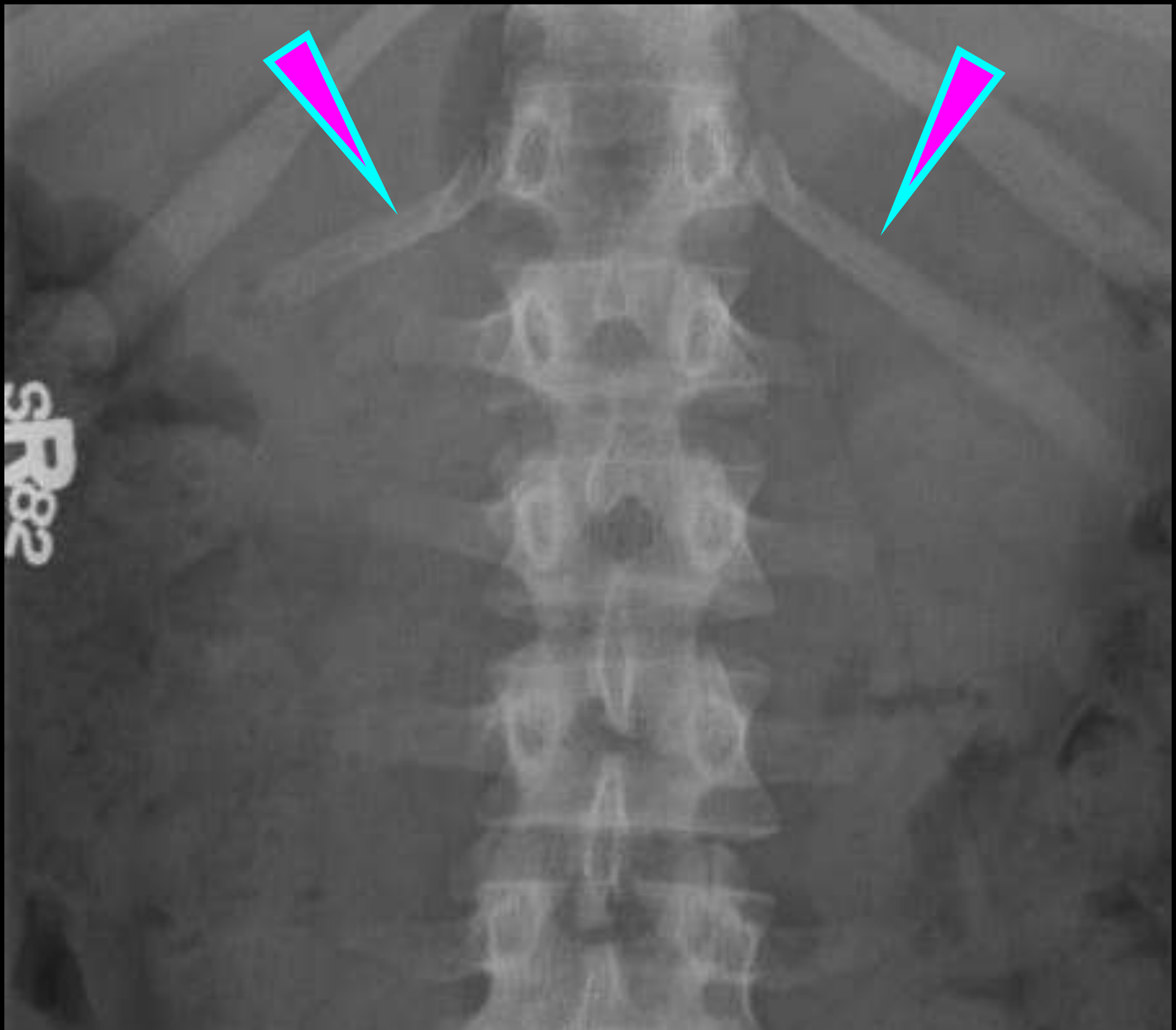

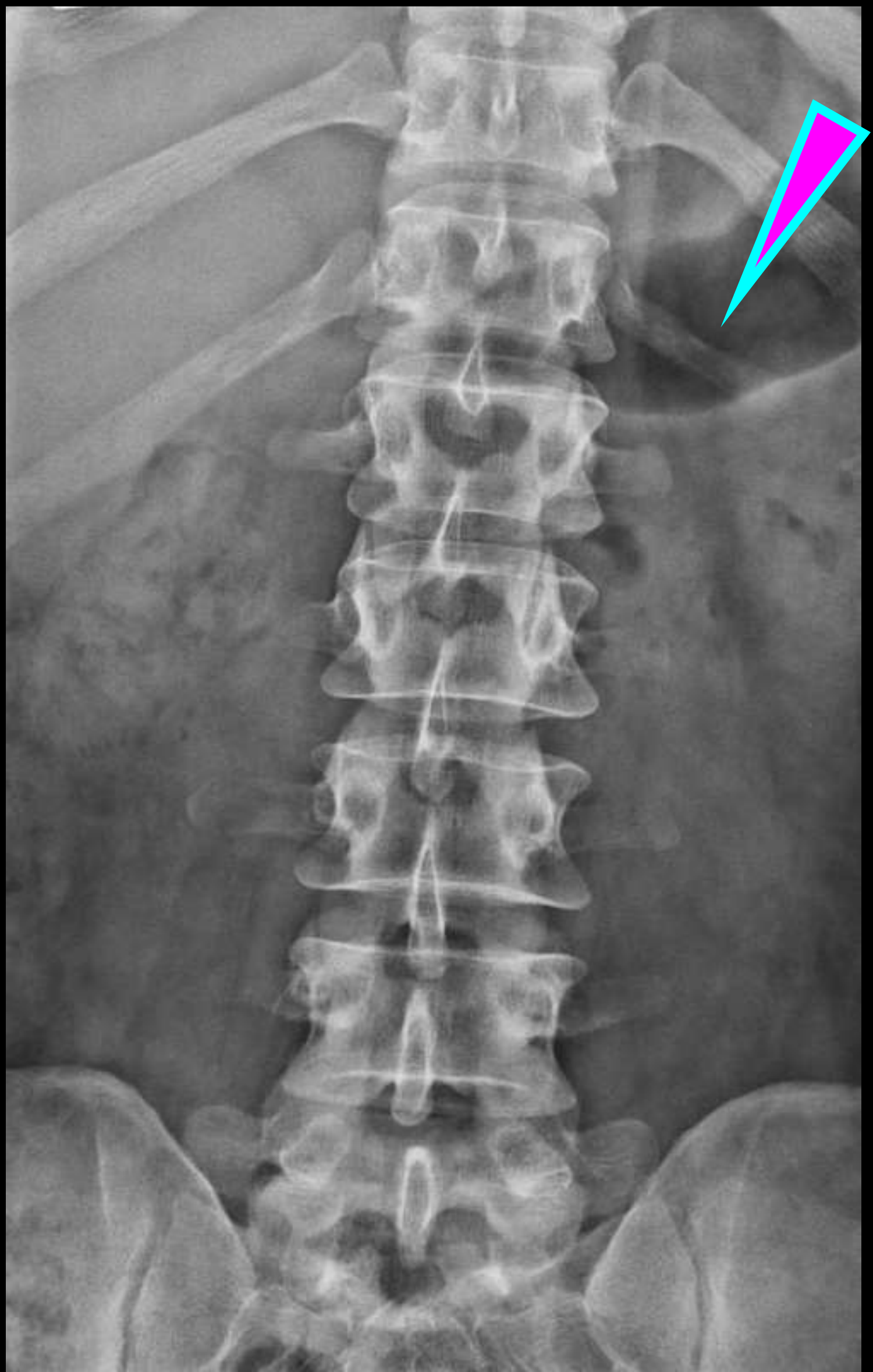

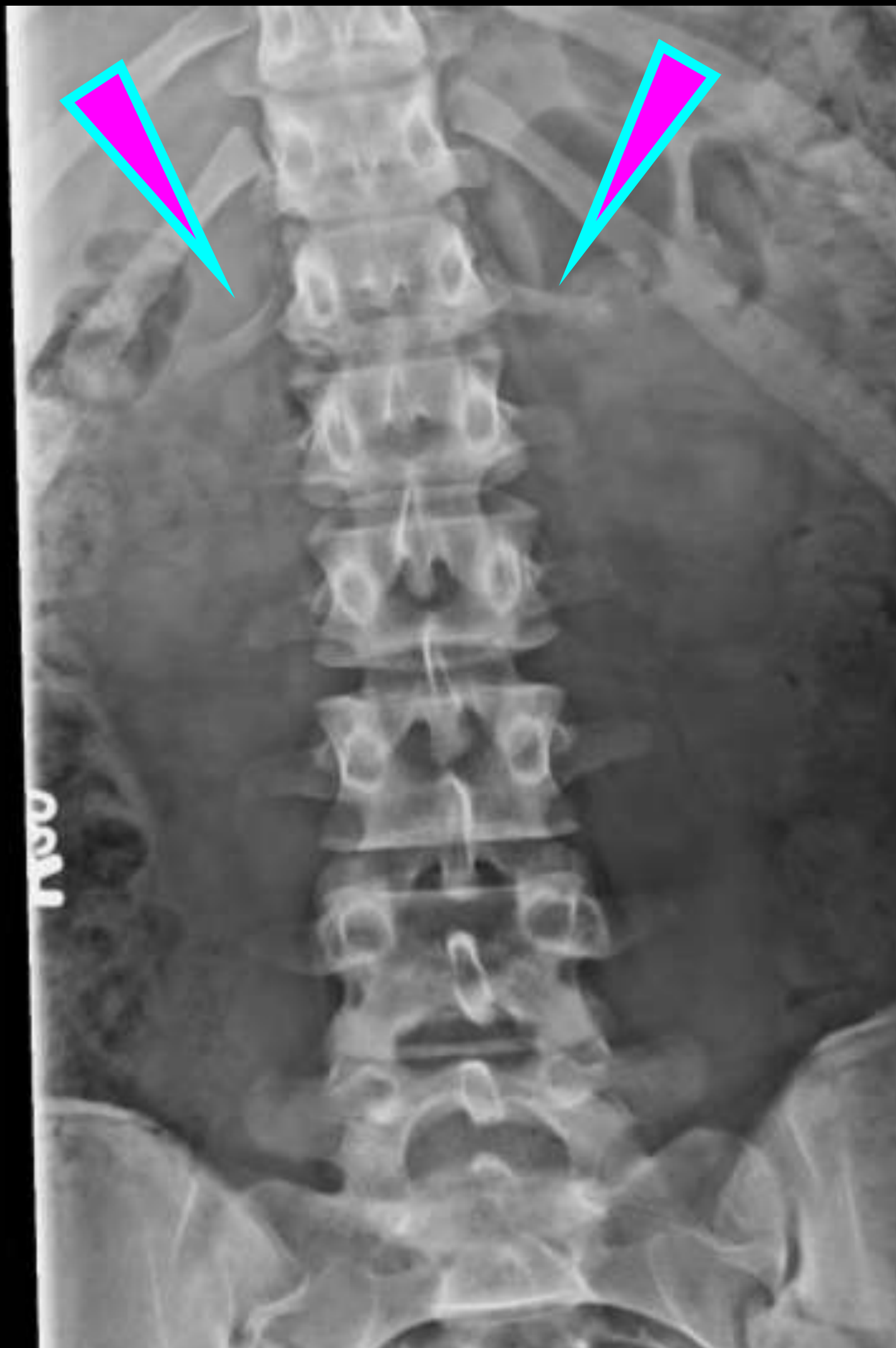

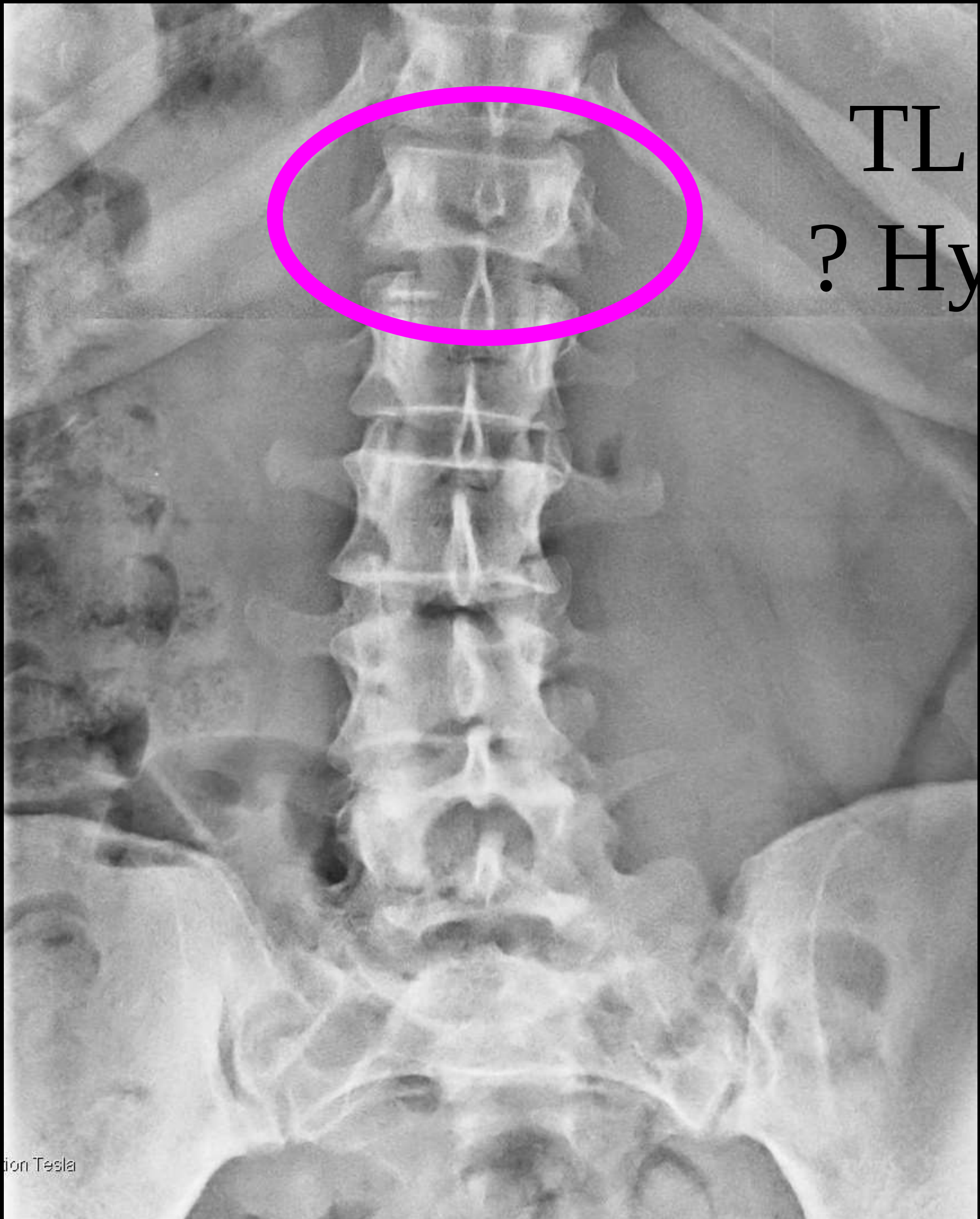

TL

? Hy

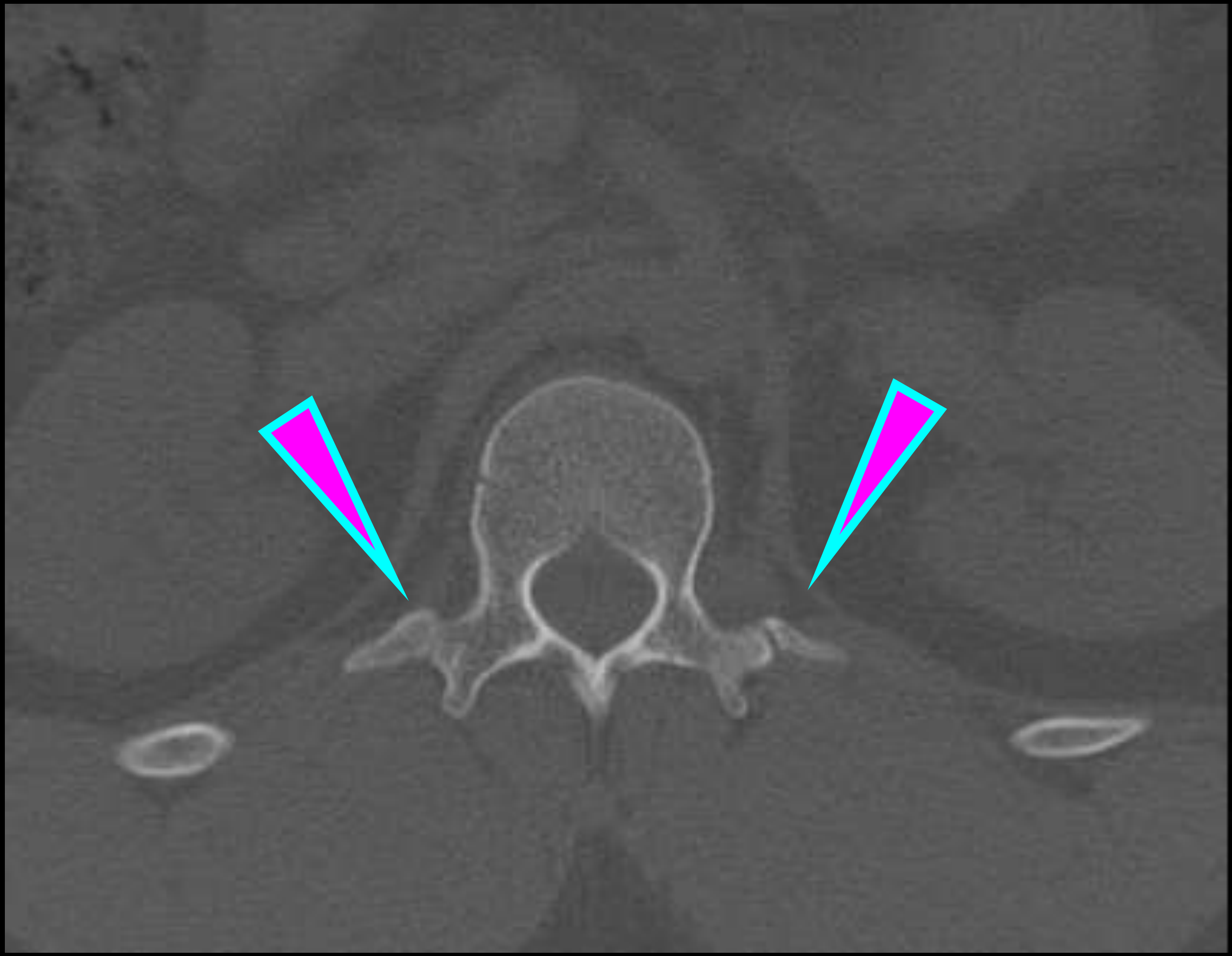

Thoraco-lumbar junction

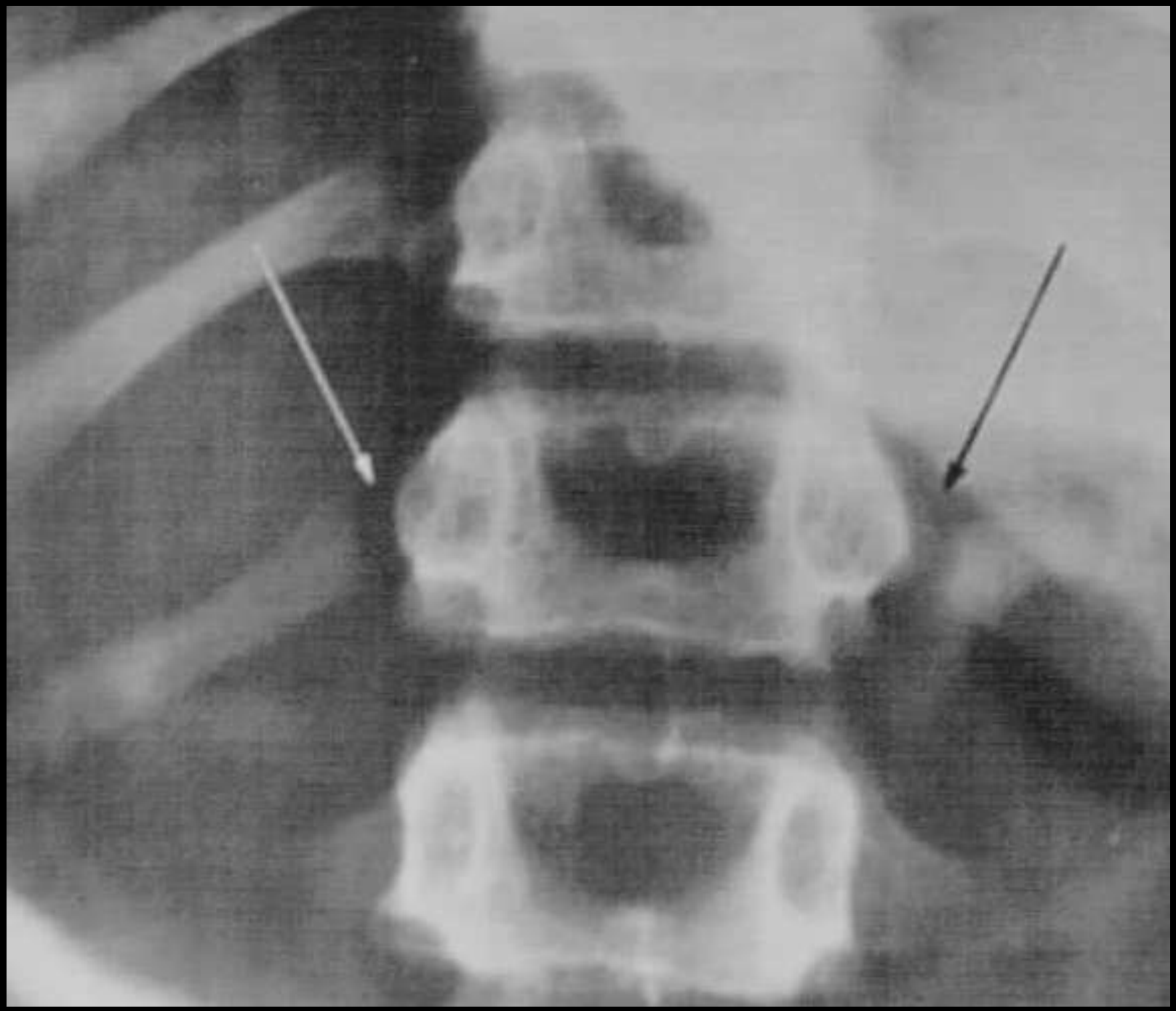

Thoracolumbar Transitional vertebra

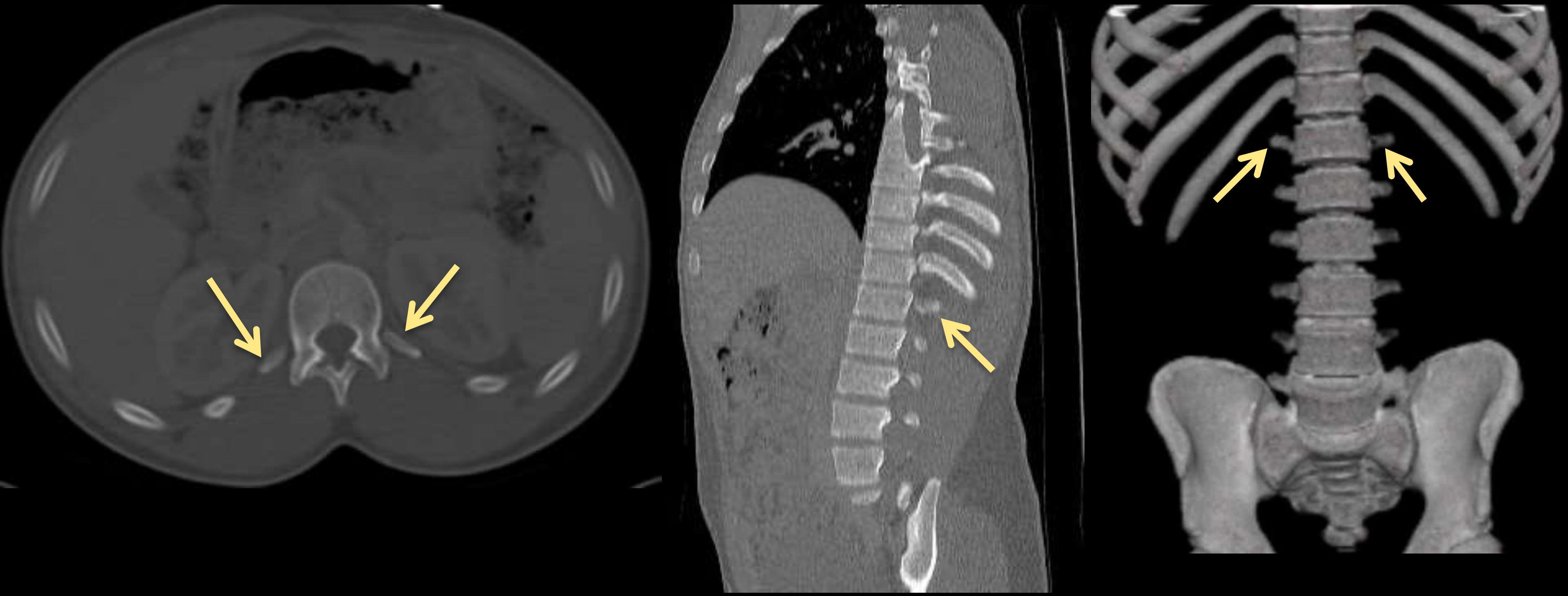

Axial (a), oblique sagittal (b), 3D (c) CT images of thoracolumbar junction shows a transitional verterbra with short ribs on both sides

TLTV

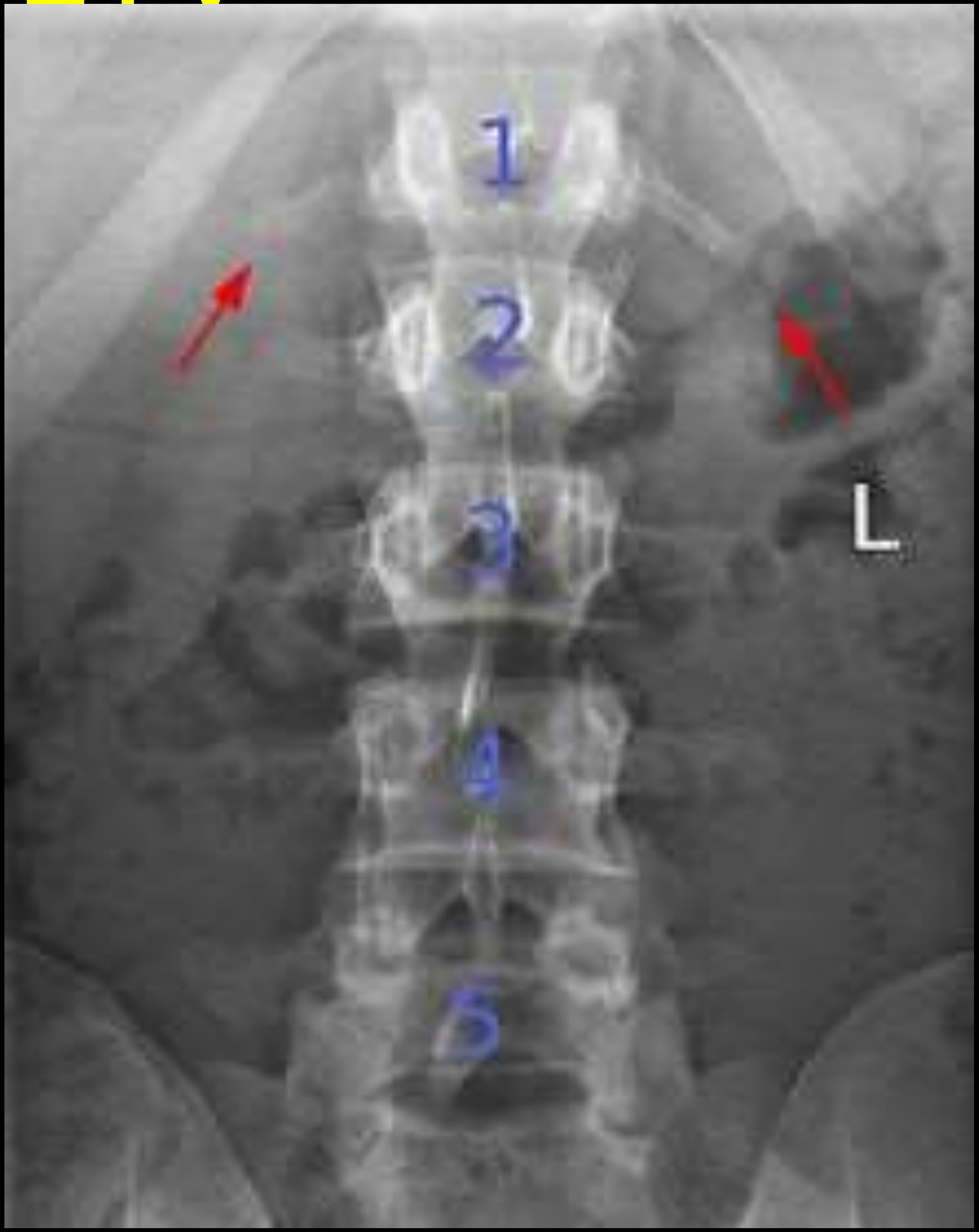

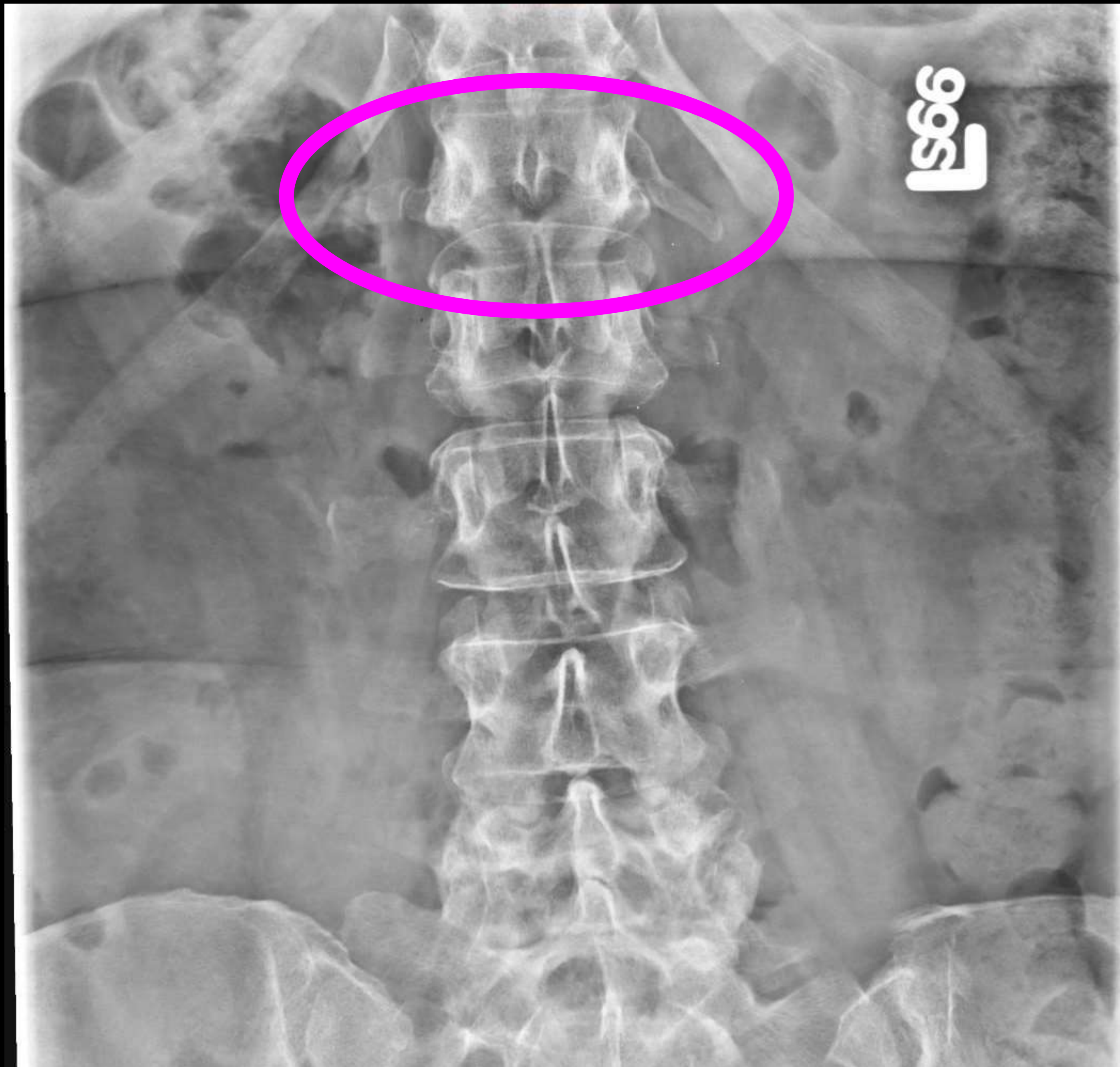

Thoraco-lumbar junction

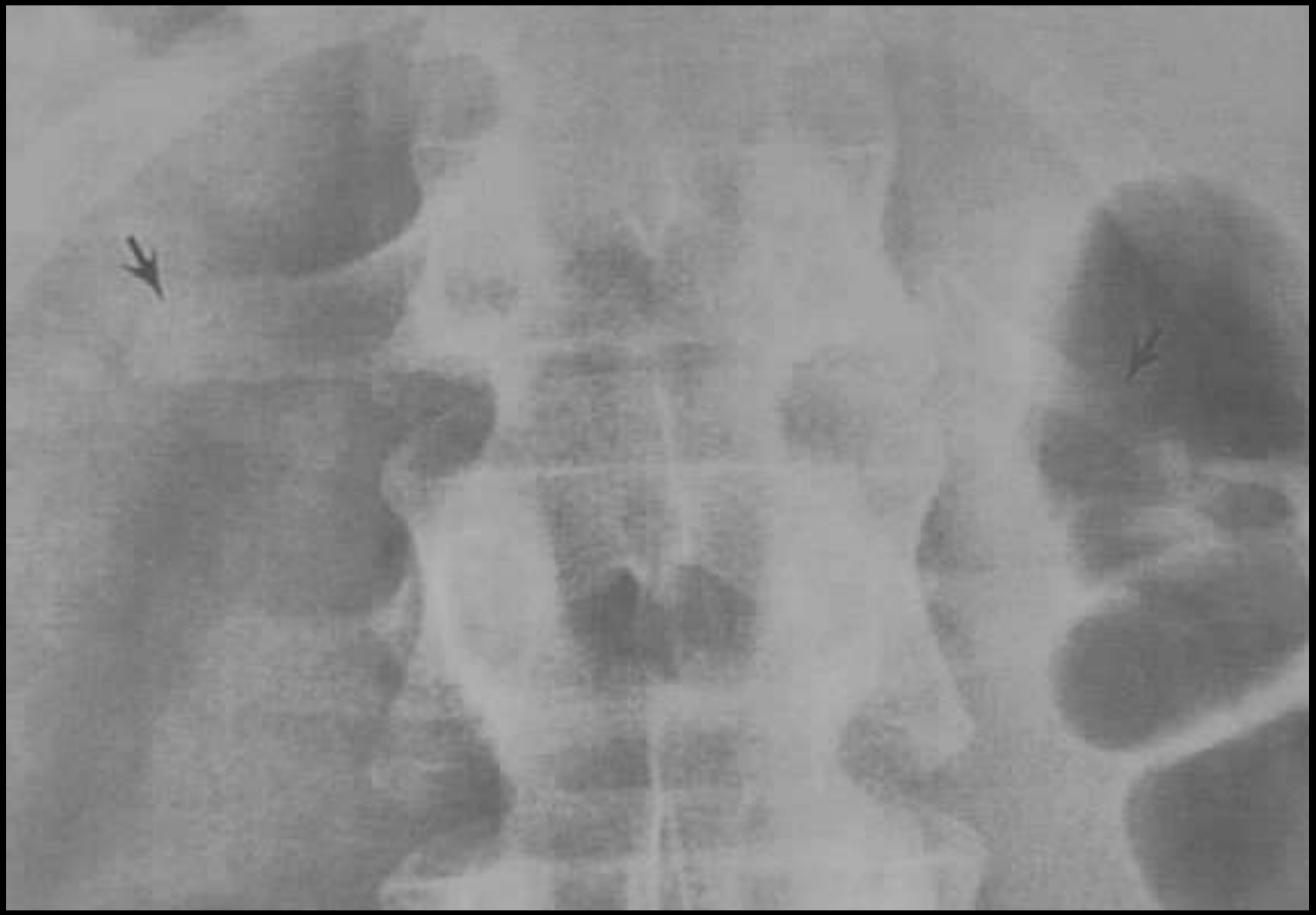

TLTV

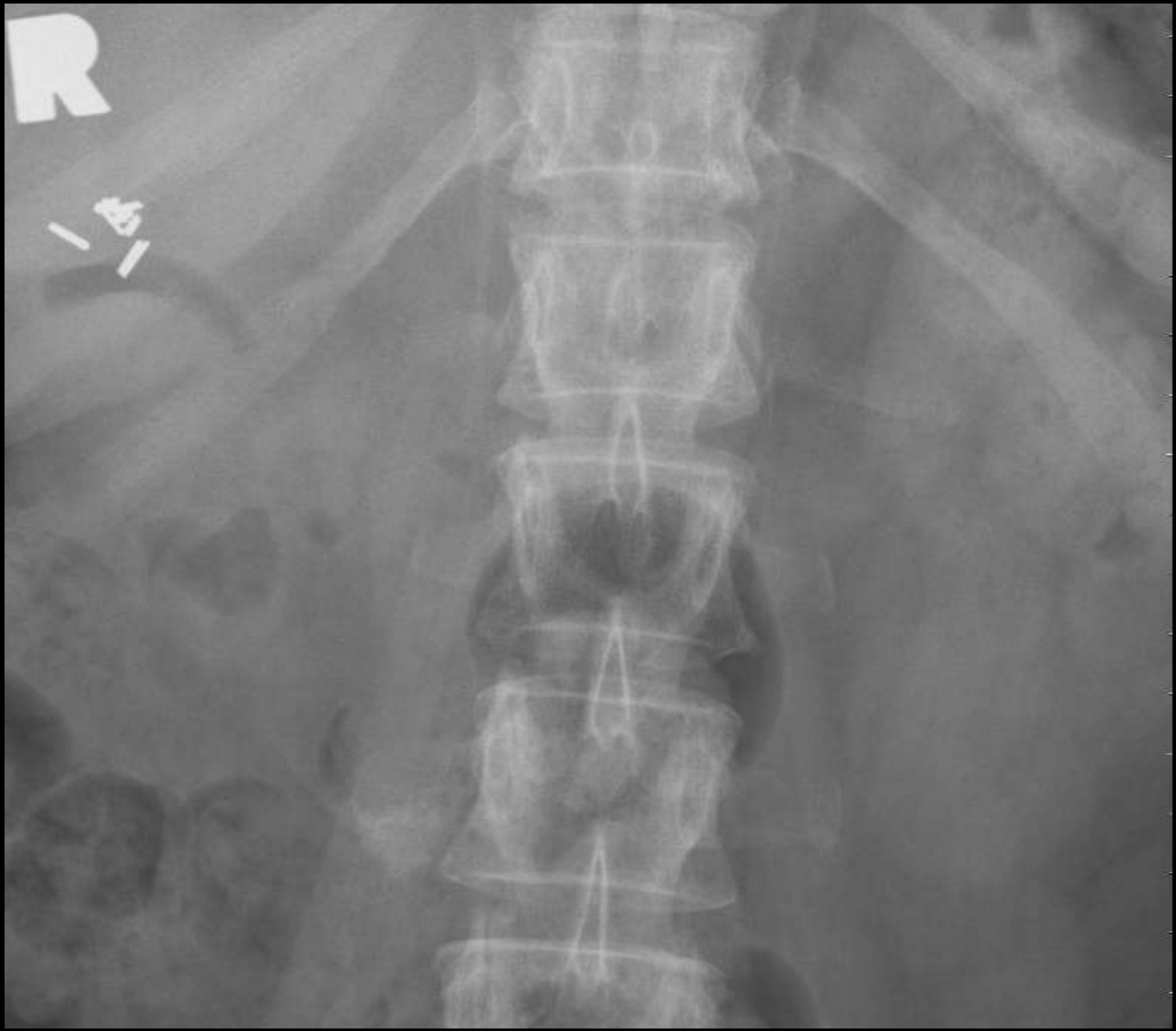

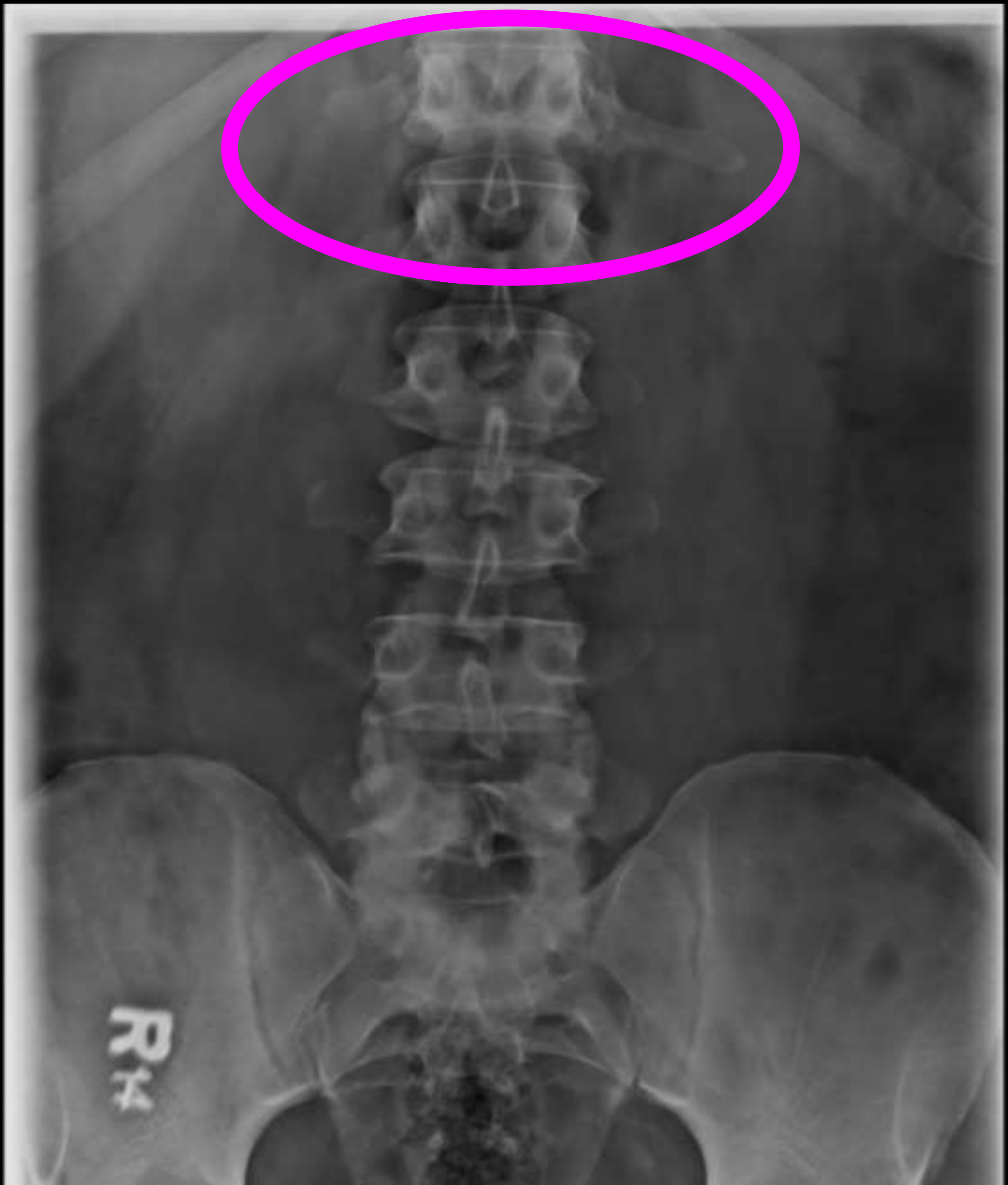
R


L14

TLTV

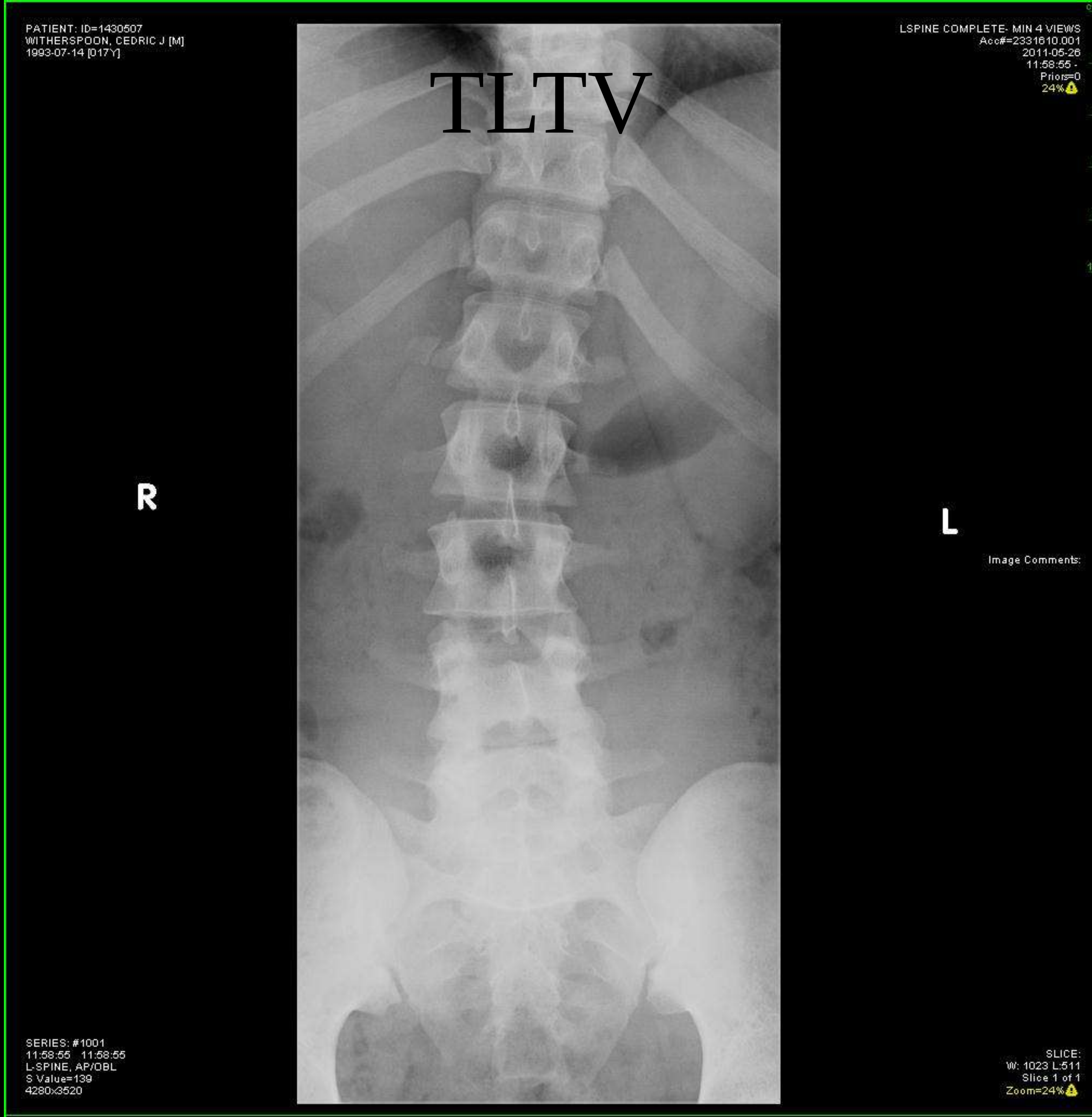
PATIENT: ID=1430507
WITHERSPOON, CEDRIC J [M]
1993-07-14 [017Y]
LSPINE COMPLETE- MIN 4 VIEWS
Acc#=2331610.001
2011-05-26
11:58:55 -
Priors=0
24%
R
L
Image Comments:
SERIES: #1001
11:58:55 11:58:55
L-SPINE, AP/OBL
S Value=139
4280x3520
SLICE:
W: 1023 L:511
Slice 1 of 1
Zoom=24%

TLTV


R

LumboSacral Transitional Vertebra (LSTV)

Presence of an enlarged transverse process on one or both sides of the last lumbar vertebra

Classified as per Castellvi's classification *(Castellvi et al, 1985)*

LSTV - Dermatomes

Patients with LSTV have dermatomal variation and alteration in function of the lumbosacral nerve roots, which manifests as poor correlation with clinical symptoms and may result in wrong level of percutaneous injection procedures

Seyfert S. Dermatome variations in patients with transitional vertebrae. J Neurol Neurosurg Psychiatry. 1997 Dec;63(6):801-803.
Kim YH, Lee PB, Lee CJ, Lee SC, Kim YC, Huh J. Dermatome variation of lumbosacral nerve roots in patients with transitional lumbosacral vertebrae. Anesth Analg. 2008 Apr;106(4):1279-1283.

Castellvi Classification of LSTV

Type I	Dysplastic transverse process	Unilateral (a) or bilateral (b) large triangular transverse process, at least 19 mm wide
Type II	Incomplete lumbarisation / sacralisation	Enlarged transverse process with unilateral (a) or bilateral (b) pseudarthrosis with the adjacent sacral ala
Type III	Complete lumbarisation / sacralisation	Enlarged transverse process, with unilateral (a) or bilateral (b) complete fusion with the adjacent sacral ala
Type IV	Mixed	Type IIa on one side and type IIIa on the other

Lumbosacral Transitional Vertebra- Classification

Type I- *Dysplatic transverse perocess:*

- Large transverse process triangular in shape measuring at least 19 mm in width
- Type Ia- Unilateral; Type Ib- Bilateral

Castellvi Classification of LSTV

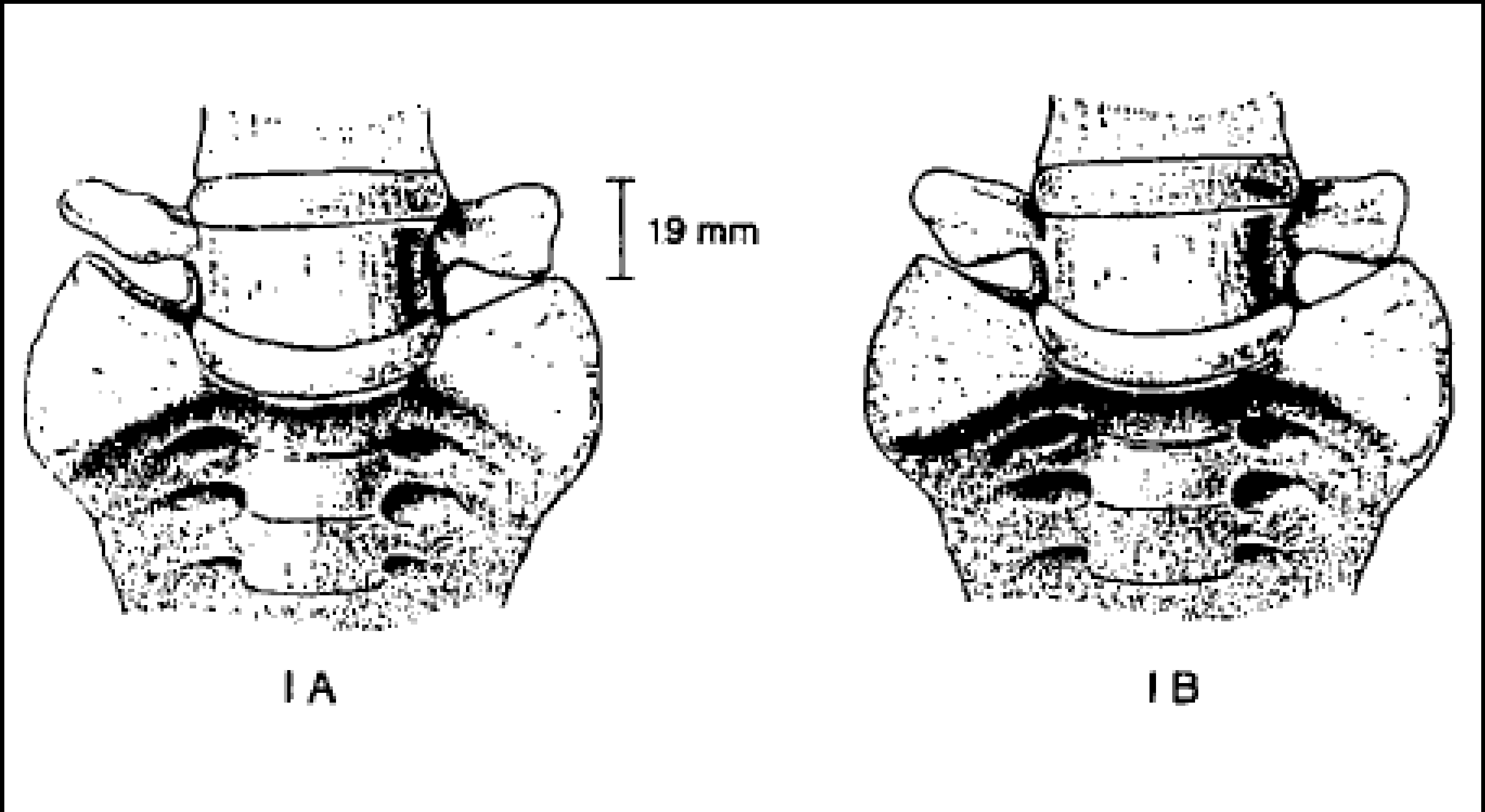

Lumbosacral Transitional Vertebra- Type Ia

Figure- Oblique coronal CT image of lumbosacral junction shows a transitional verterbra with enlarged tranverse process on the right side

Lumbosacral Transitional Vertebra- Type Ib

Figure – Coronal CT image of lumbosacral junction shows a transitional verterbra with enlarged tranverse process on both sides

Lumbosacral Transitional Vertebra- Classification

Type II- *Incomplete lumbarization/sacralization*

- Large transverse process appears to follow the contour of the sacral ala
- Appears like a diarthrodial joint between the transverse process and the sacrum
- Type IIa- Unilateral; Type IIb- Bilateral

Castellvi Classification of LSTV

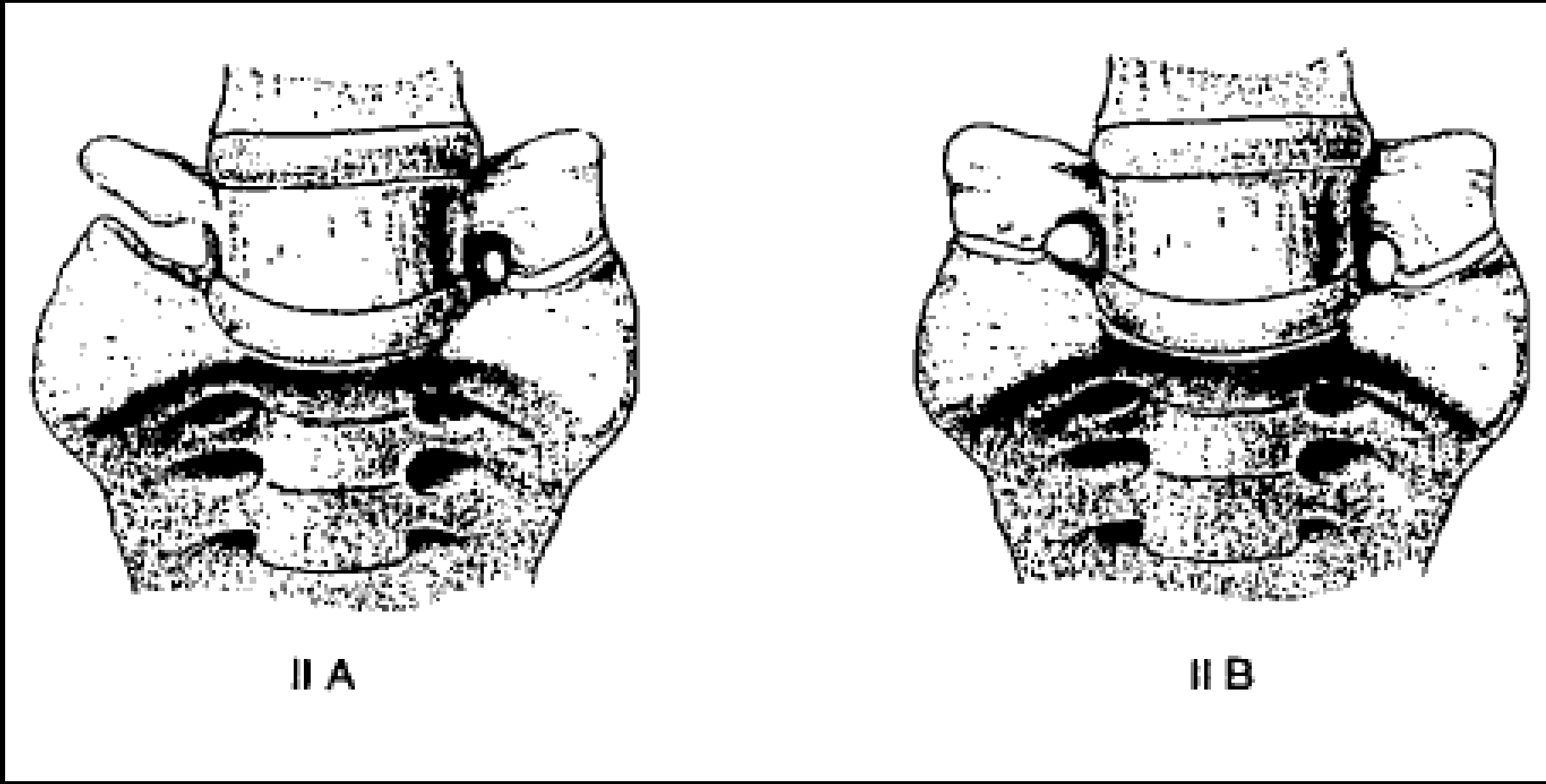

Type IIa

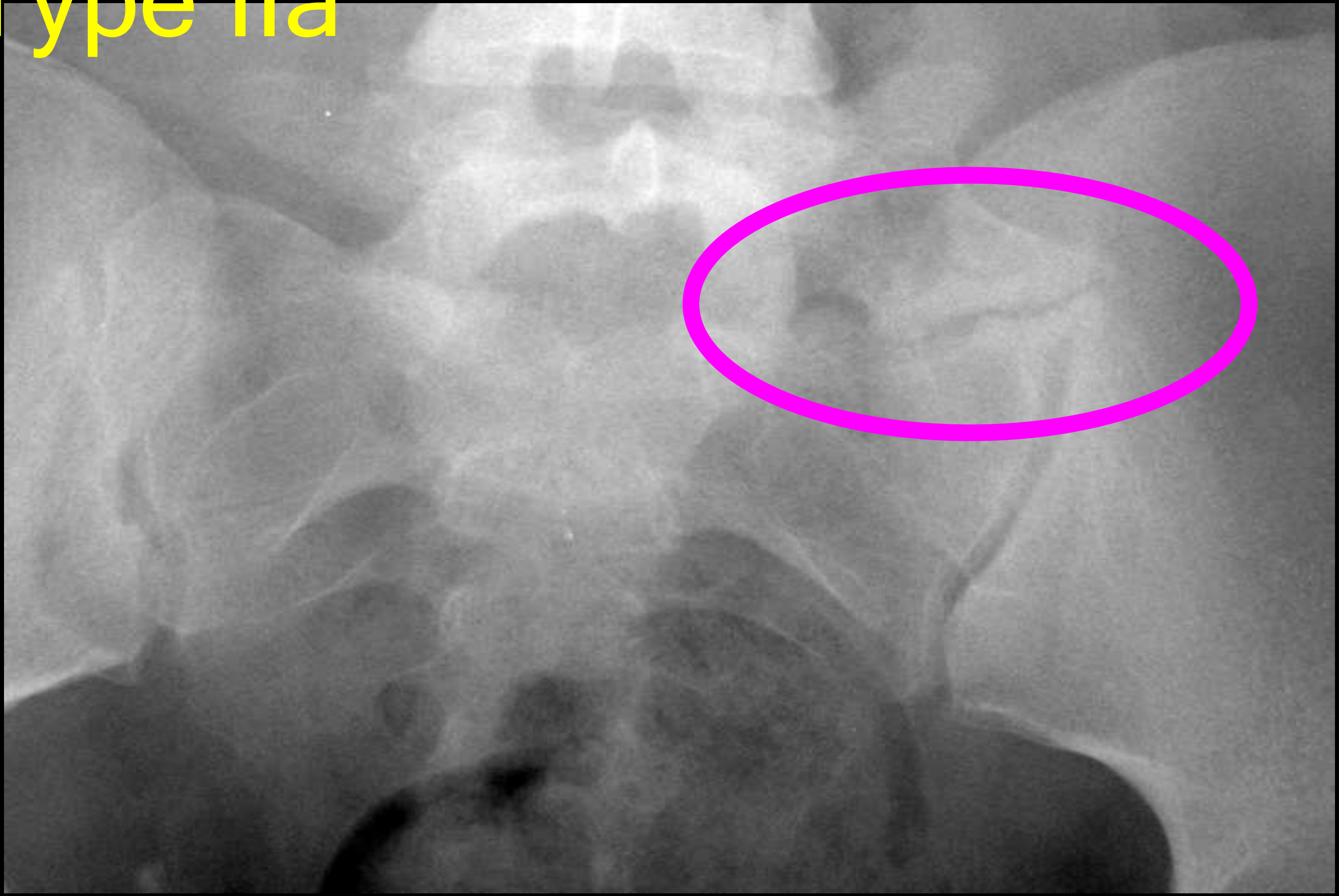

Lumbosacral Transitional Vertebra- Type IIa

Figure - Coronal CT image of lumbosacral junction shows a transitional verterbra with diarthrodial joint appearance on the right side.

Type IIb

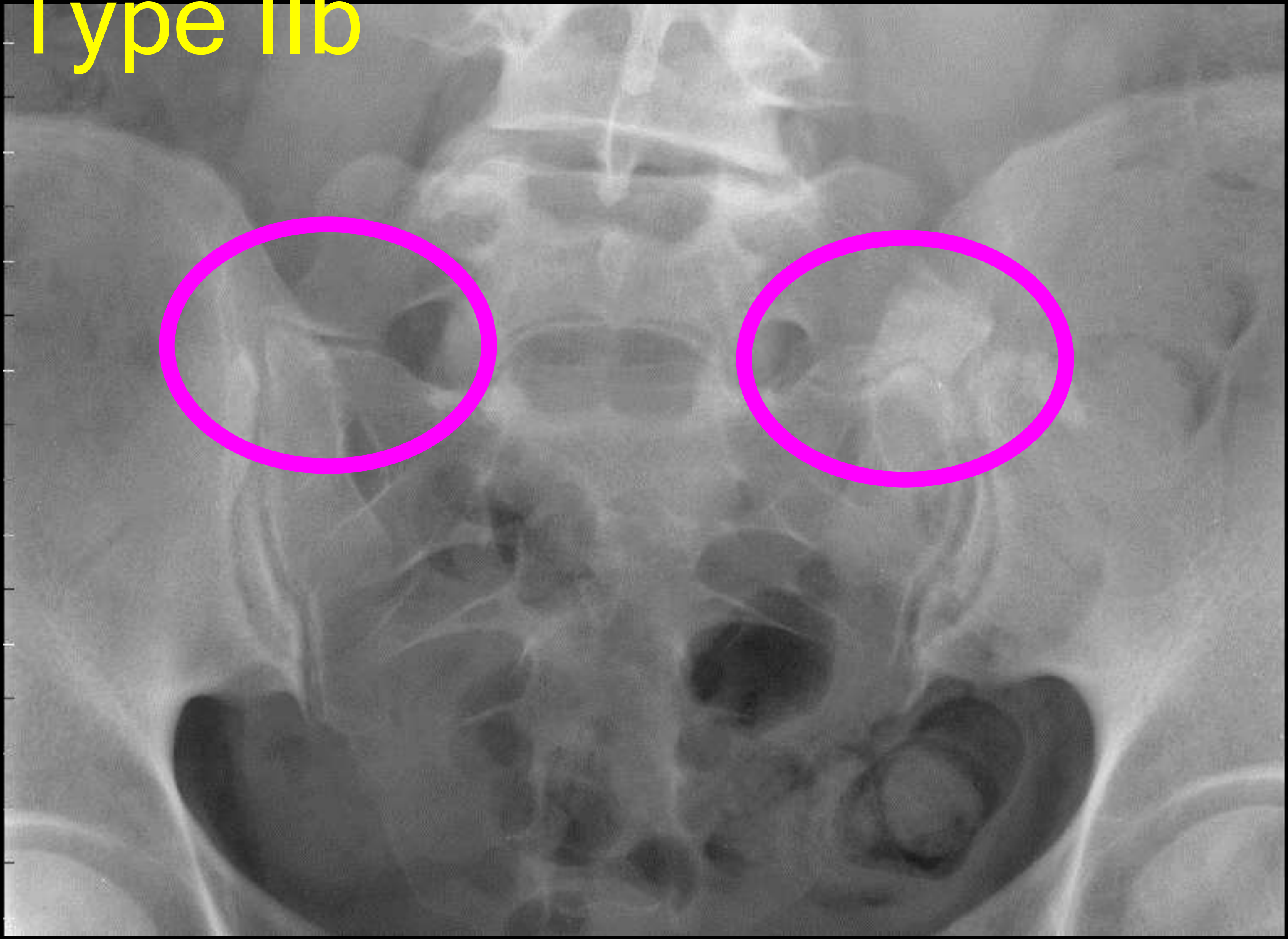

Lumbosacral Transitional Vertebra- Type IIb

Figure - Coronal CT image of lumbosacral junction shows a transitional verterbra with diarthrodial joint appearance on both sides.

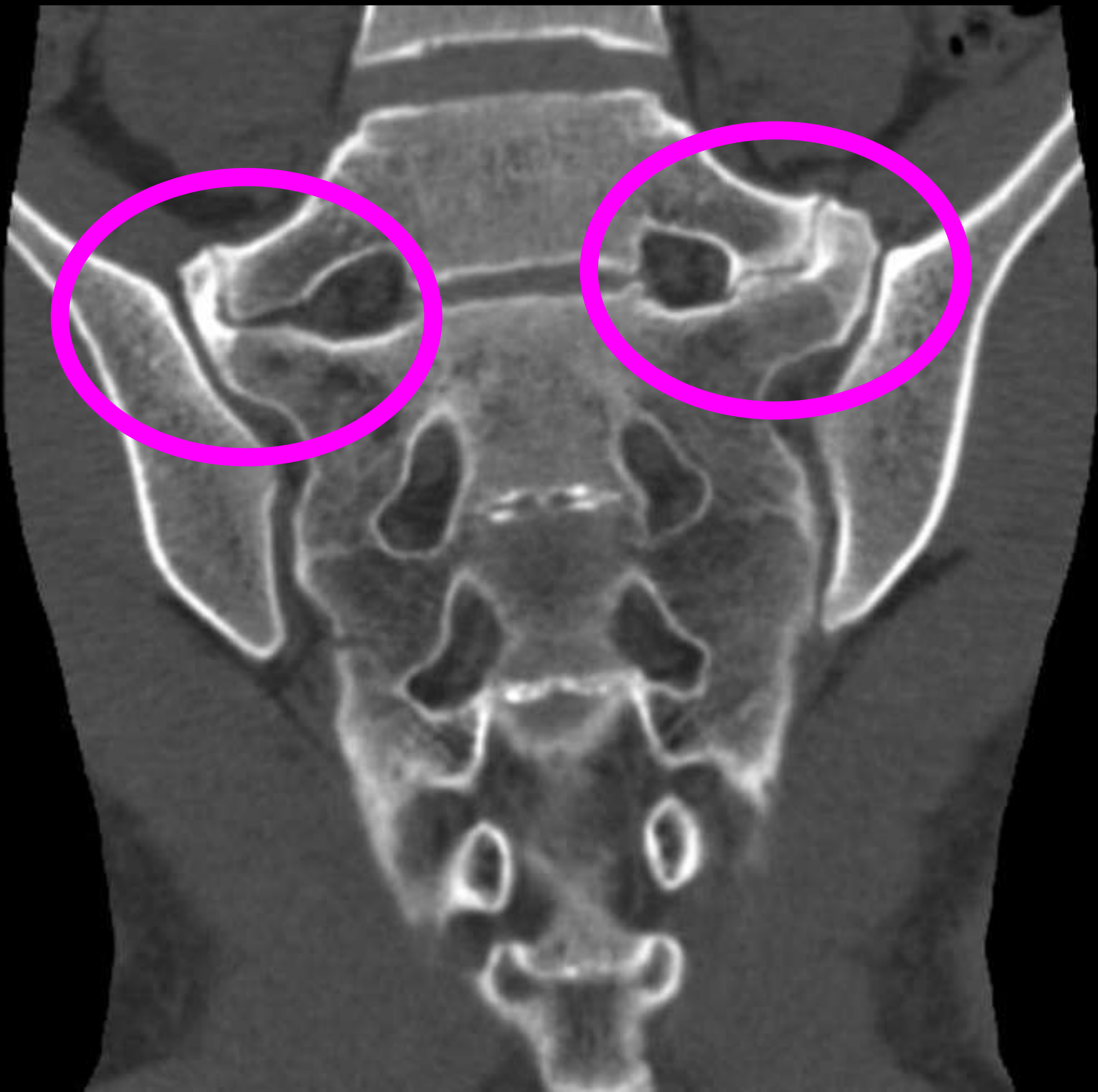

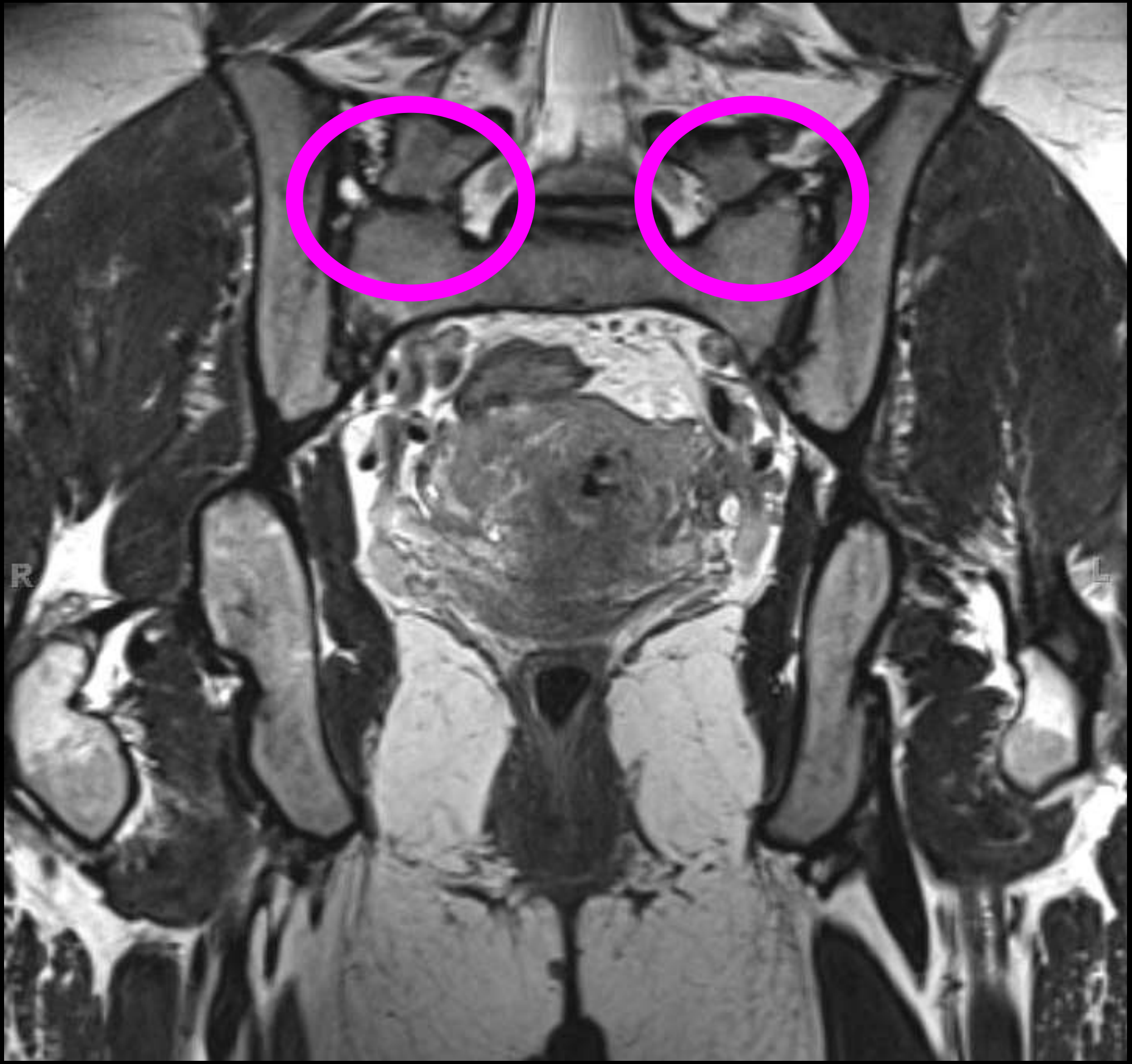
R
L

PELVIS W/CONTRAST CT
(Pelvis Bone 3.0 MPR)
SeriesNo: 1000 (9)
Slice 5 of 5
Key Image
R
KEY
Key Image
P
UV_S.35.4.190 (EB_CT11_SZ1311)
VisualPACS_KO (SIEMENS) Tesla
W: 258 L:128
PELVIS W/CONTRAST CT
(Pelvis Bone 3.0 MPR)
SeriesNo: 1000 (9)
Slice 4 of 5
Key Image
A
2012-05-18
R
KEY
Key Image
P
UV_S.35.4.190 (EB_CT11_SZ1311)
VisualPACS_KO (SIEMENS) Tesla

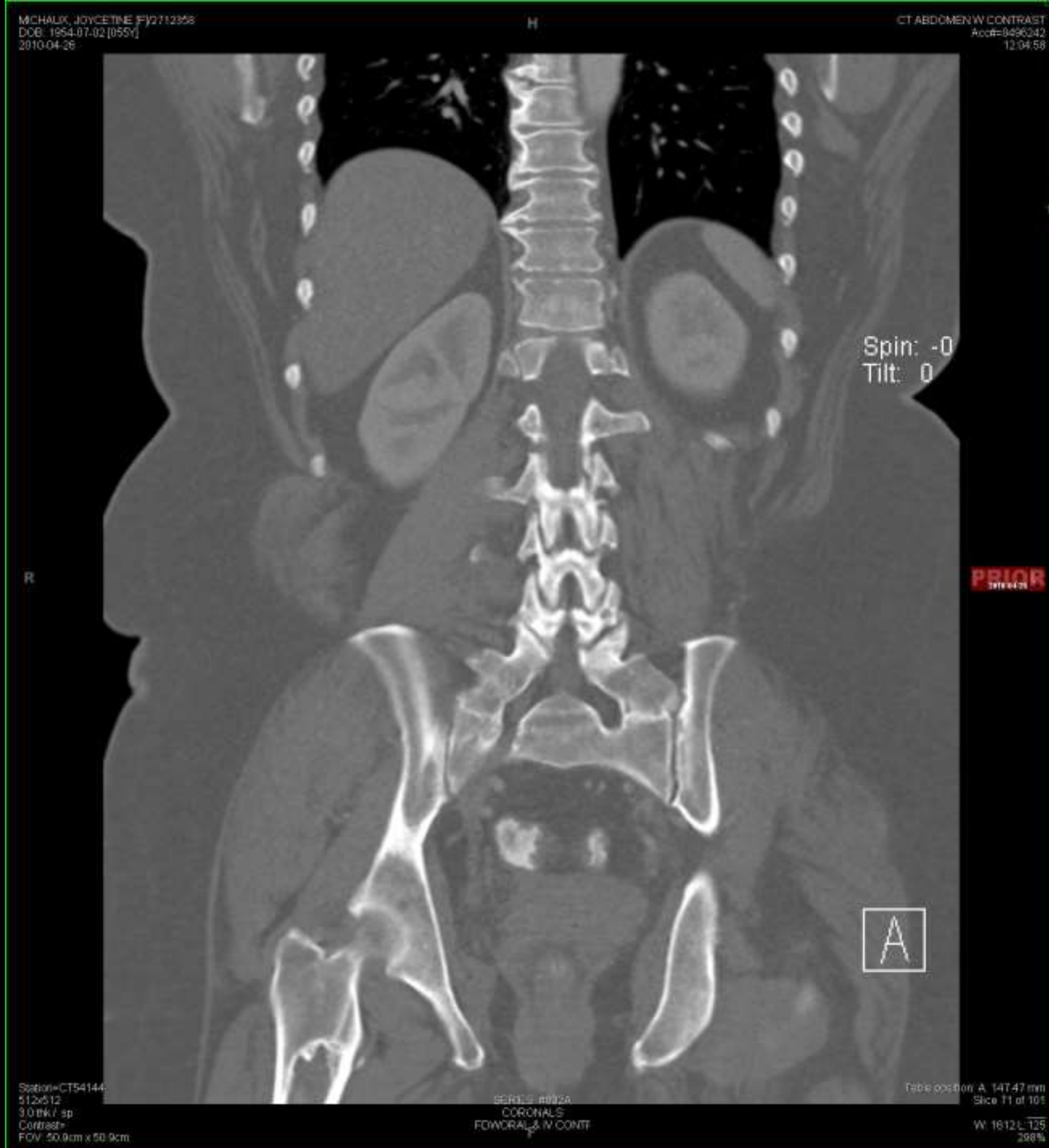
MICHAUX, JOYCETINE [F]/2712358
DOB: 1954-07-02 [055Y]
2010-04-26
H
CT ABDOMEN W CONTRAST
Acc#=8496242
12:04:58
Spin: -0
Tilt: 0
R
PRIOR
A
Station=CT54144
512x512
3.0 thk / sp
Contrast+
FOV: 50.9cm x 50.9cm
SERIES #002A
CORONALS
FDWORAL & IV CONT
F
Table position: A 147.47 mm
Slice 71 of 101
W: 1612 L: 125
298%

Lumbosacral Transitional Vertebra- Classification

Type III- *Complete lumbarization/ sacralization*

- Similar to Type II
- Instead of diarthrodial joint, there is osseous fusion between the transverse process and the sacrum
- Type IIIa- Unilateral; Type IIIb- Bilateral

Castellvi Classification of LSTV

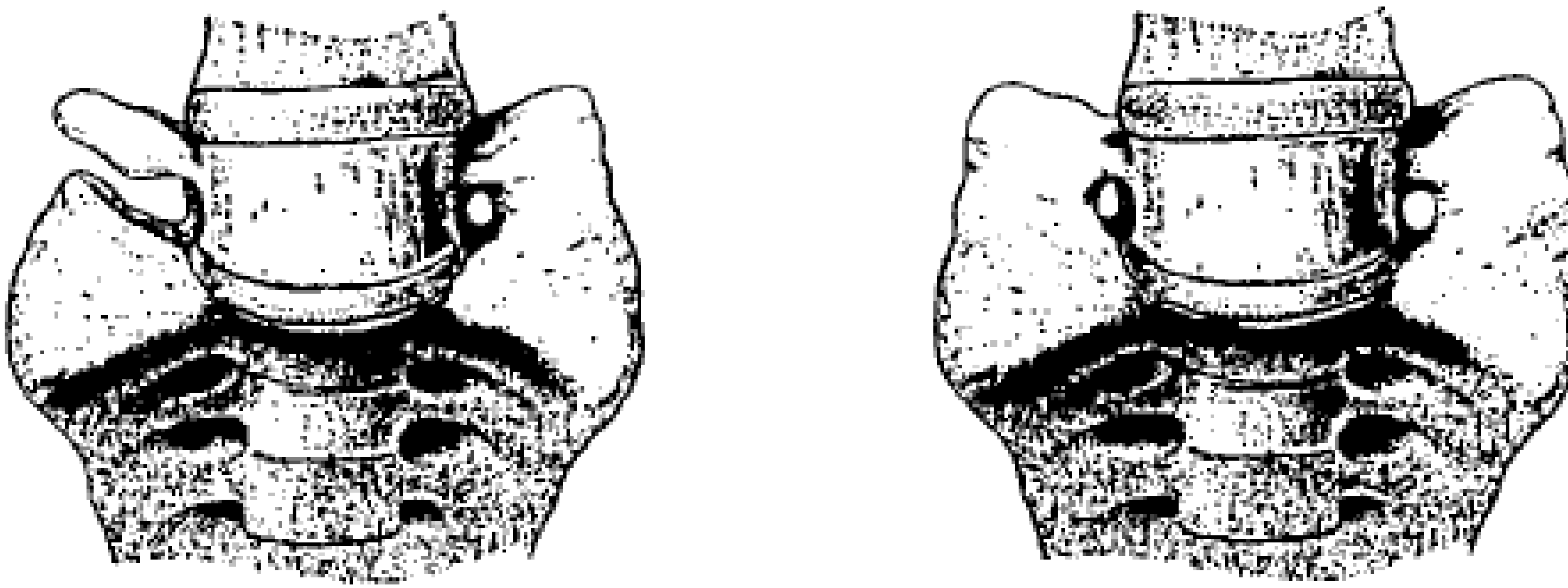

III A III B

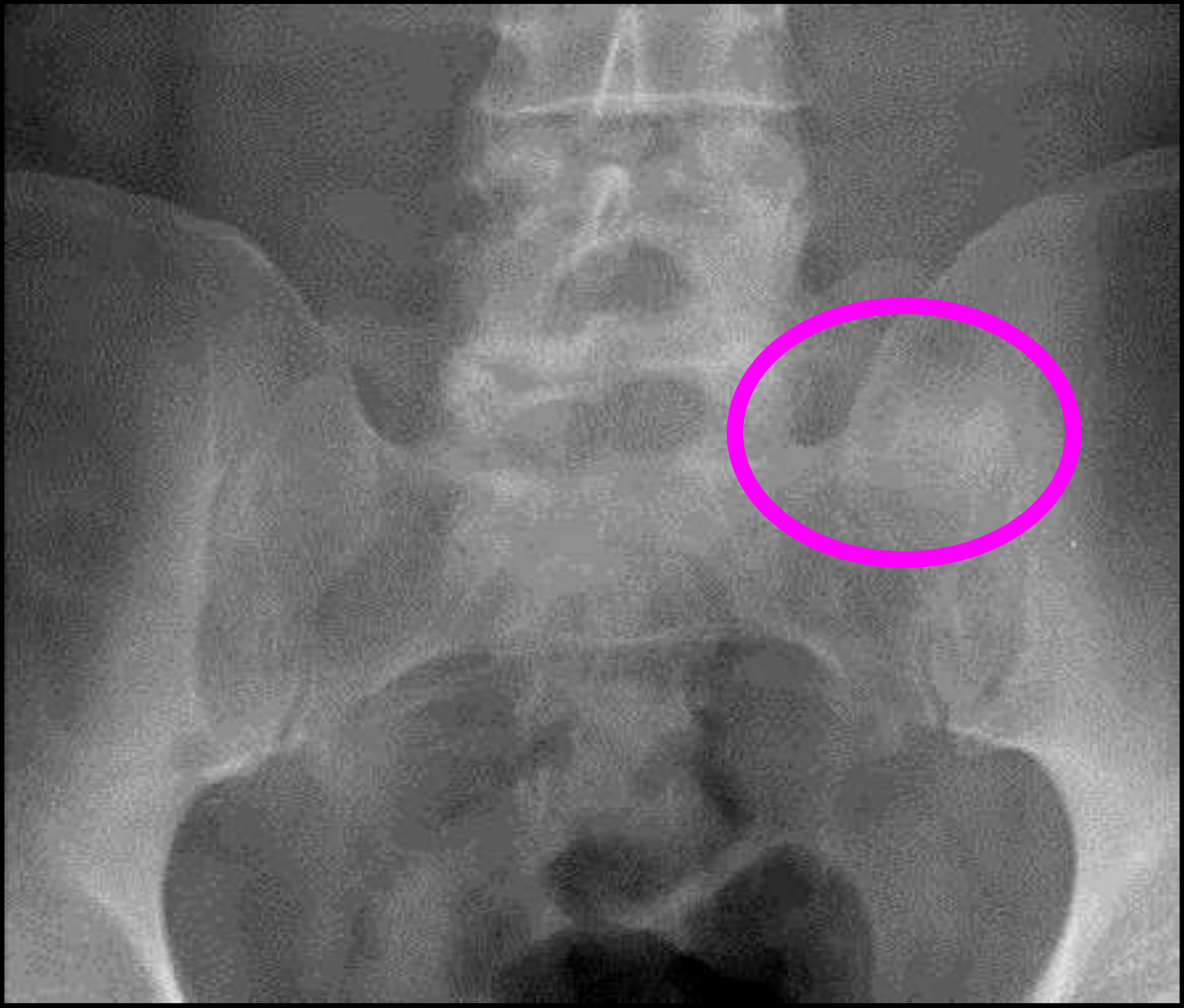

Lumbosacral Transitional Vertebra- Type IIIa

Figure - Coronal CT image of lumbosacral junction shows a transitional verterbra with fusion on left side

Lumbosacral Transitional Vertebra- Type IIIb

Figure - Coronal CT image of lumbosacral junction shows a transitional verterbra with fusion on both sides

Lumbosacral Transitional Vertebra- Classification

Type IV- *Mixed*

- Type II on one side and Type III on the other.

Castellvi Classification of LSTV

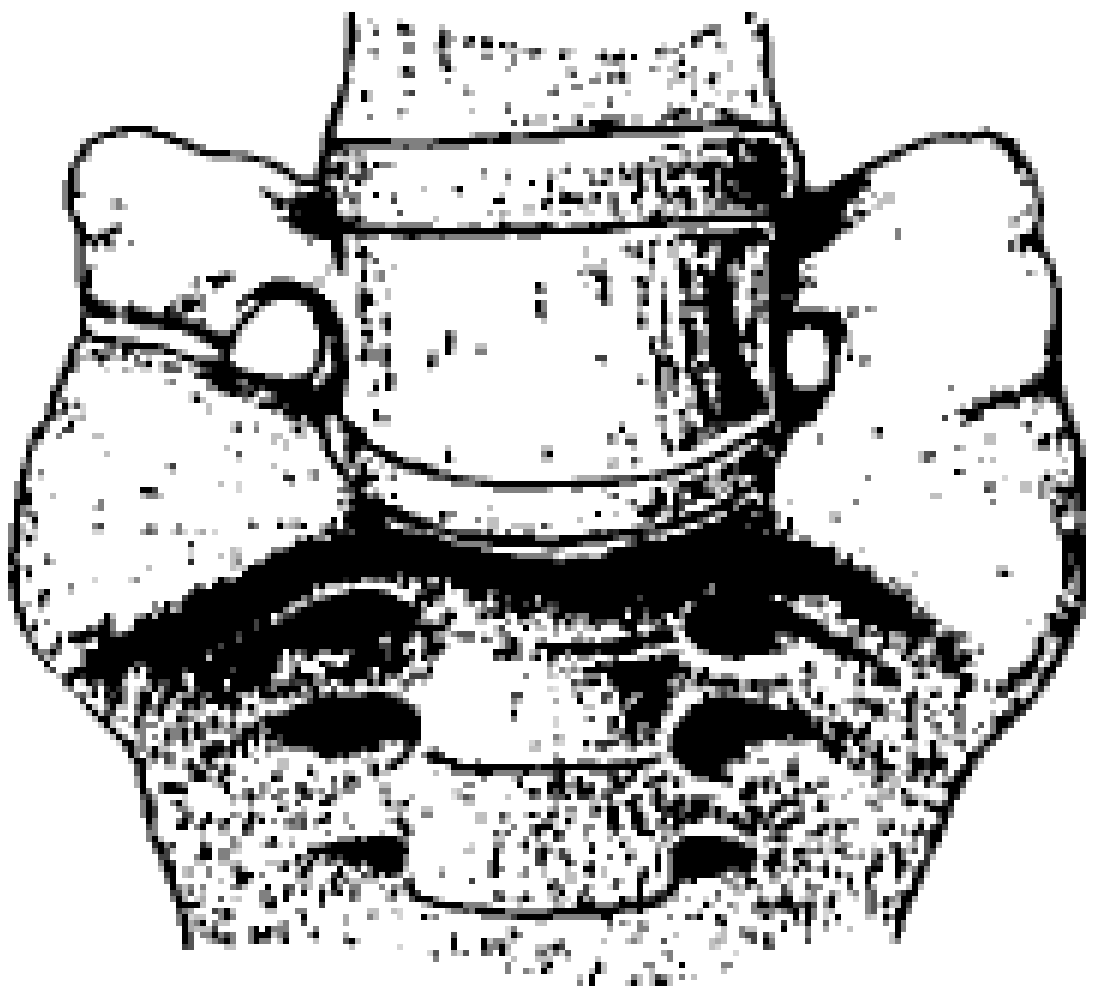

IV

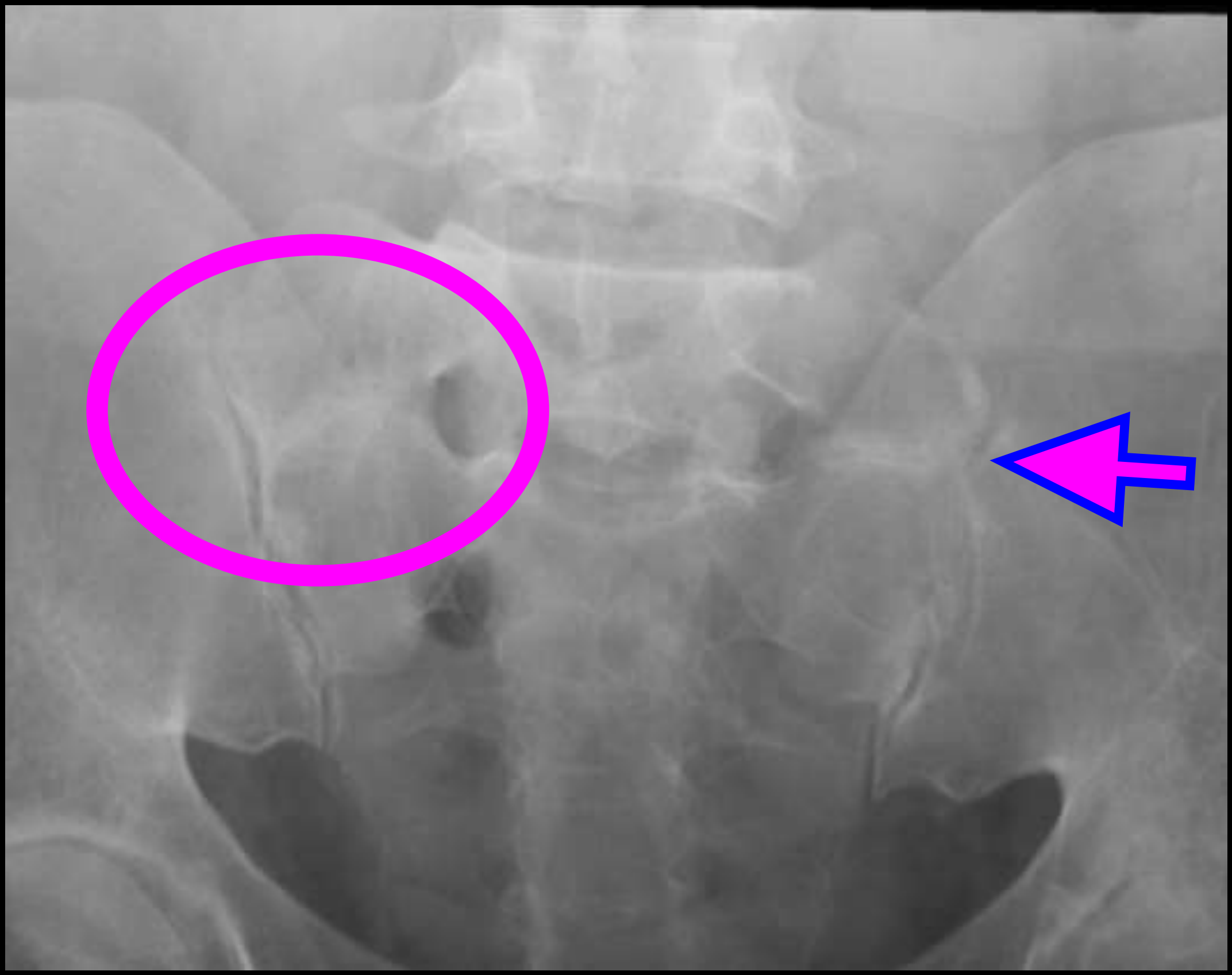

Lumbosacral Transitional Vertebra- Type IV

Figure - Coronal CT image of lumbosacral junction shows a transitional verterbra with fusion on left and a diarthrodial looking joint on the right side

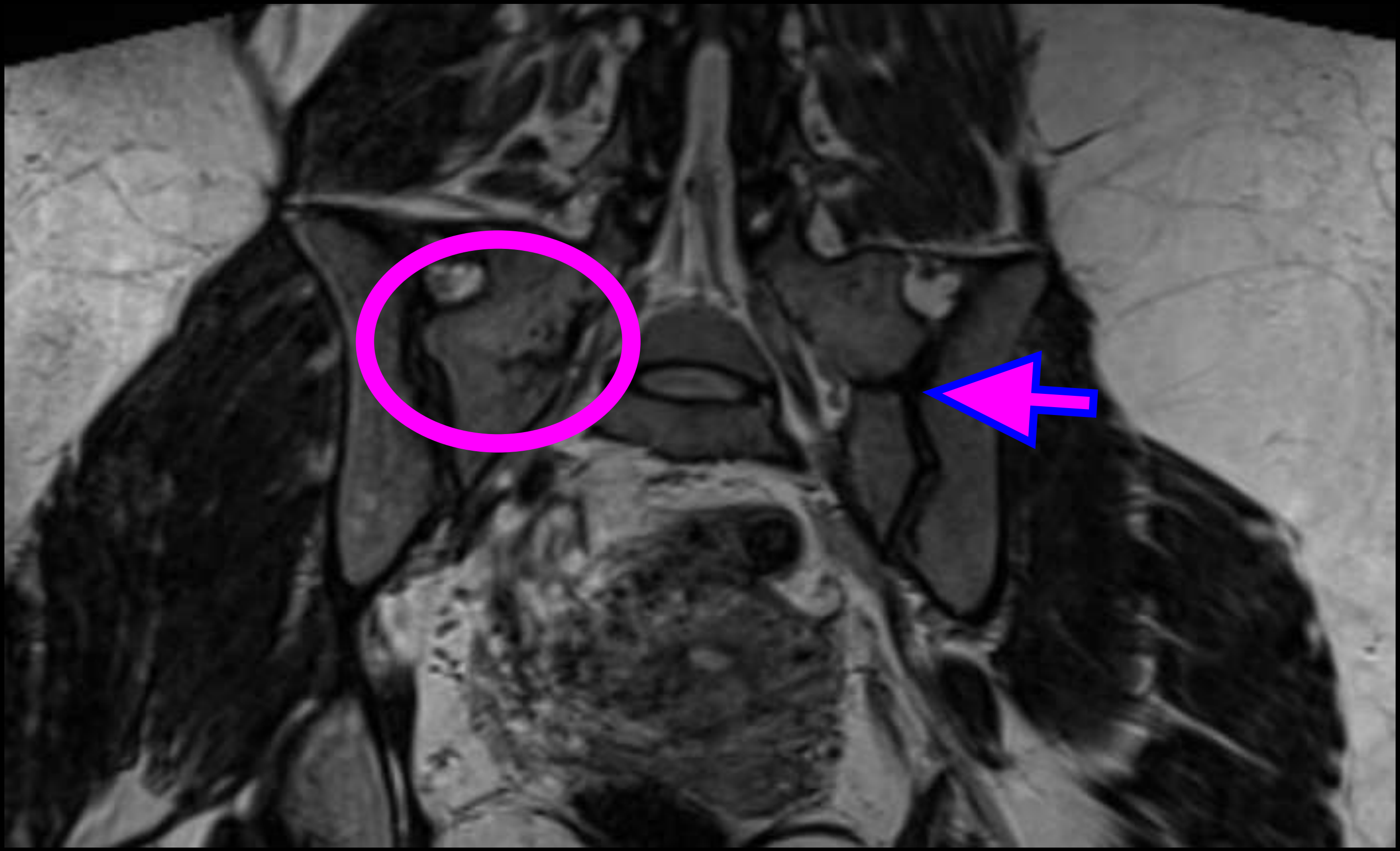

Transitional Segments
Bertolotti's Syndrome

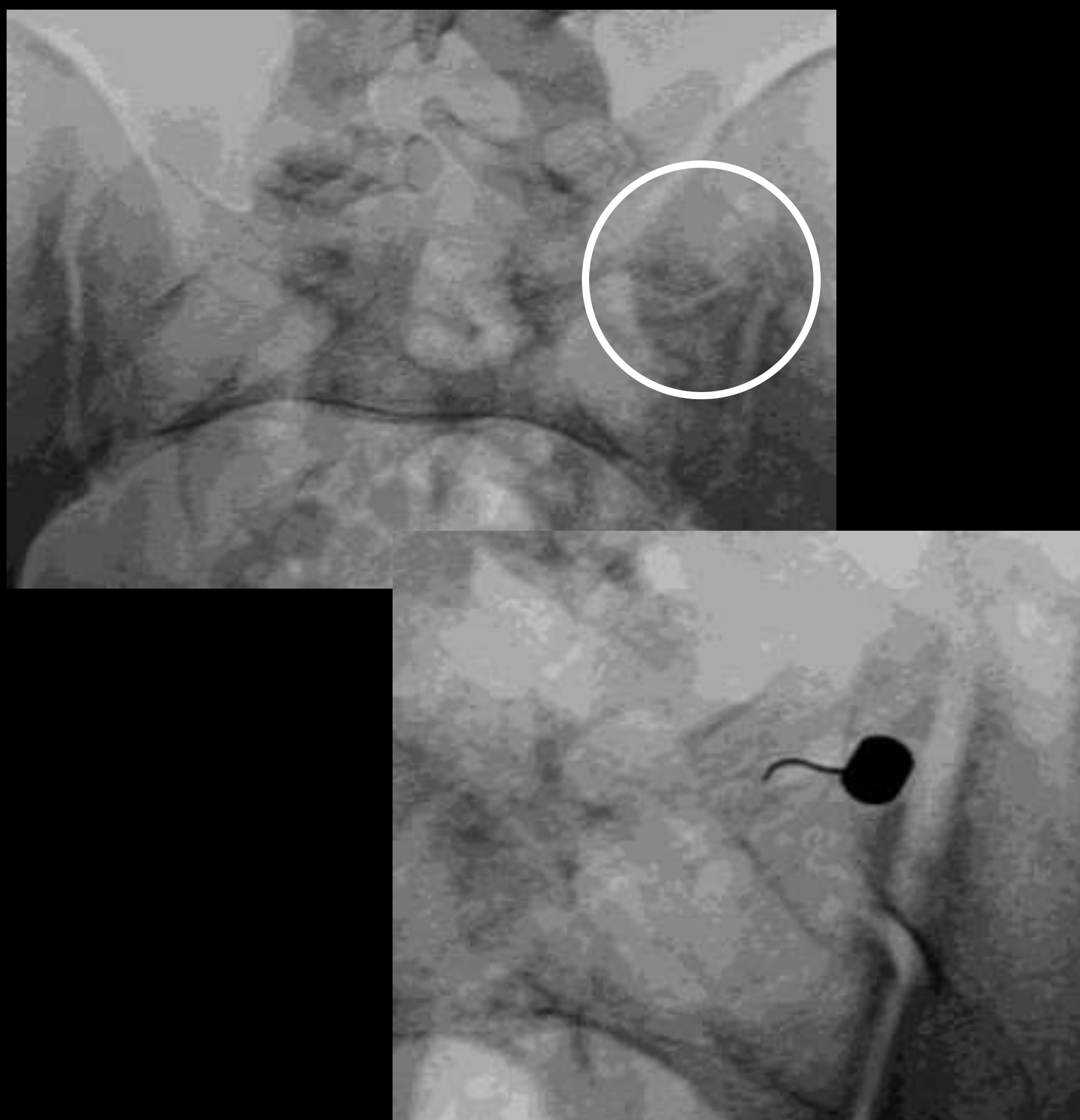

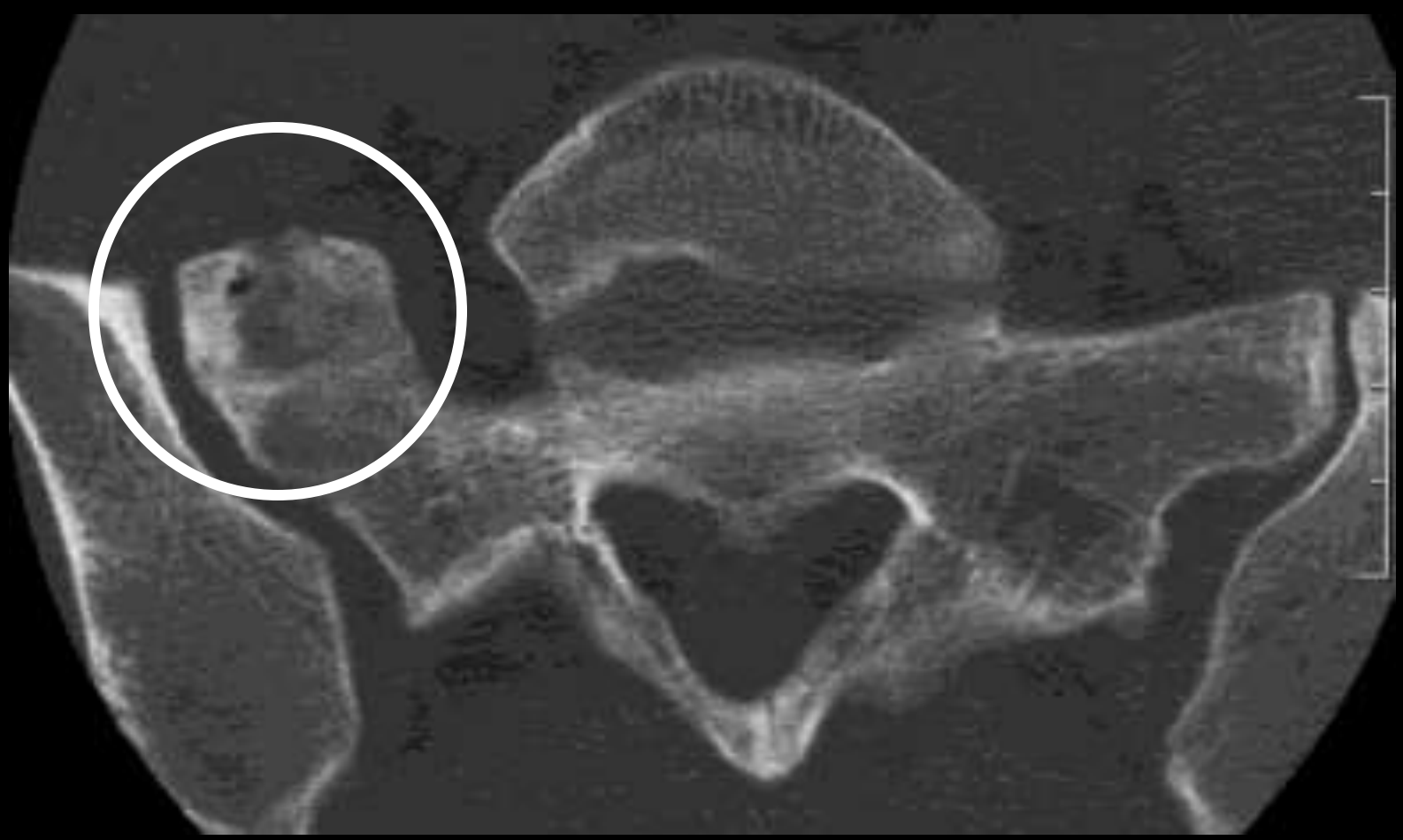

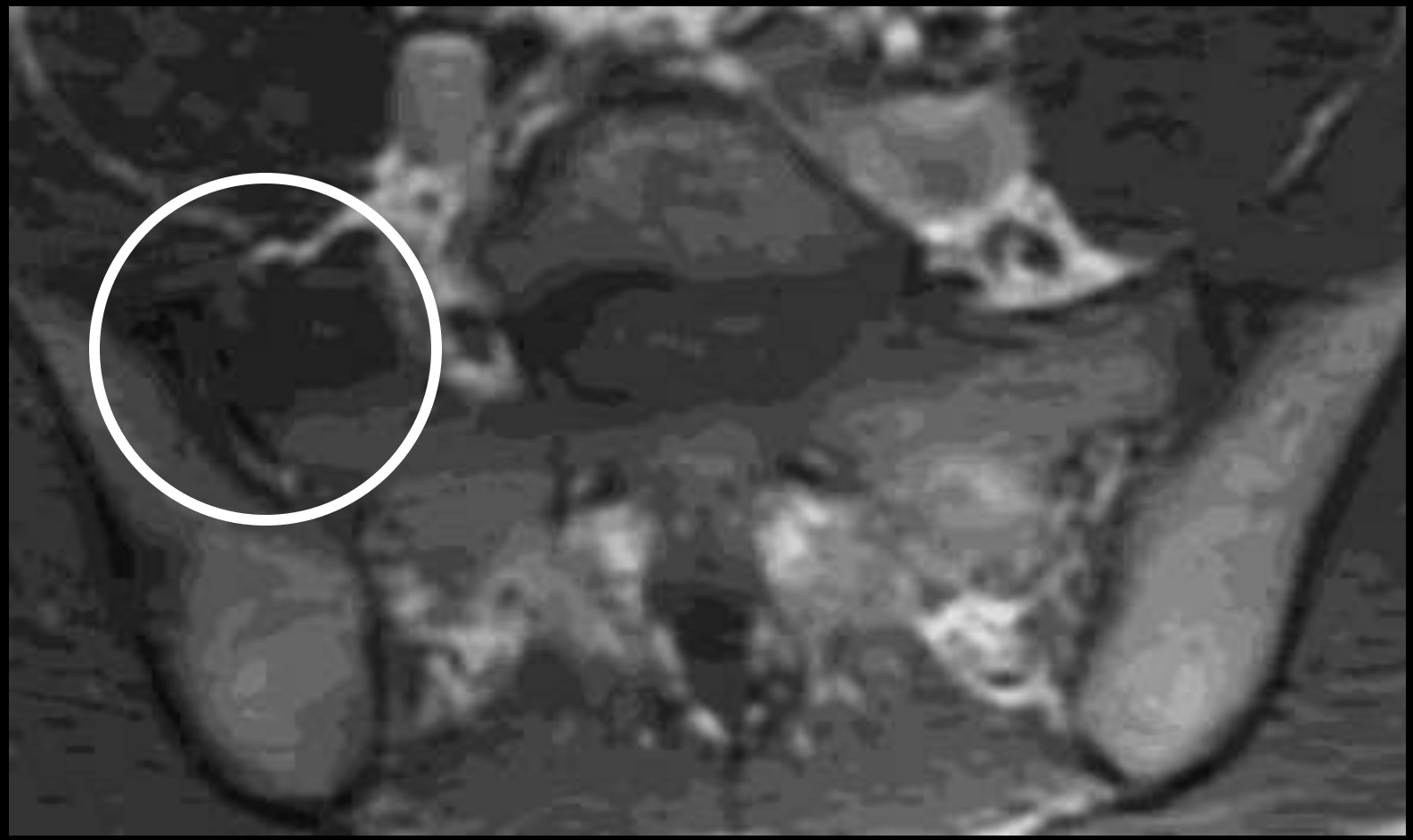

Courtesy of Tim Maus, M.D.

Bertolotti Syndrome

Transitional segment

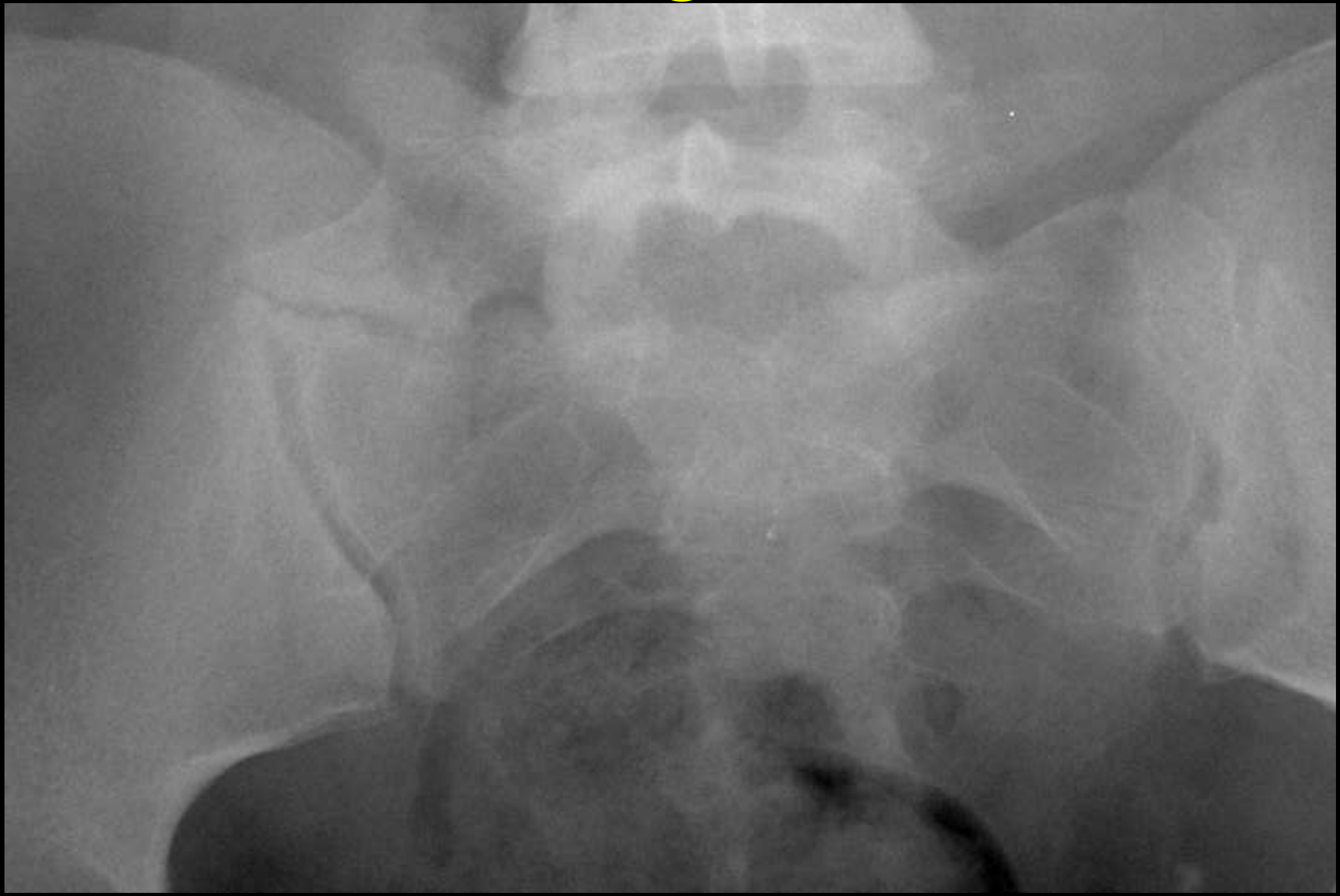

Bertolotti's Syndrome

Courtesy of Tim Maus, M.D.

Bertolotti's Syndrome

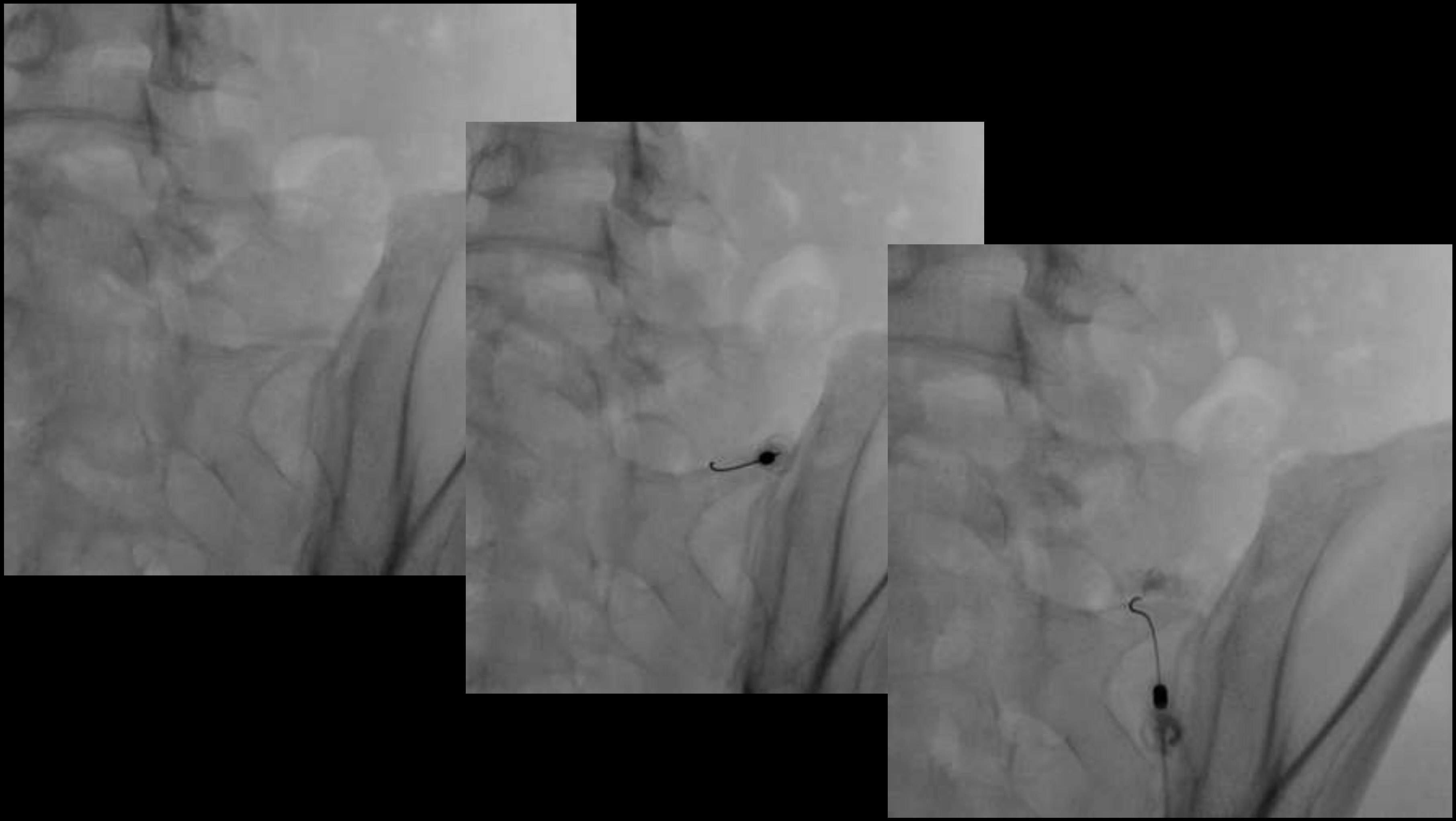

Courtesy of Tim Maus, M.D.

Bertolotti’s Syndrome

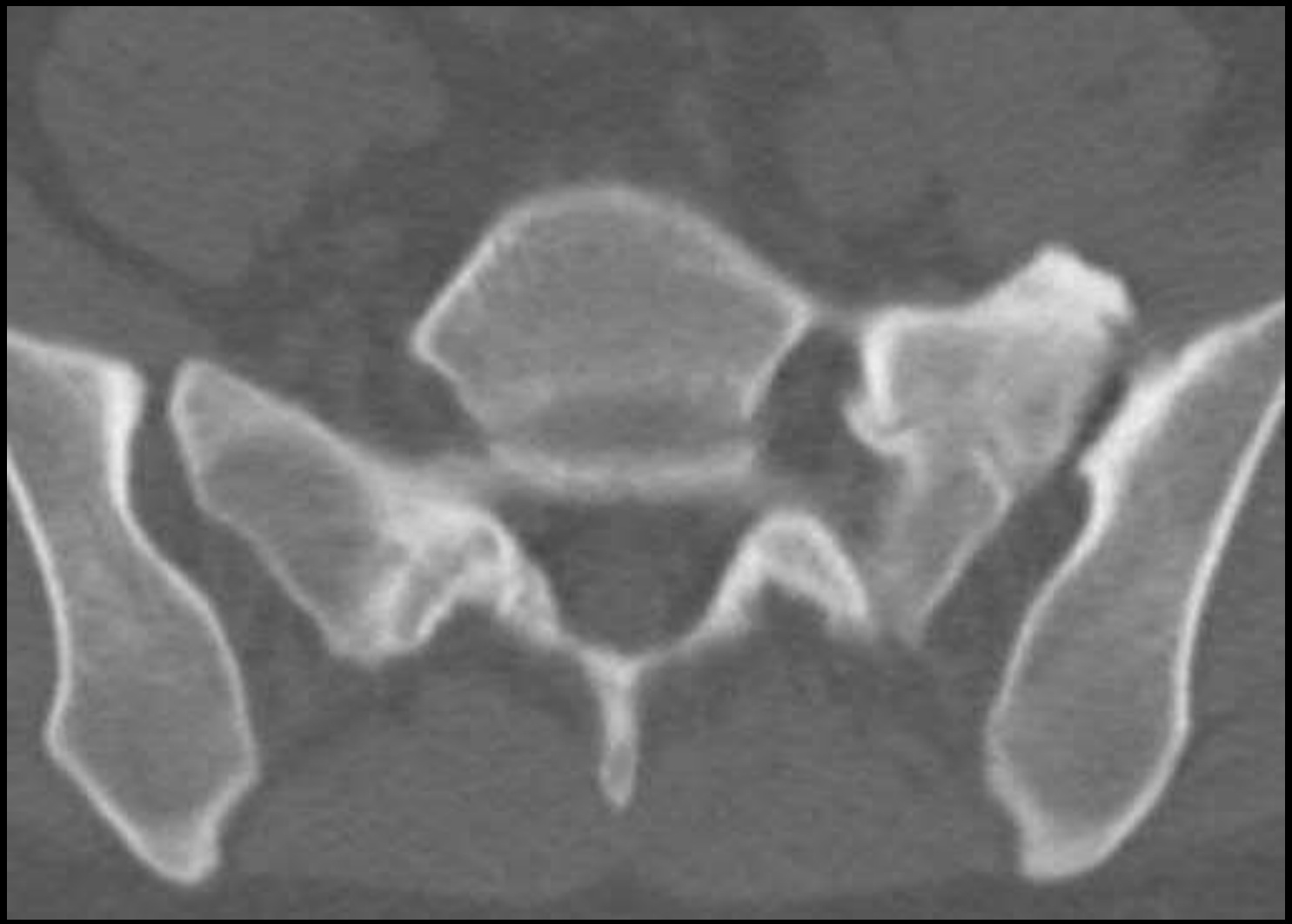

Courtesy of Tim Maus, M.D.

Bertolotti's Syndrome

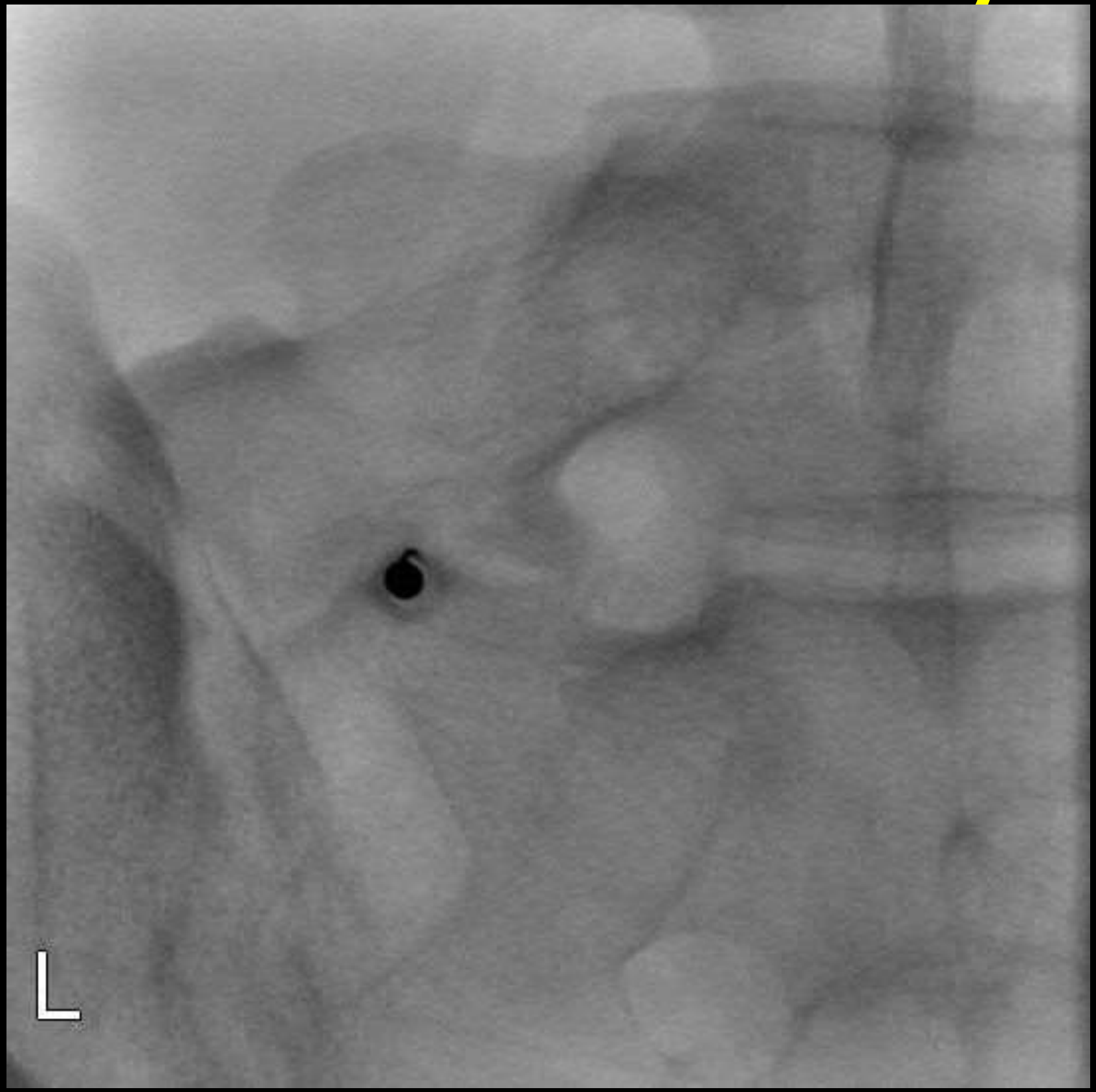

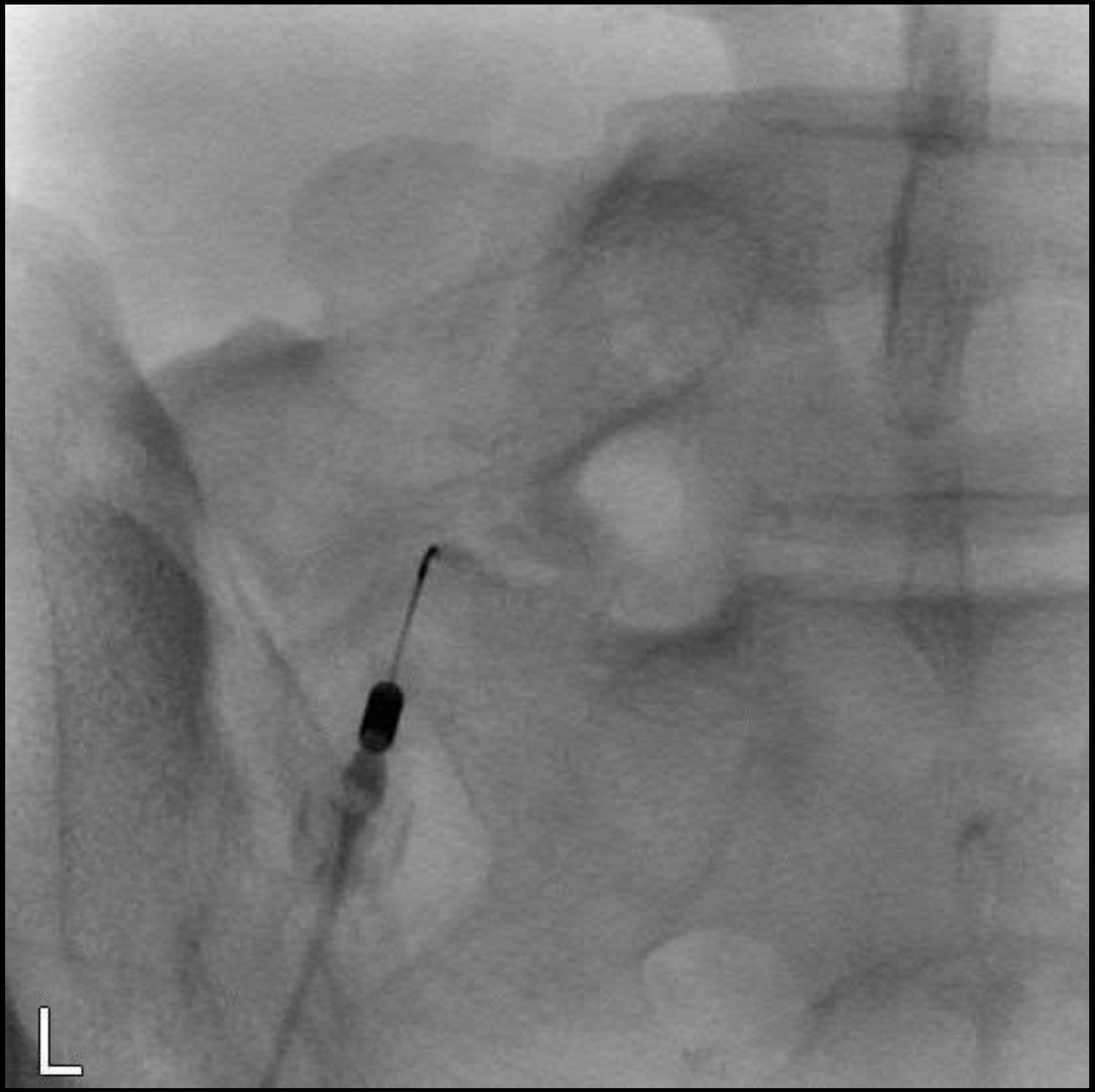

Courtesy of Tim Maus, M.D.

Bertolotti's Syndrome

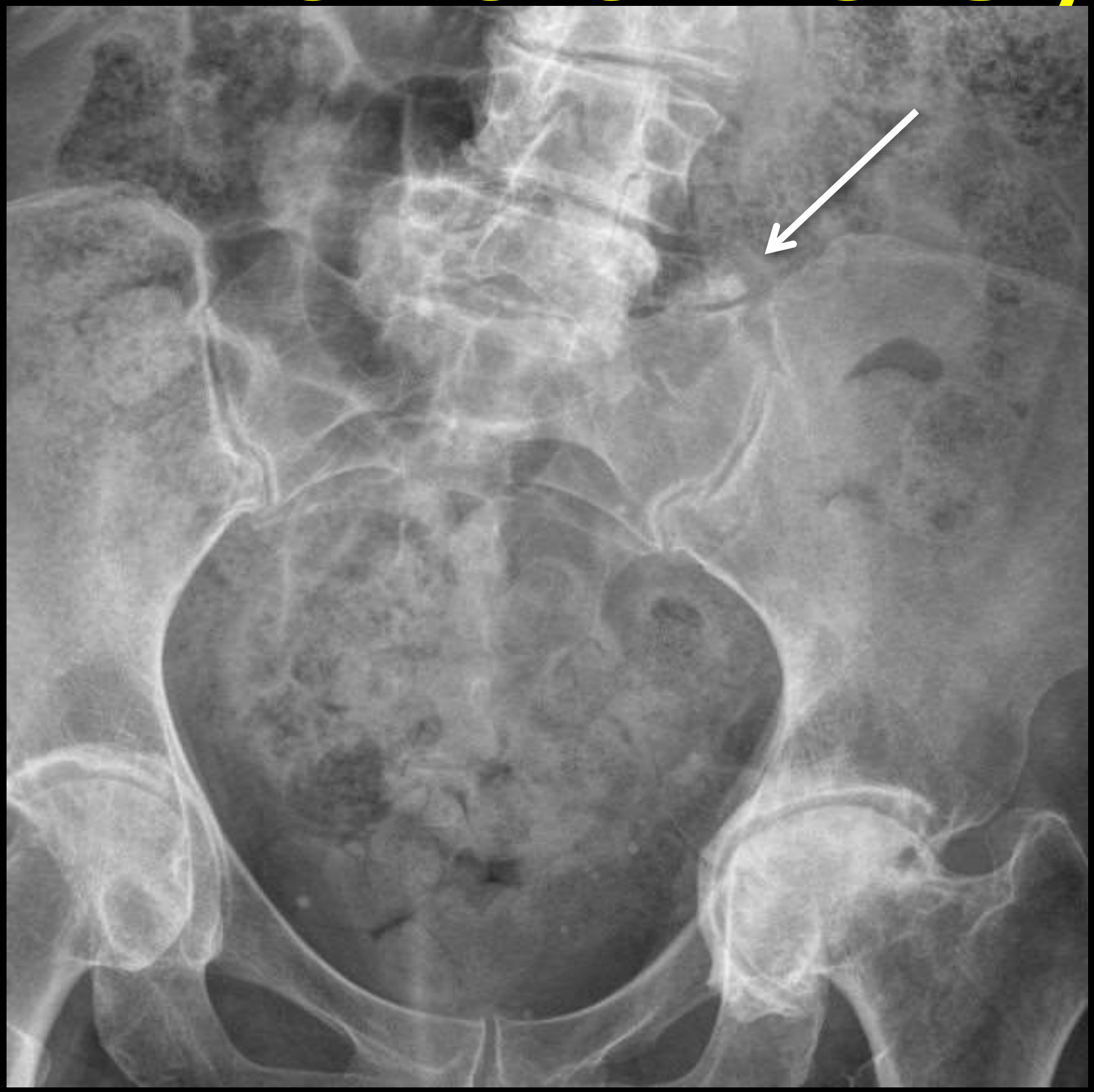

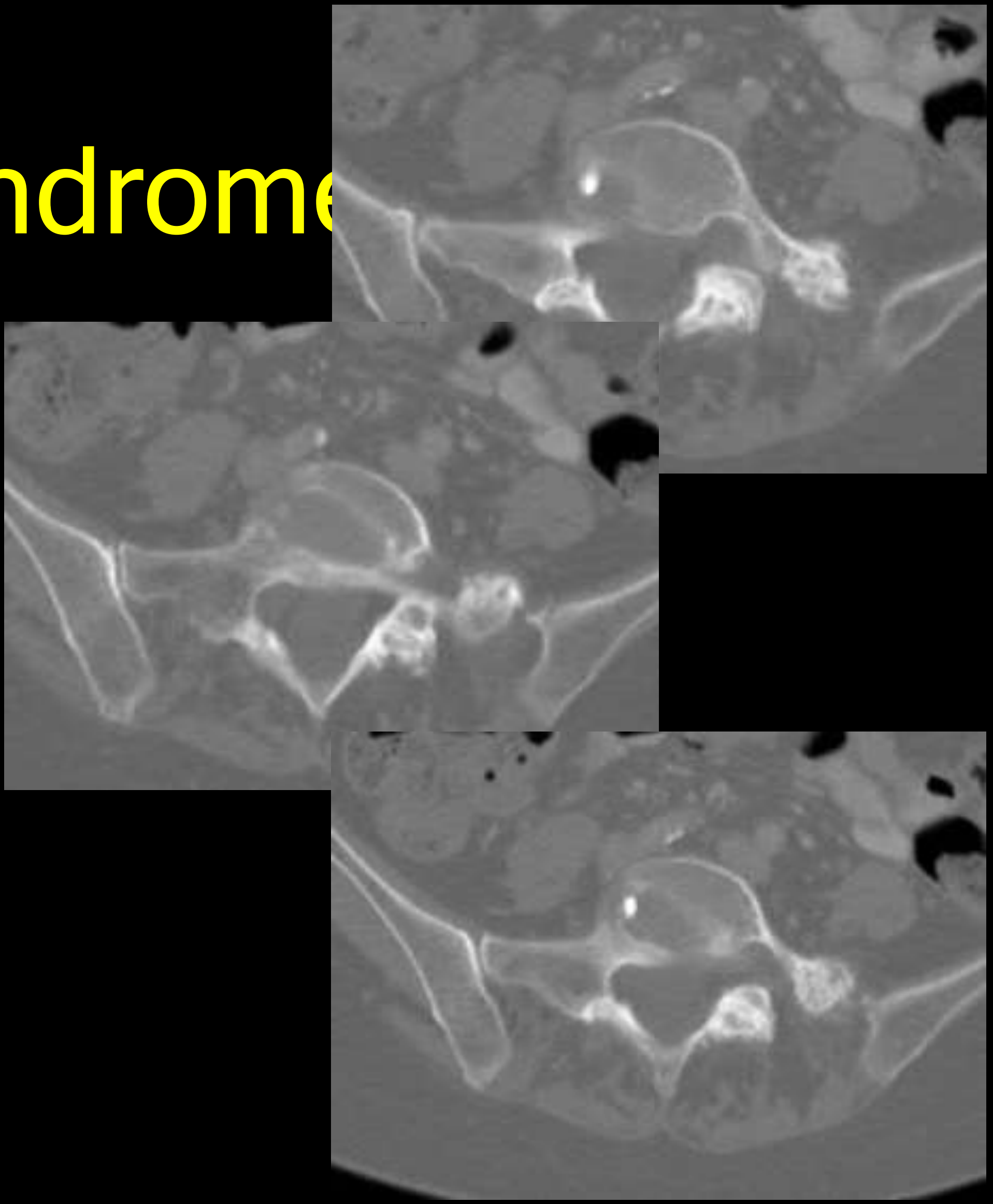

Courtesy of Tim Maus, M.D.

Berolotti’s Syndrome

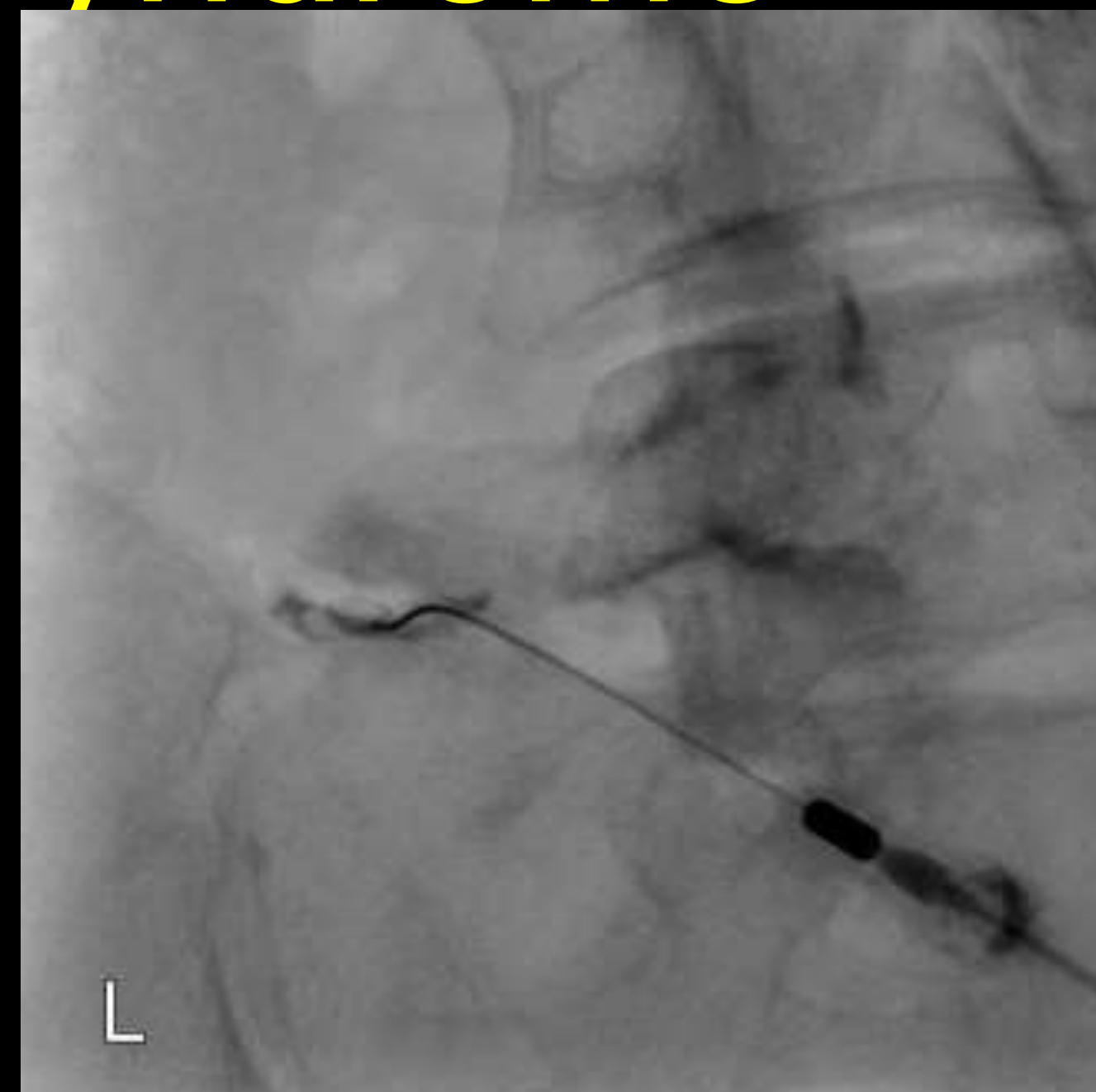

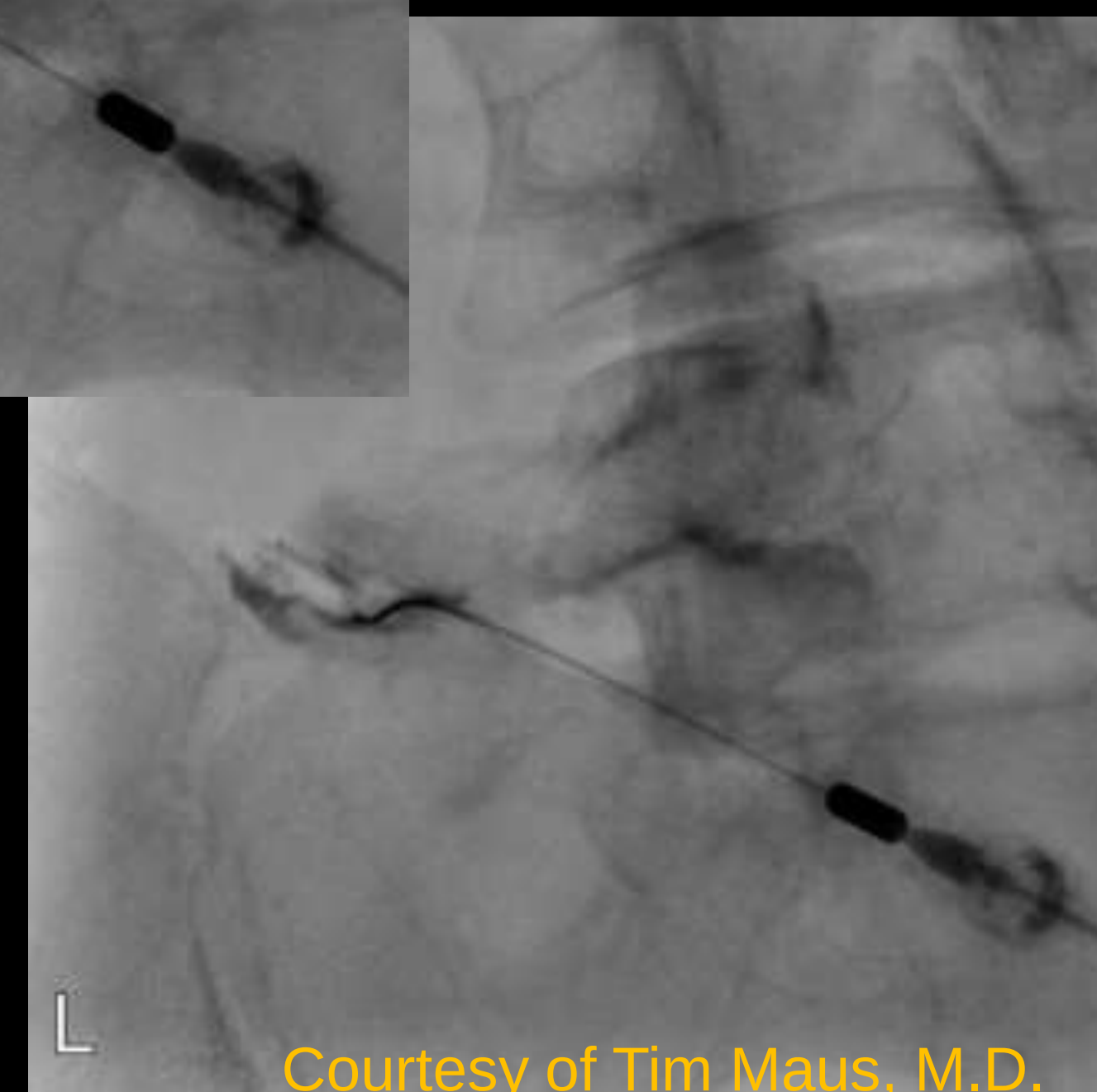

Bertolotti's Syndrome

Courtesy of Tim Maus, M.D.

Bertolotti's Syndrome

Courtesy of Tim Maus, M.D.

Type of Transitional Verterba



Pain Physician. 2006;9:53-56, ISSN 1533-3159

A Prospective Observational Report

Lumbosacral Transitional Vertebrae: Incidence in a Consecutive Patient Series

Elva G. Delport, MD, Tony R. Cucuzzella, MD, Nancy Kim, MD, Julie Marley, PT, Dip MDT, Christine Pruitt, RN, MS, and Anton G. Delport, PT, Dip MDT

Results

Prevalence of Lumbosacral Transitional Vertebral Types		
TYPE	Percentage	Number
Type Ia	4.3	13/300
Type Ib	2.3	7/300
Type IIa	6	18/300
Type IIb	9.7	29/300
Type IIIa	1	3/300
Type IIIb	4	12/300
Type IV	2	6/300
Total n=	88/300	

LSTV Identification on MRI

features described for identifying LSTV on lateral projection/sagittal imaging

- "squared" appearance vertebral body morphology
- decreased intervertebral disc height at the lumbosacral junction
- S1-2 intervertebral disc morphology

Wigh RE. The thoracolumbar and lumbosacral transitional junctions. Spine (Phila Pa 1976). 1980 May-Jun;5(3):215-222.

Nicholson AA, Roberts GM, Williams LA. The measured height of the lumbosacral disc in patients with and without transitional vertebrae. *Br J Radiol* 1988;61: 454–455.

O'Driscoll CM, Irwin A, Saifuddin A. Variations in morphology of the lumbosacral junction on sagittal MRI: correlation with plain radiography. *Skeletal Radiol* 1996;25: 225–230.

Identification of LSTV by IVD morphology

O'Driscoll Type 1

- No disc material between S1 & remainder of sacrum (non-LSTV)

O'Driscoll Type 2

- Small residual disc between S1 and remainder of sacrum, AP diameter of disc being less than AP diameter of sacrum

O'Driscoll Type 3

- Well-formed residual disc between S1 & remainder of sacrum, AP diameter of disc equaling the AP diameter of sacrum

O'Driscoll Type 4

- Well-formed residual disc with abnormal "squaring" of presumed upper sacral segment on lateral view

O'Driscoll Classification of first sacral IVD (S1-2)

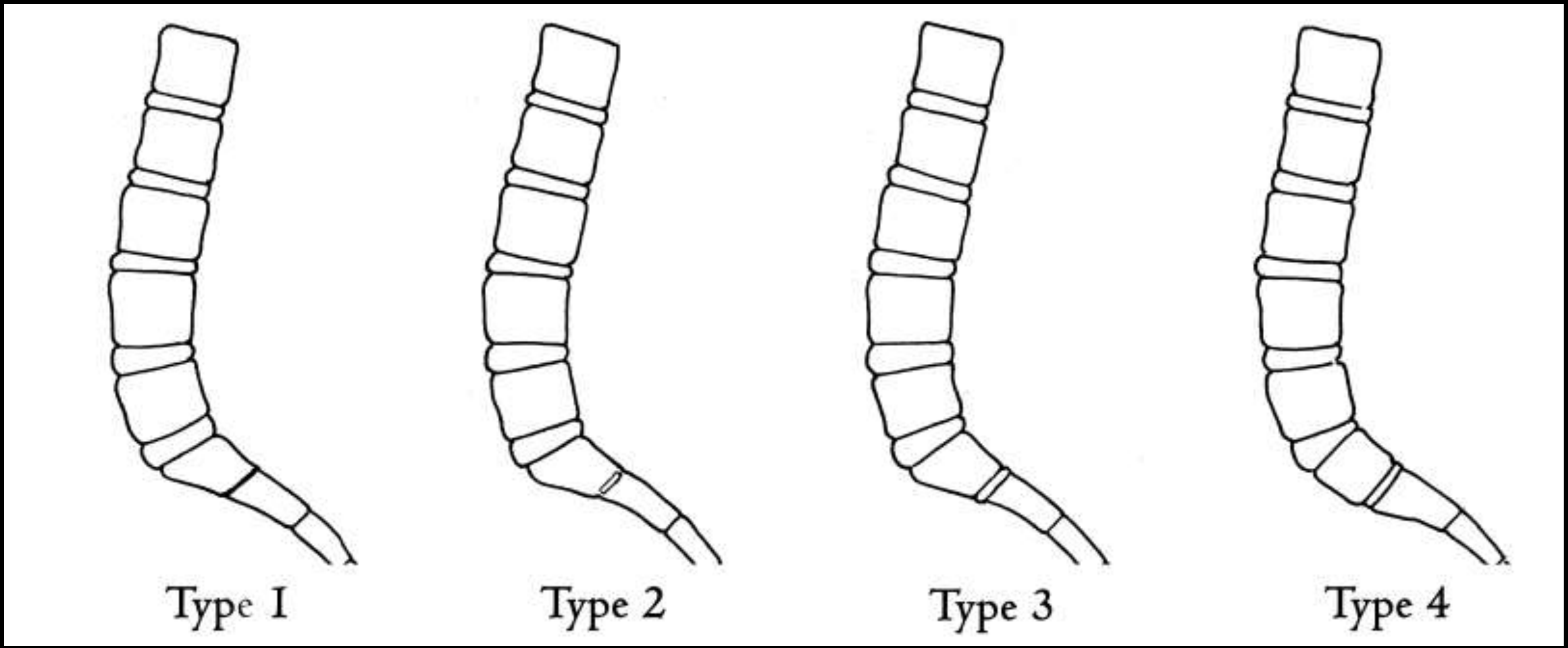

Type 1

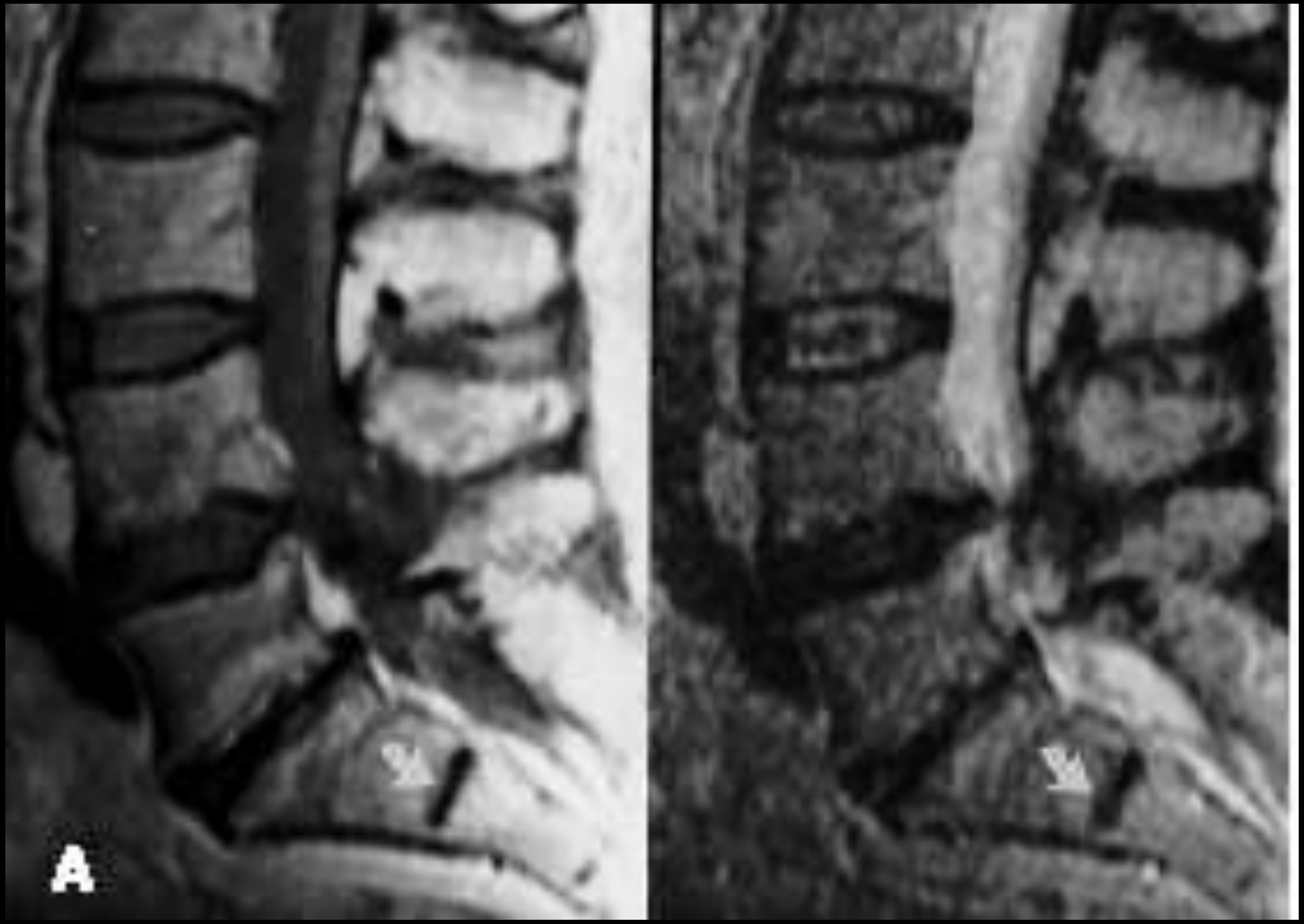

Type 2

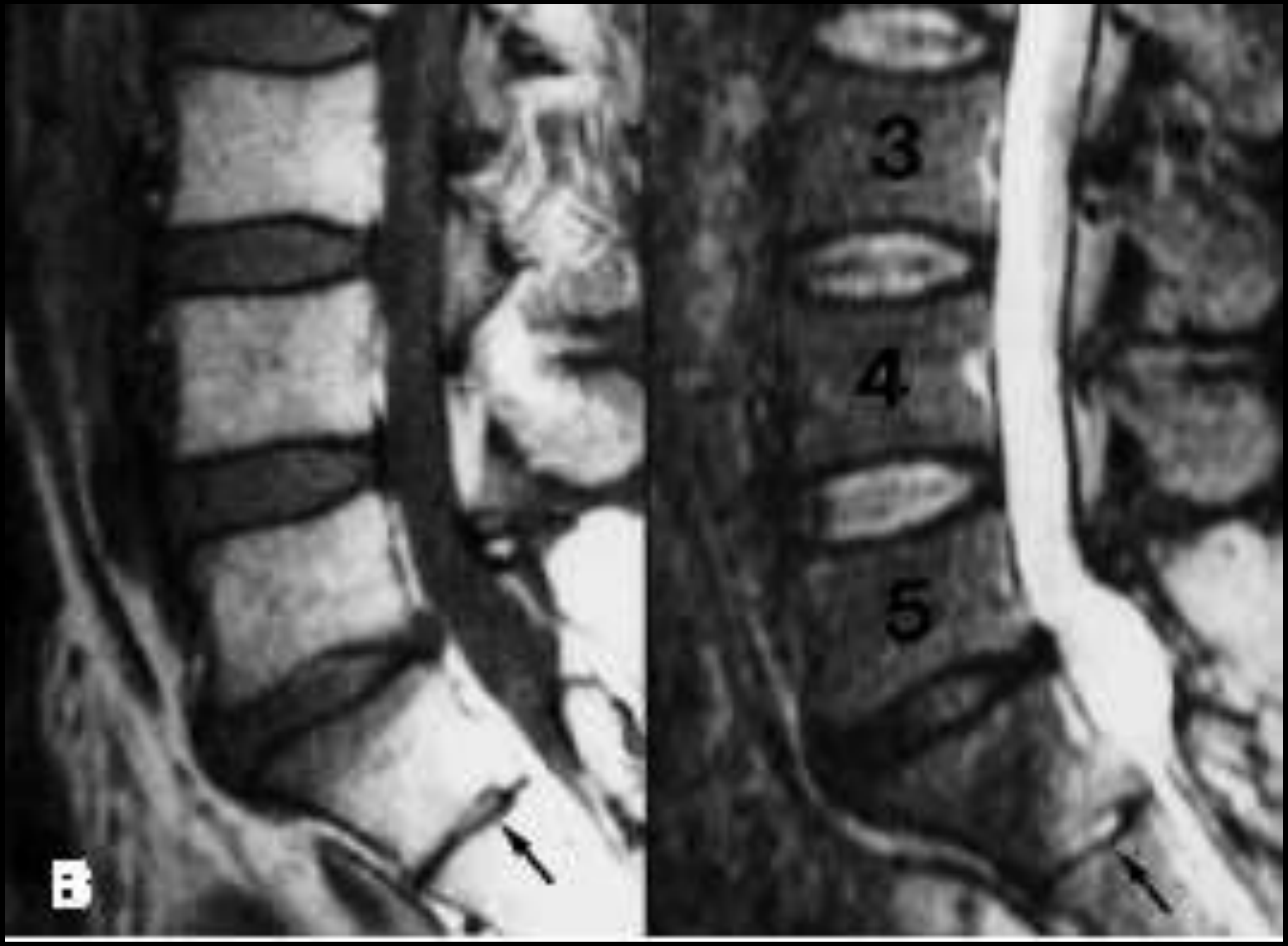

Type 3

Type 4

LSTV and vertebral Numbering

Imaging classification systems for LSTV do not provide insight into accurate labeling information for the vertebral level

If a LSTV is present, this should be stated along with its characterization including where the lowest, well-formed intervertebral disc is. This landmark can be identified at fluoroscopy during surgical or percutaneous procedures

Reported Landmarks for Vertebral Labeling from L-spine MRI

Spinal cord

– conus medullaris

Lee CH, Seo BK, Choi YC, Shin HJ, Park JH, Jeon HJ, Kim KA, Park CM, Kim BH. Using MRI to evaluate anatomic significance of aortic bifurcation, right renal artery, and conus medullaris when locating lumbar vertebral segments. AJR Am J Roentgenol. 2004 May;182(5):1295-1300.

Musculoskeletal

– iliolumbar ligament (ILL)

Hughes RJ, Saifuddin A. Numbering of lumbosacral transitional vertebrae on MRI: role of the iliolumbar ligaments. AJR 2006;187(1):W59-65.

Vascular

– aortic bifurcation
– right renal artery
– inferior vena cava confluence
– celiac trunk
– superior mesenteric artery root

Chithriki M, Jaibaji M, Steele RD. The anatomical relationship of the aortic bifurcation to the lumbar vertebrae: a MRI study. Surg Radiol Anat. 2002 Dec;24(5):308-312.

Lee CH, Park CM, Kim KA, Hong SJ, Seol HY, Kim BH, Kim JH. Identification and prediction of transitional vertebrae on imaging studies: anatomical significance of paraspinal structures. Clin Anat. 2007 Nov;20(8):905-14.

Reported Landmarks for Vertebral Labeling from L-spine MRI

Spinal cord

Vascular

(ILL)

Hughes RJ, Saifuddin A. Numbering of lumbosacral transitional vertebrae on MRI: role of the iliolumbar ligaments. AJR 2006;187(1):W59-65.

Radiol Anat. 2002 Dec;24(5):308-312.

Lee CH, Park CM, Kim KA, Hong SJ, Seol HY, Kim BH, Kim JH. Identification and prediction of transitional vertebrae on imaging studies: anatomical significance of paraspinal structures. Clin Anat. 2007 Nov;20(8):905-14.

Clinical Relevance

Substantial variability of spine segmental anatomy may confound spine imaging interpretation

Hindrance in ascribing correct vertebral levels

Deviation from the typical total and segmental distribution is not infrequent and transitional situations are common

Knowing the prevalence will provide better insight to clinicians

Courtesy of Tim Maus, M.D.

71 M Right leg pain

Courtesy of Tim Maus, M.D.

71 M Right leg pain

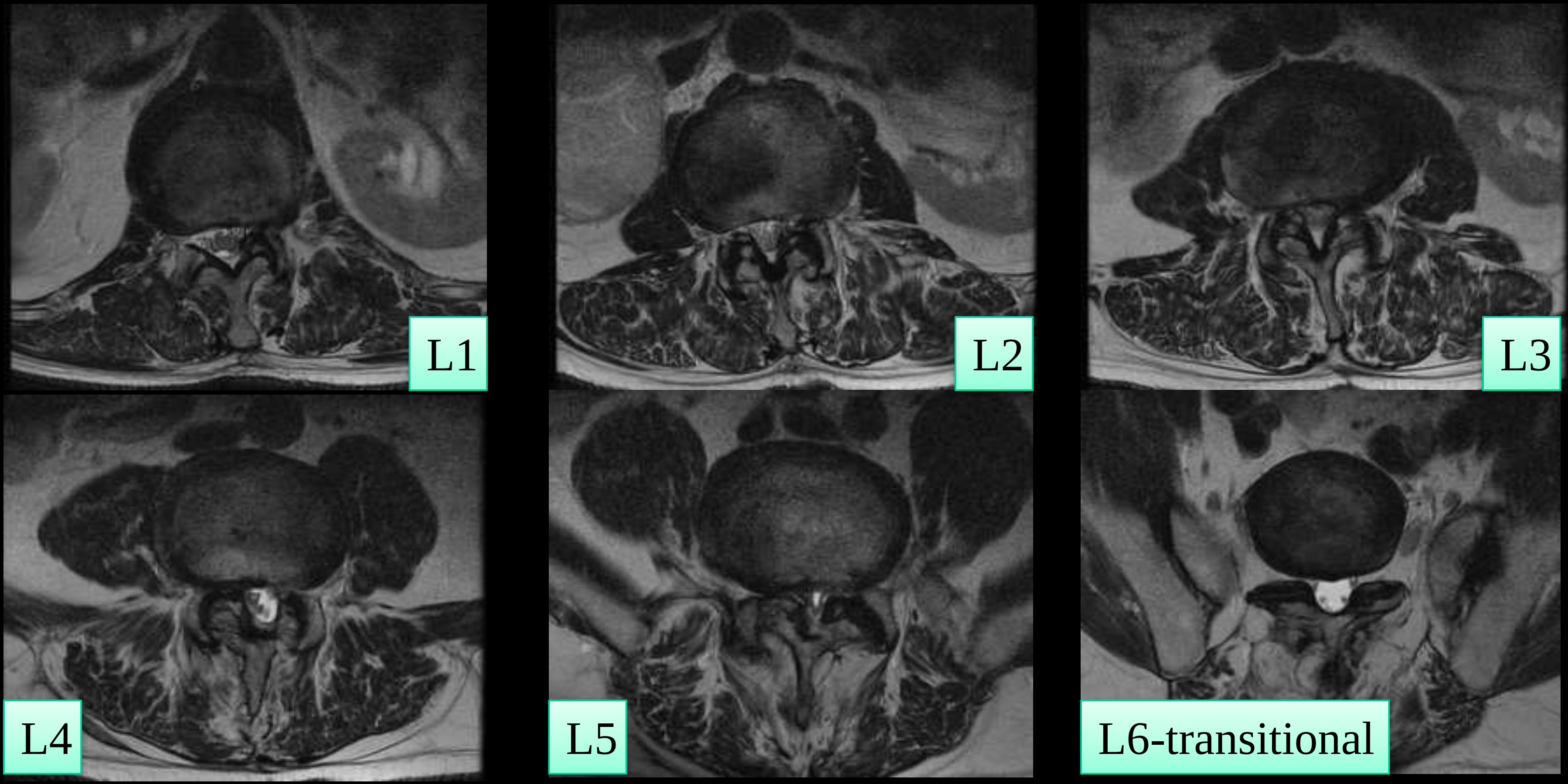

Courtesy of Tim Maus, M.D.

71 M Right leg pain

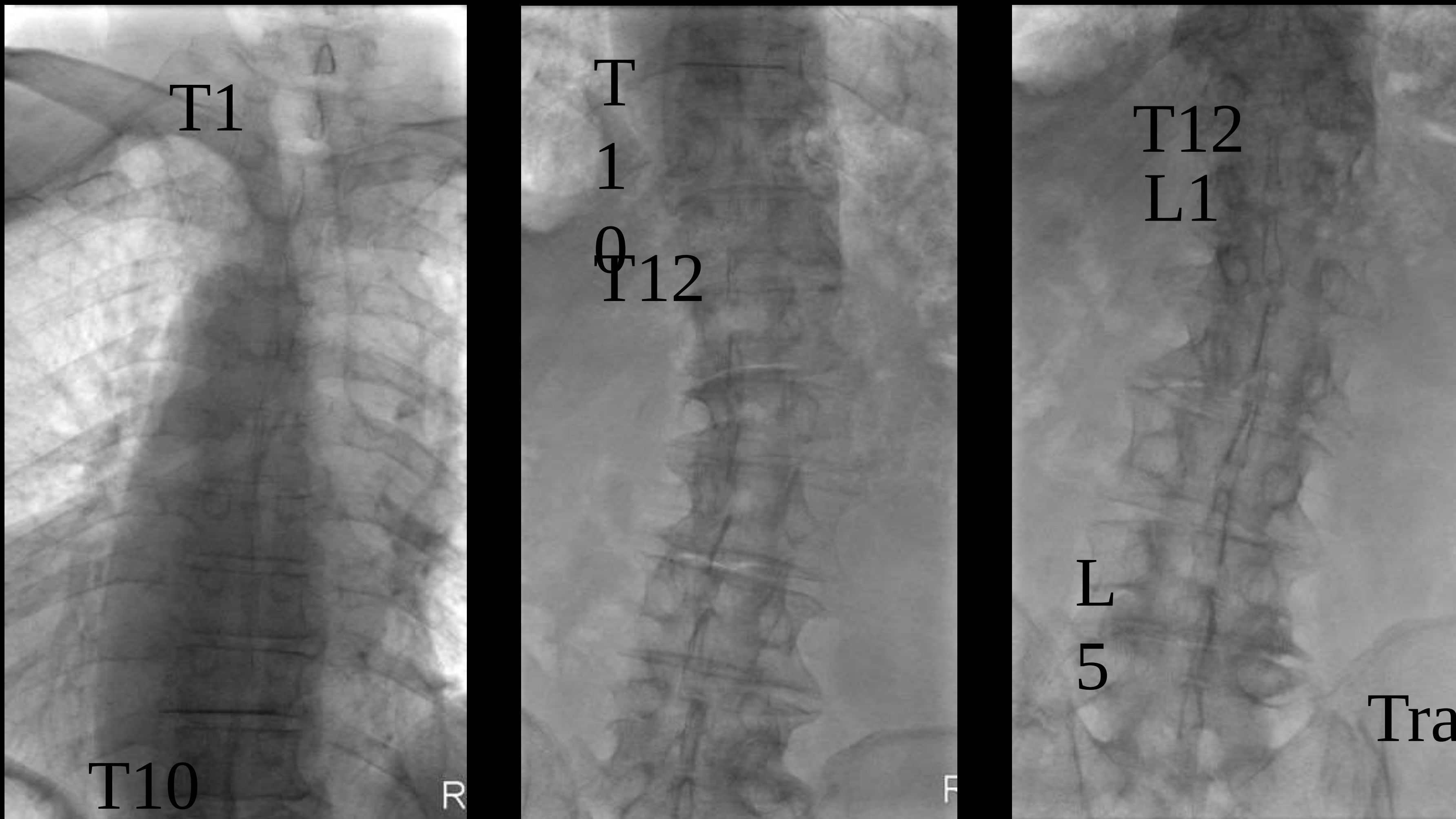

12 Thoracic rib-bearing vertebrae, 5 lumbar vertebrae above a transitional segment
The 25th segmental nerve, classically supplying the S1 radicular distribution, exits under the transitional segment pedicle

Courtesy of Tim Maus, M.D.

71 M Right leg pain

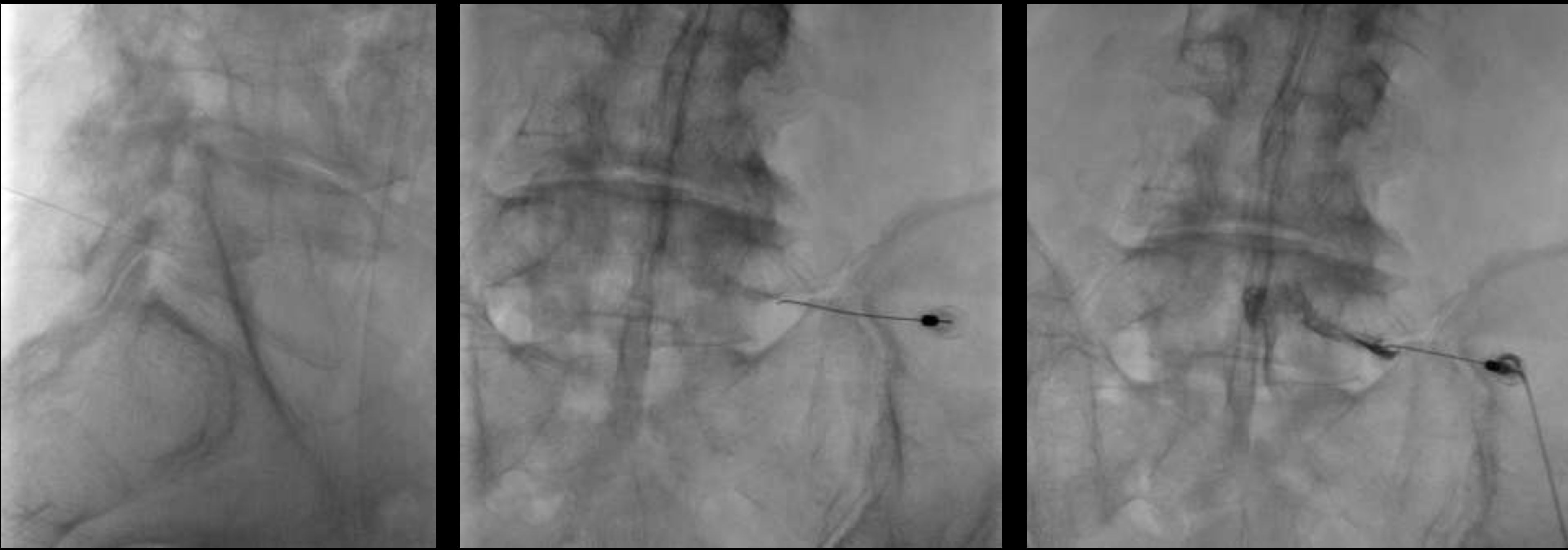

A safe triangle supra-neural TFE was performed, targeting the nerve exiting under the transitional segment pedicle, which is compressed in the lateral recess – he left the department pain free

Courtesy of Tim Maus, M.D.

43 F, left leg pain

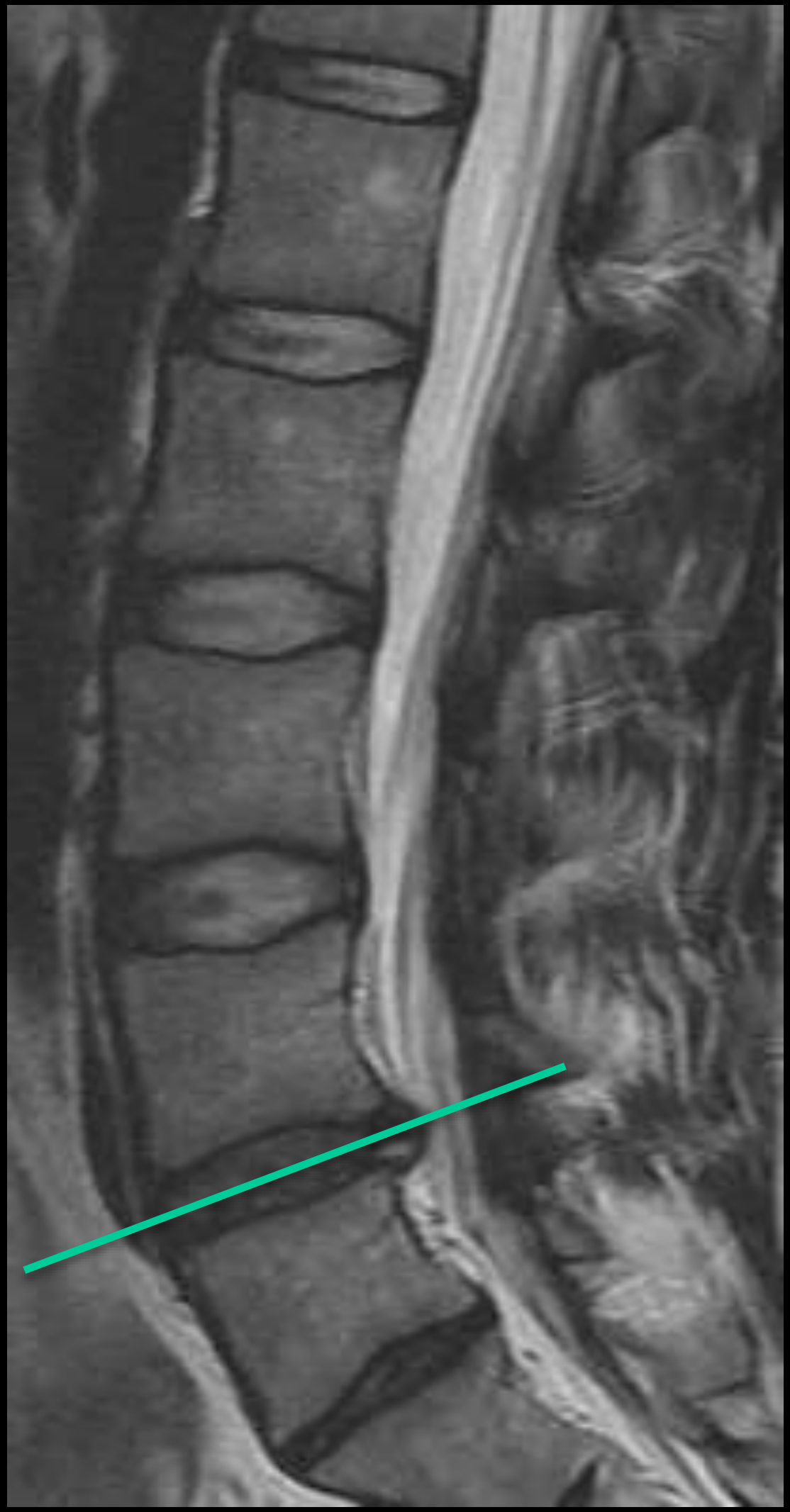

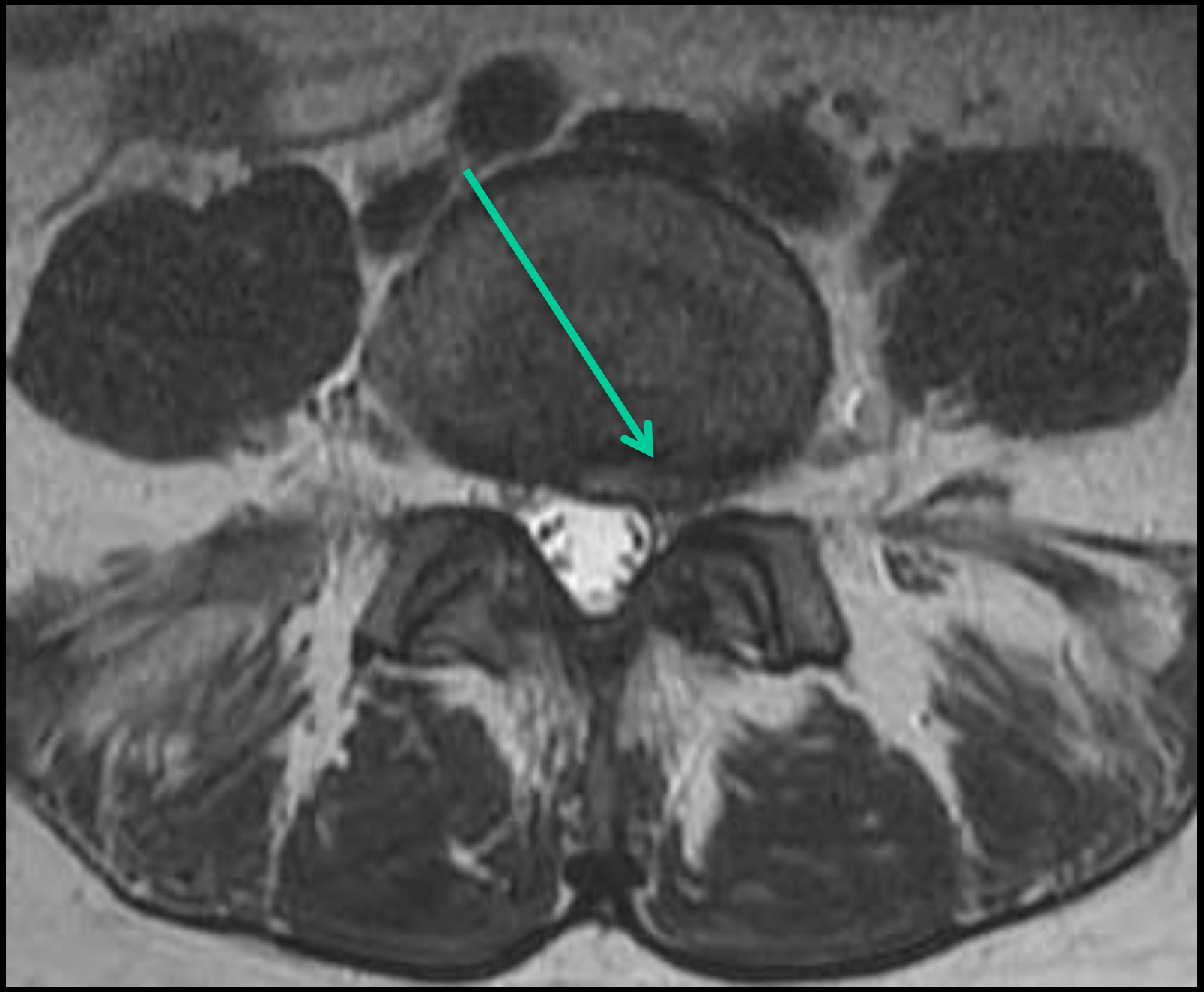

Courtesy of Tim Maus, M.D.

43 F, left leg pain

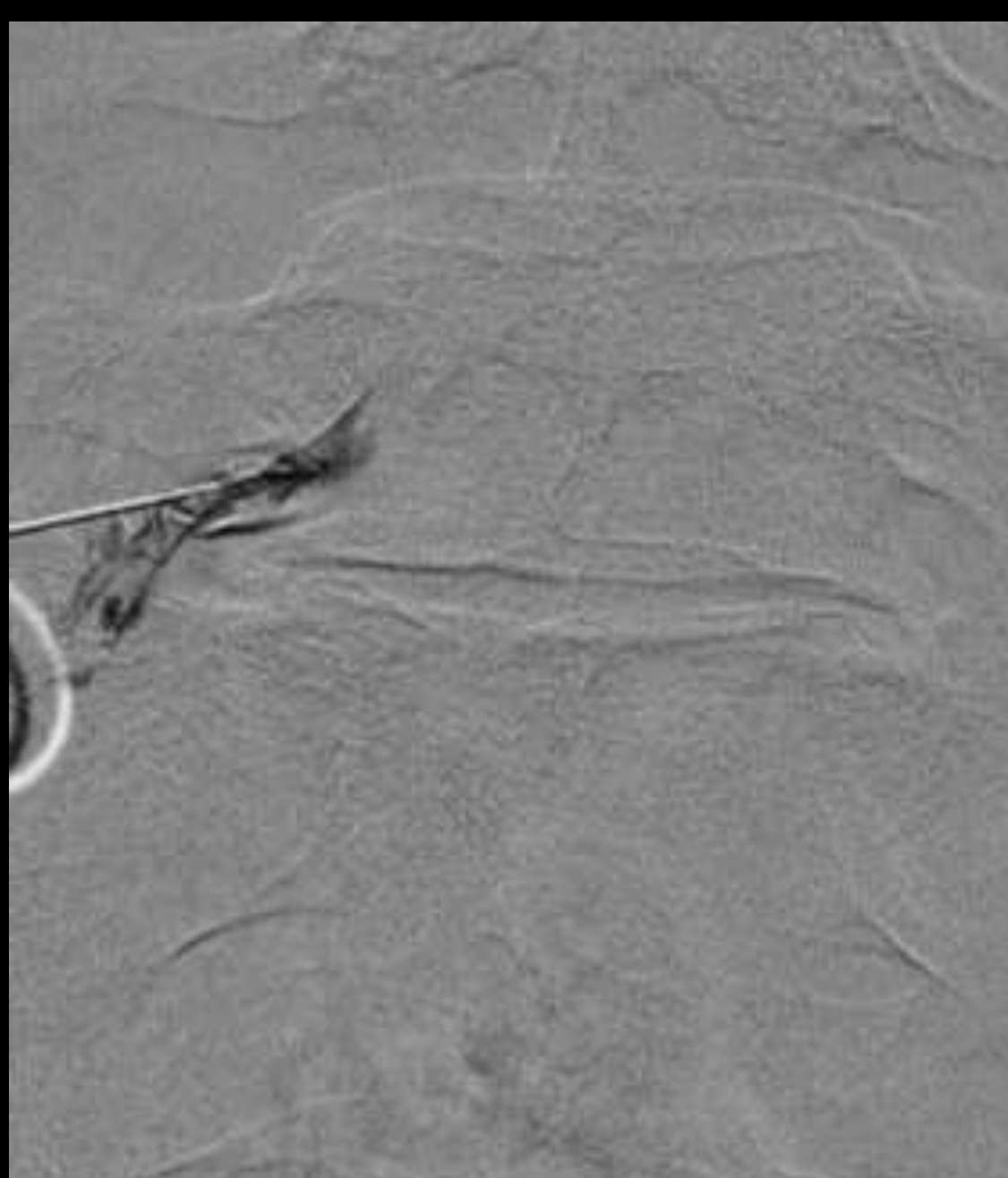

Courtesy of Tim Maus, M.D.

27 M, Left Leg Pain

-

-

27 M, Left Leg Pain

Courtesy of Tim Maus, M.D.

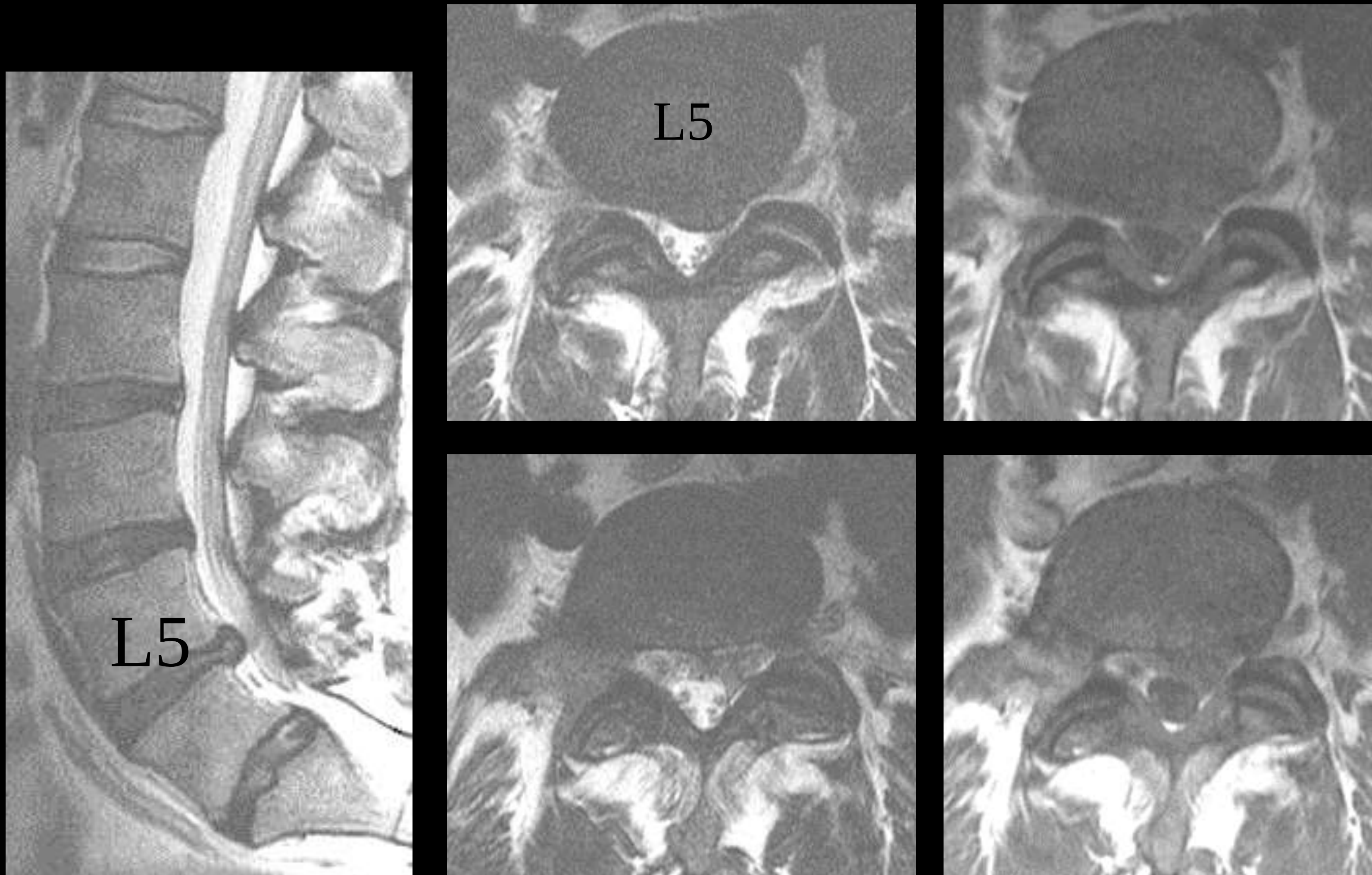

Courtesy of Tim Maus, M.D.

27 M, Left Leg Pain

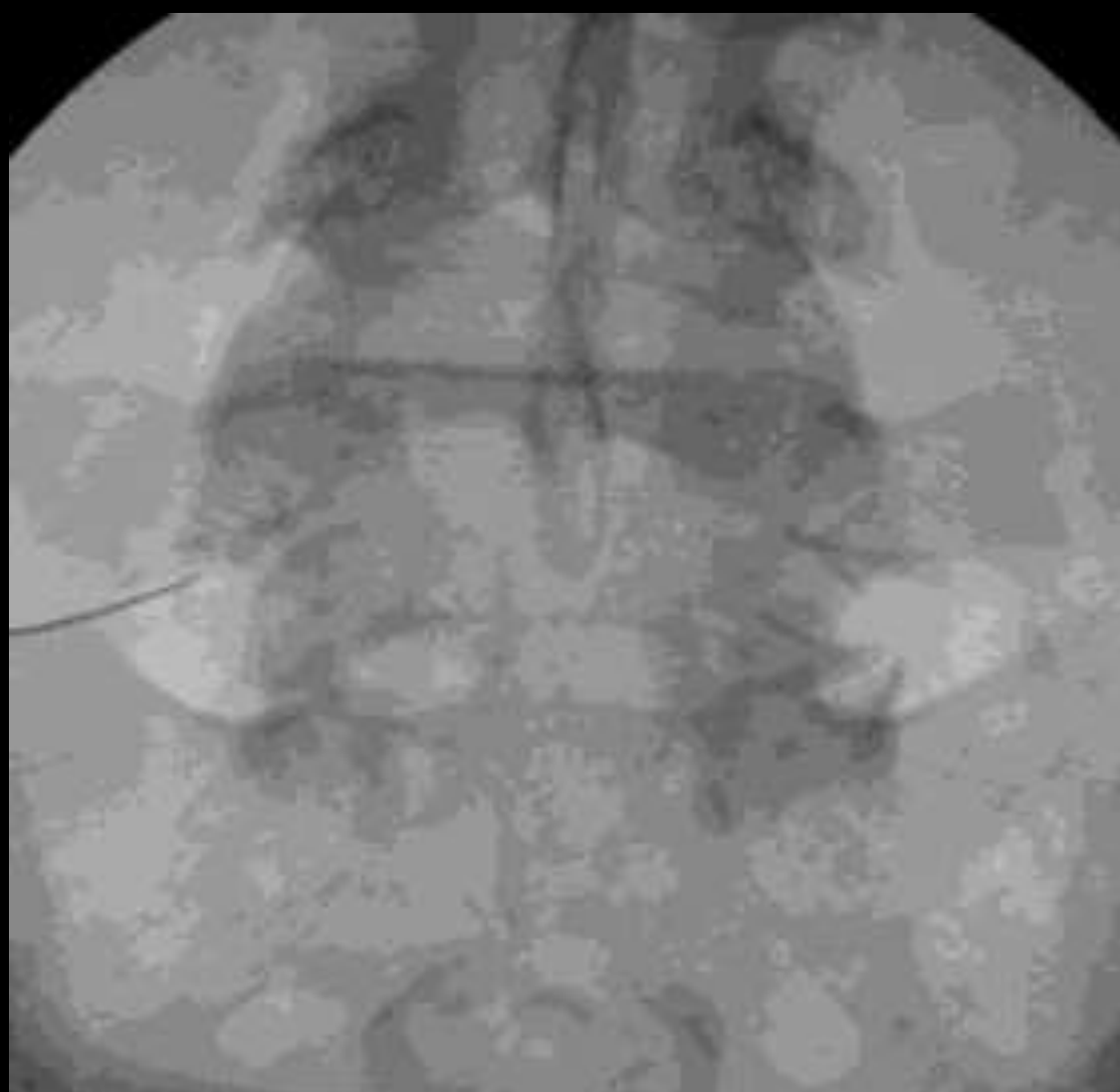

Courtesy of Tim Maus, M.D.

37, M   S1 Radicular Pai

- 37, Male
- Left buttock, posterior thigh, posterior calf pain
- Paresthesias on planter aspect of foot
- Contrary to imaging recommendations, plain films were not obtained
- MRI shows ?
- How can this be resolved with the patient’s pain pattern?
- Where should an injection be performed ?

37, M S1 Radicular Pain

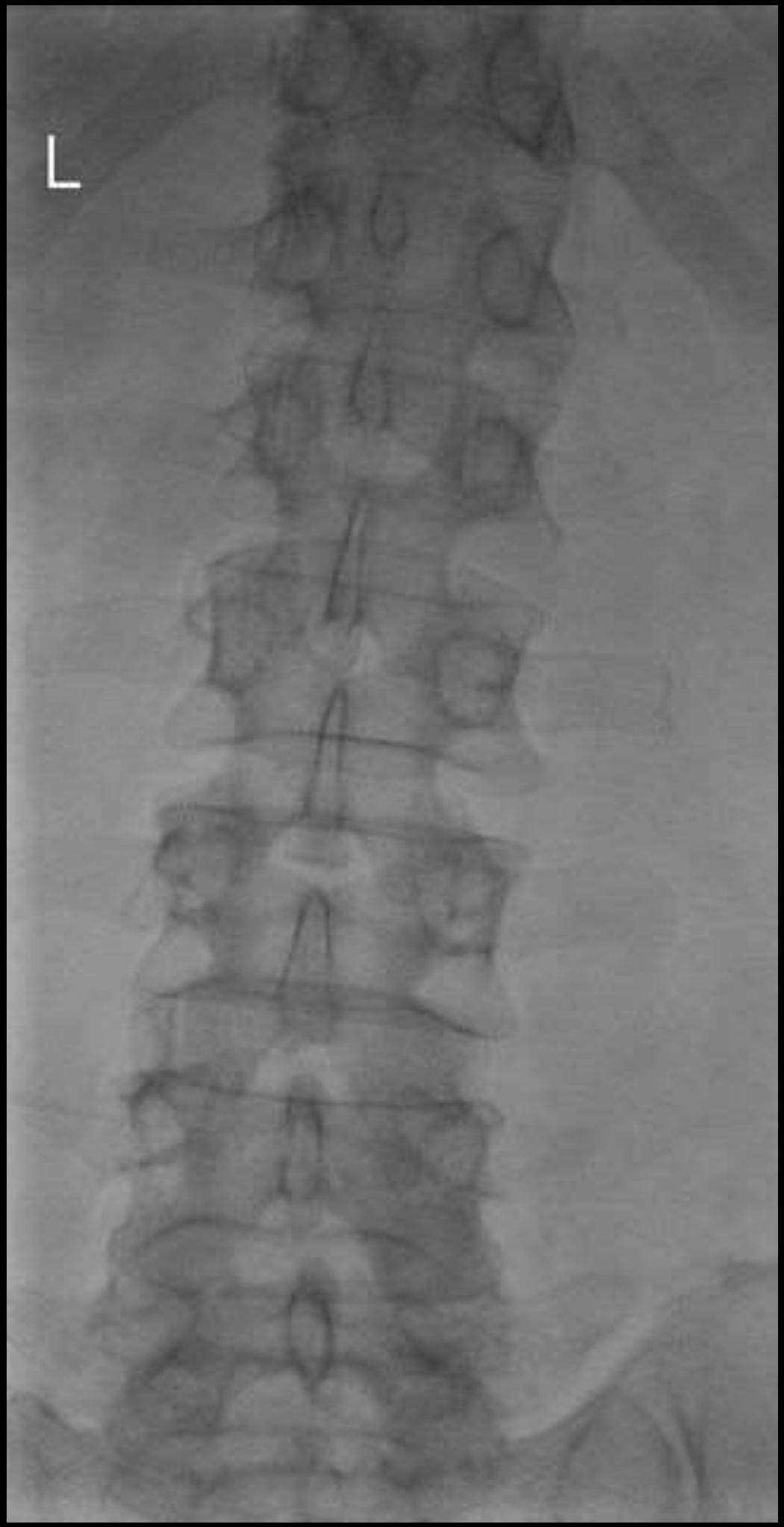

- MRI scout view:
  - 25 vertebral segments
- Fluoro observation:
  - 7 cervical
  - 12 rib bearing thoracic
  - 6 lumbar
- Neural elements do not change
- Bony structures may change about them
- Here the S1 radicular distribution is innervated by the nerve exiting under the L6 / transitional segment pedicle

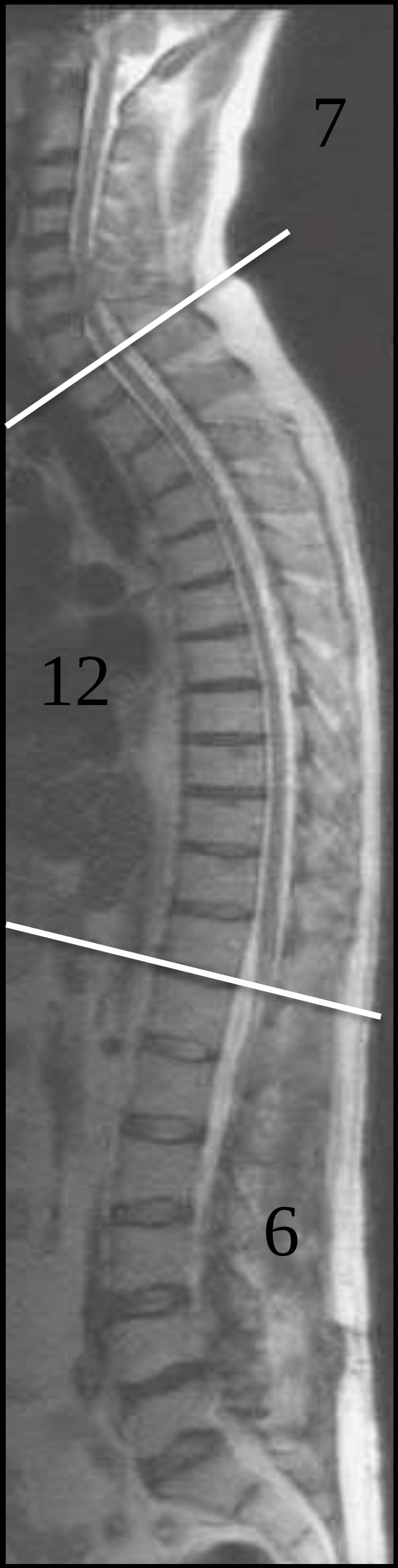

Courtesy of Tim Maus, M.D.

37, M   S1 Radicular Pain

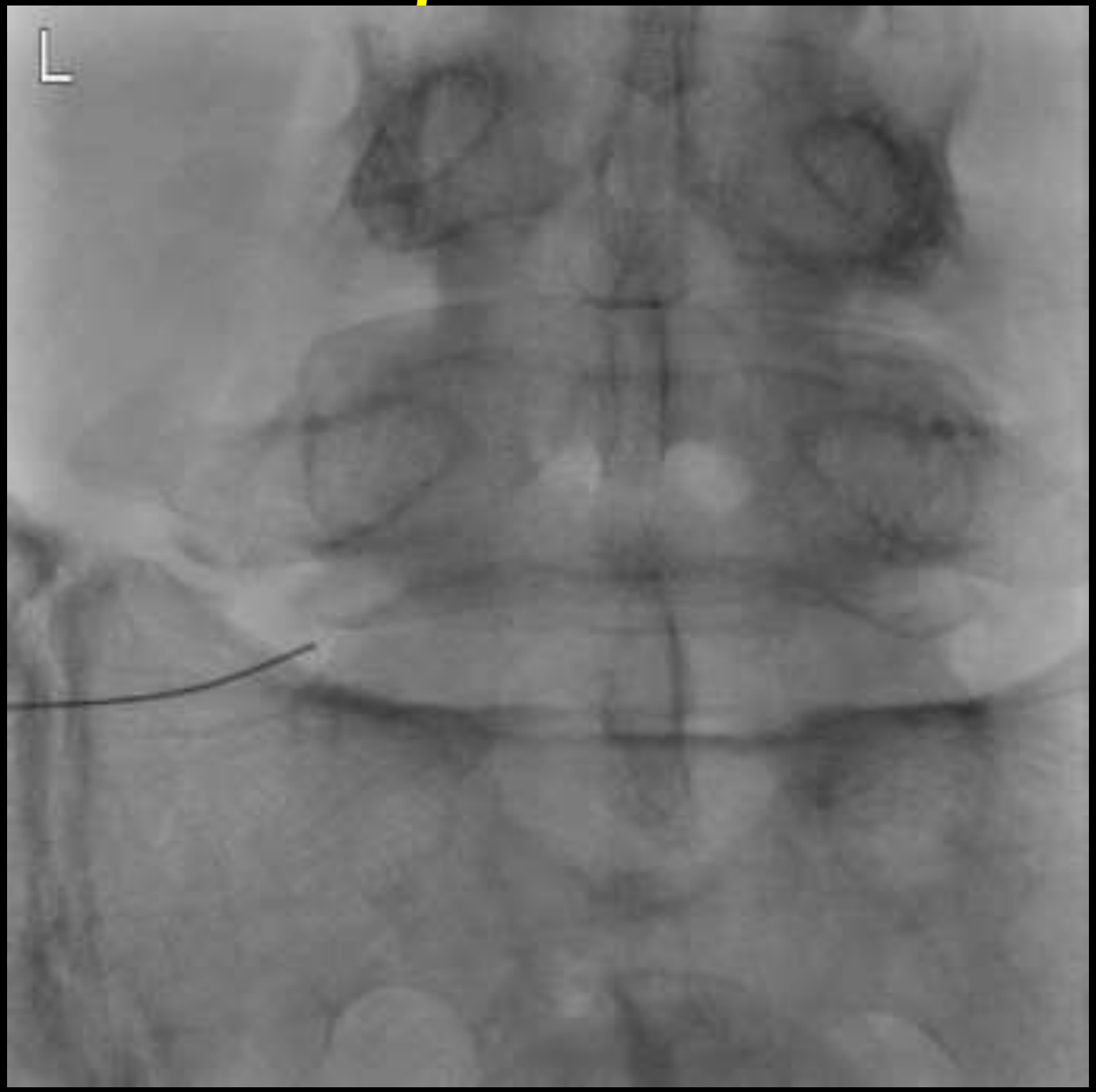

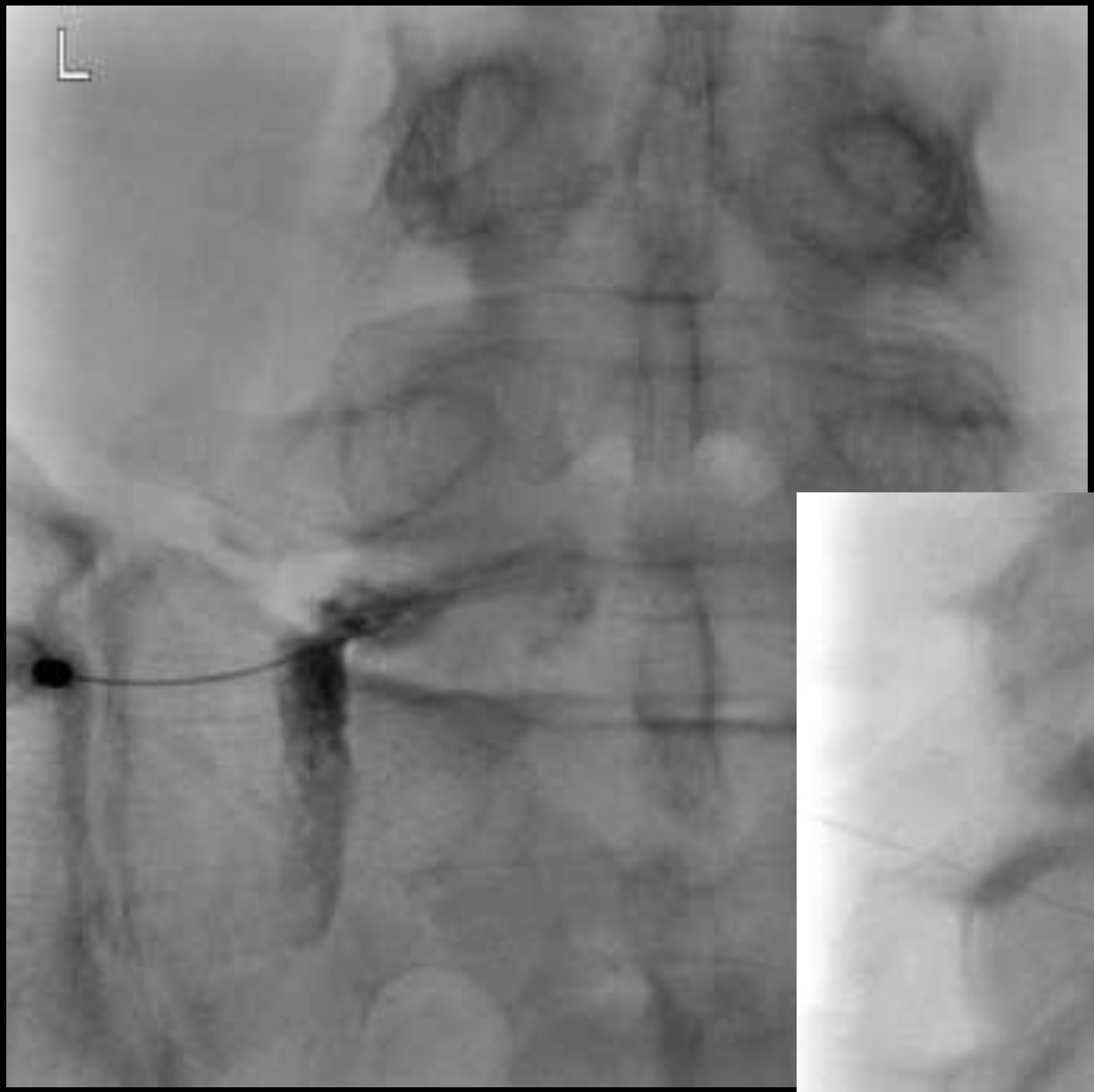

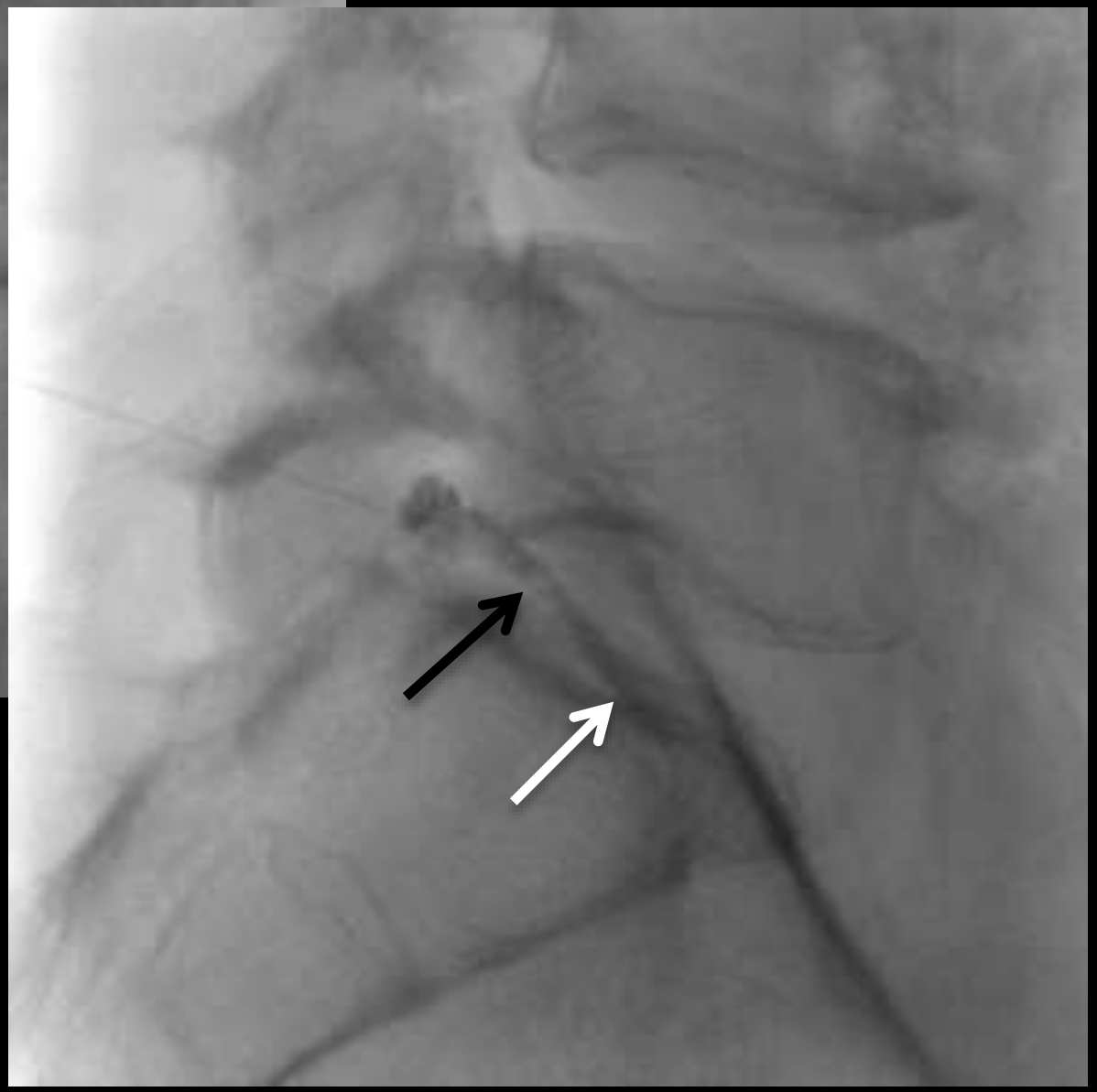

-

-

Courtesy of Tim Maus, M.D.

65, F Right Leg Pain

-
-
-

6 lumbar vertebrae

Courtesy of Tim Maus, M.D.

65, F Right Leg Pain

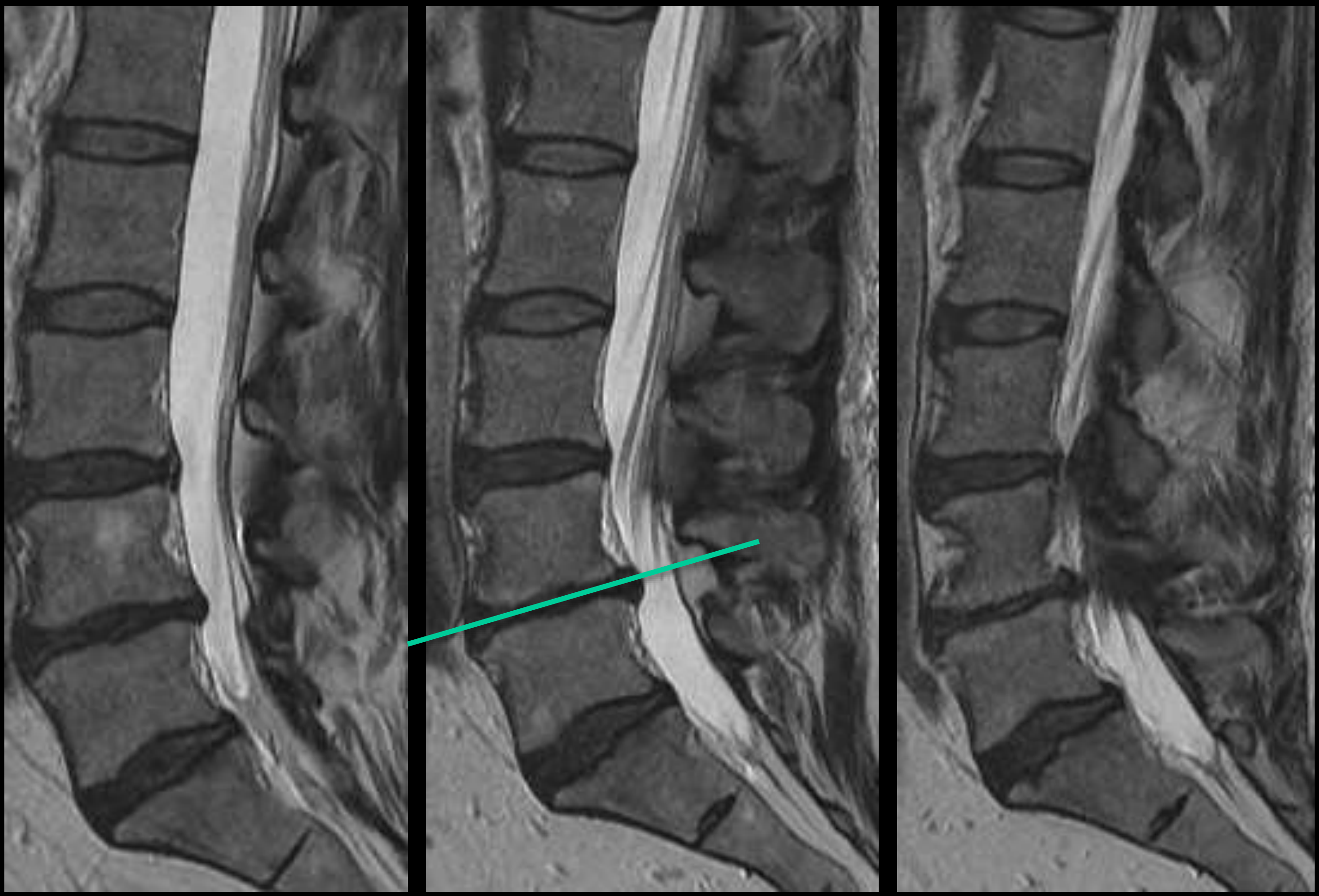

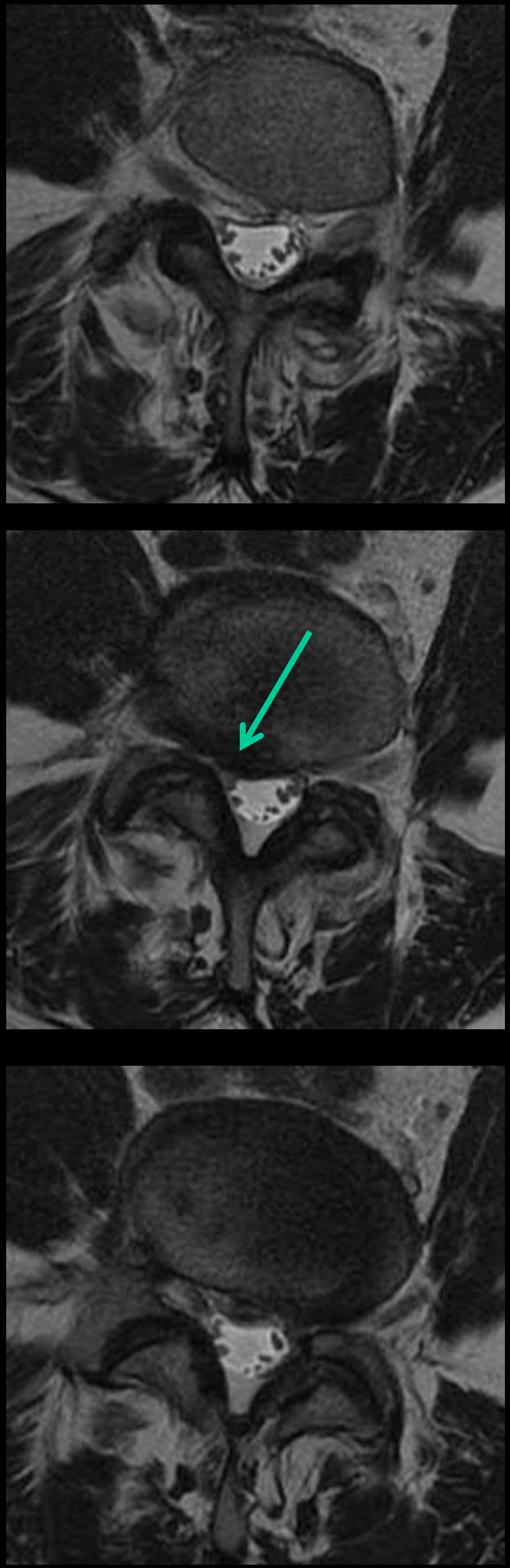

•

•

5, F Right Leg Pain

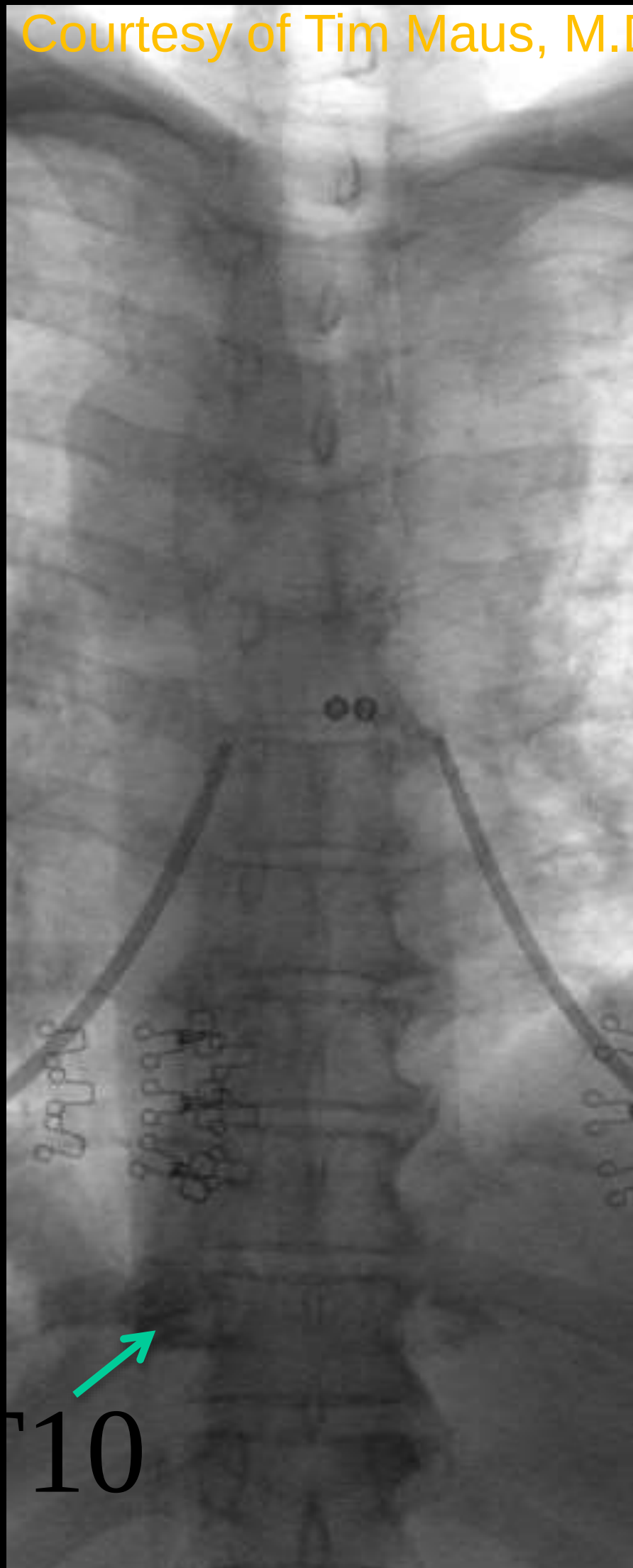

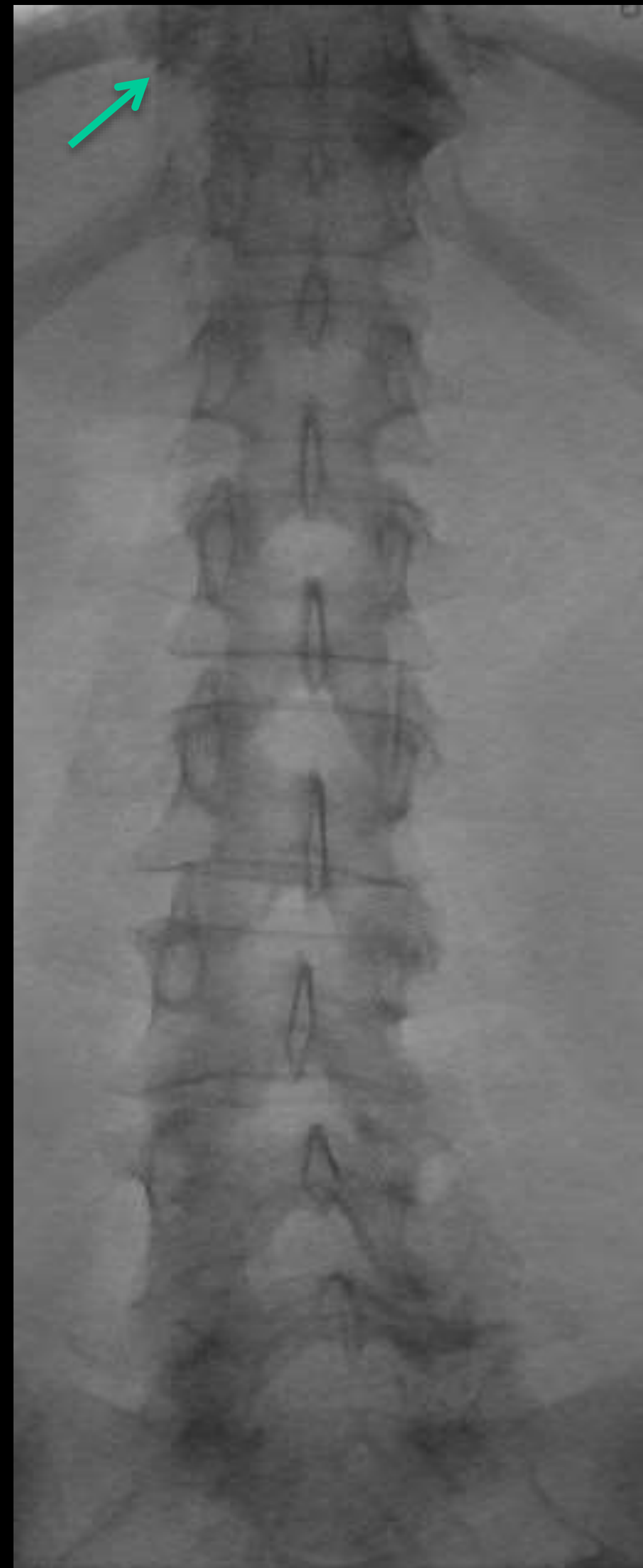

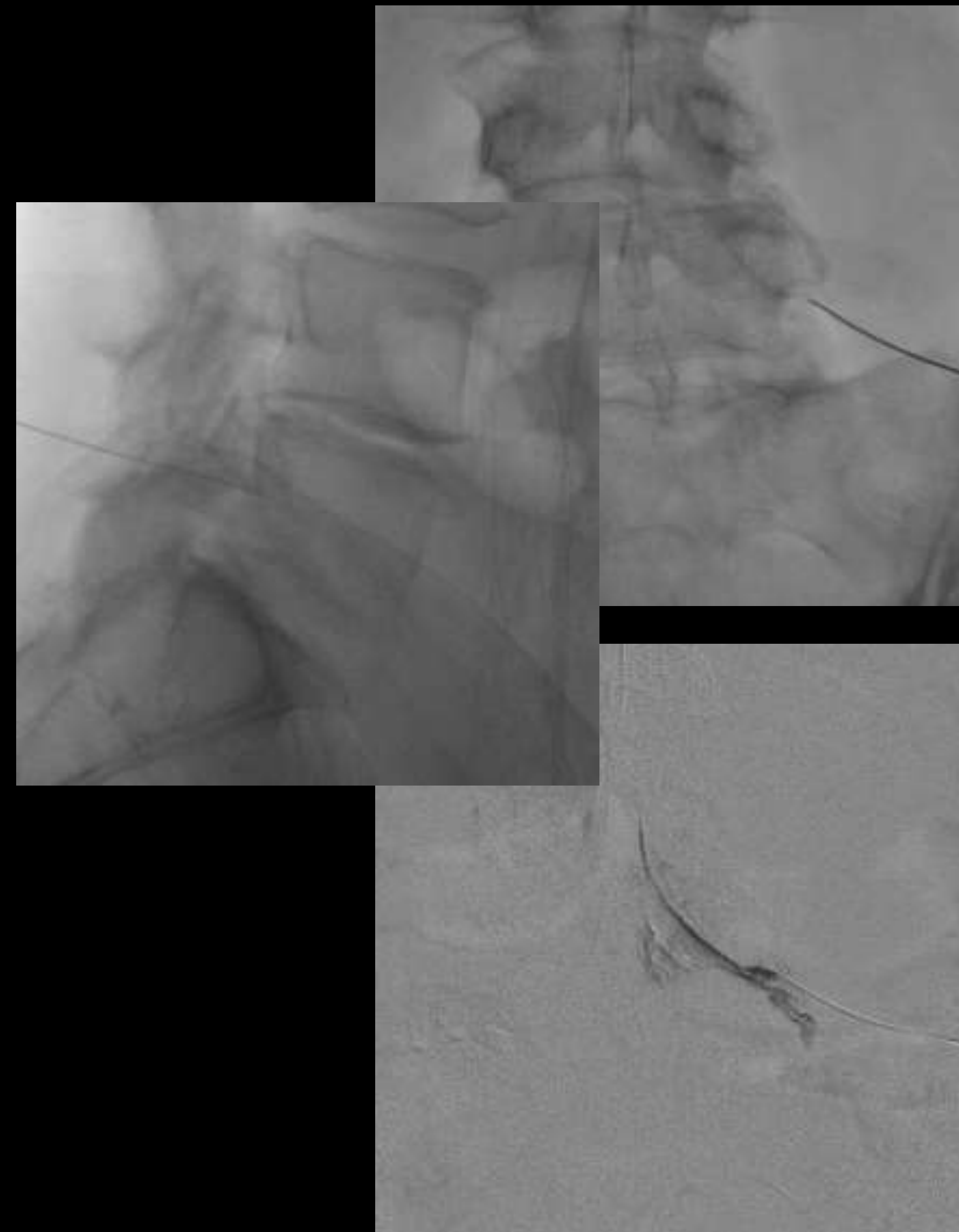

Courtesy of Tim Maus, M.D.

65, F Right Leg Pain



Courtesy of Tim Maus, M.D.

71, F   Right Hip Pain

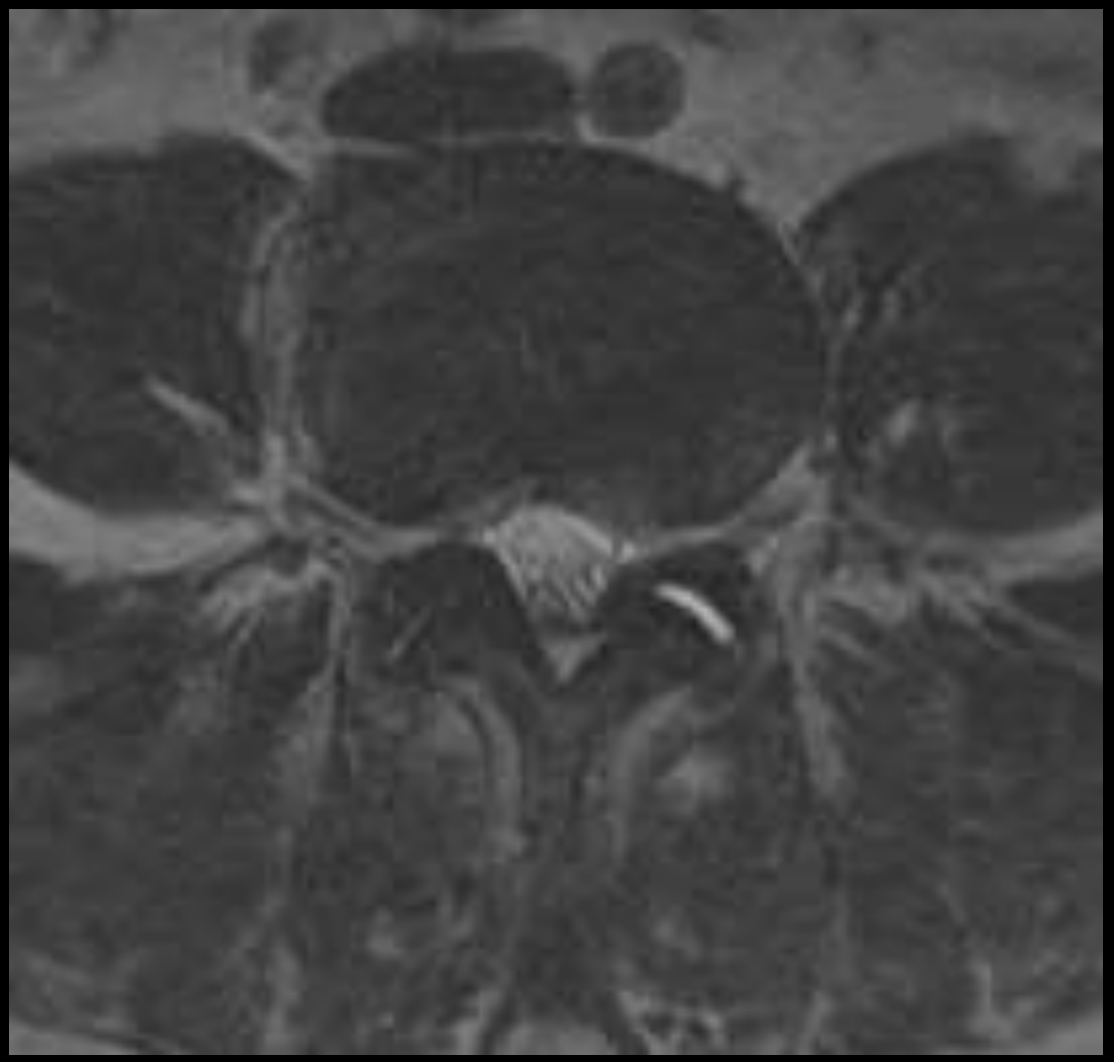

Courtesy of Tim Maus, M.D.

71, F Right Hip Pain

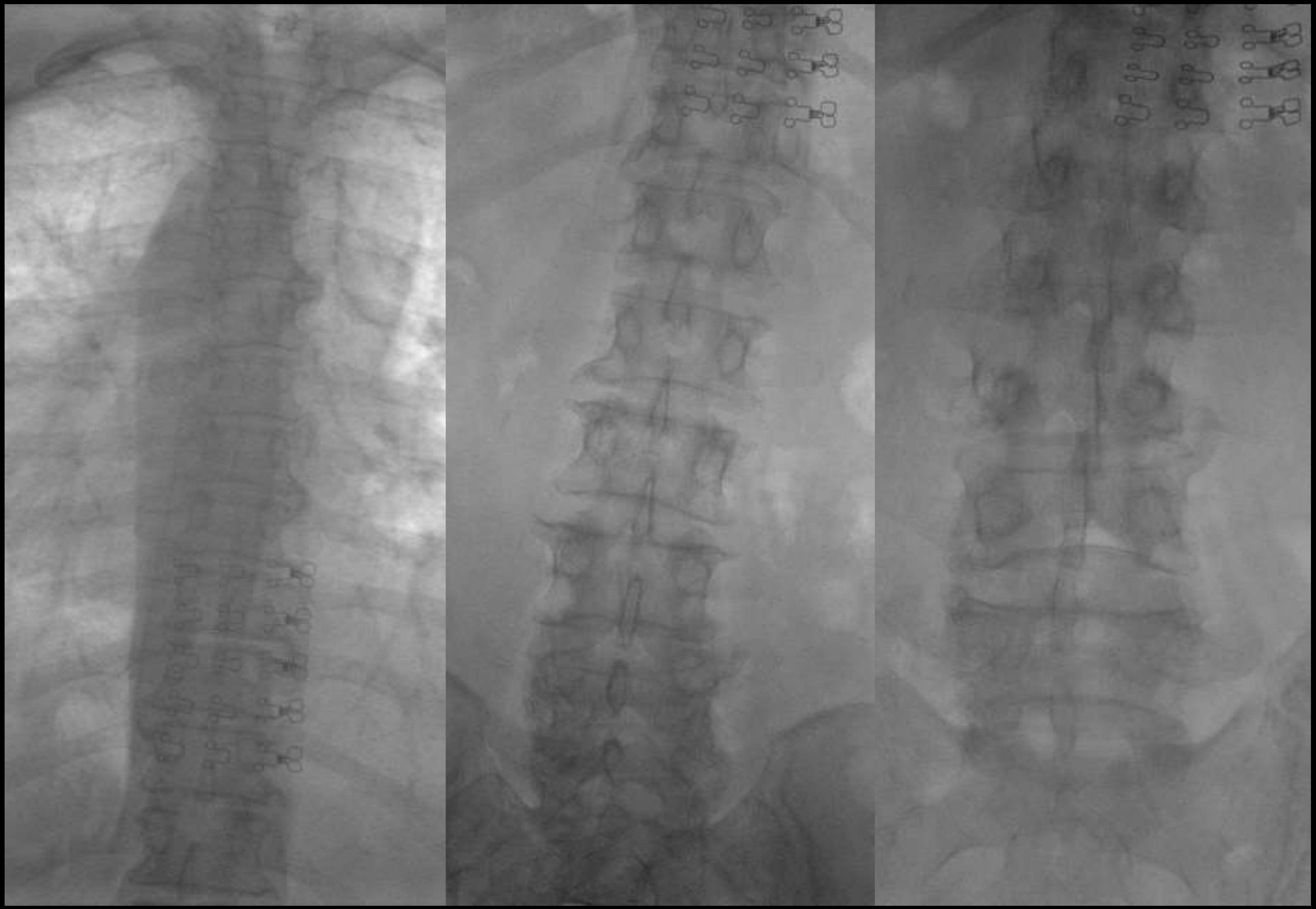

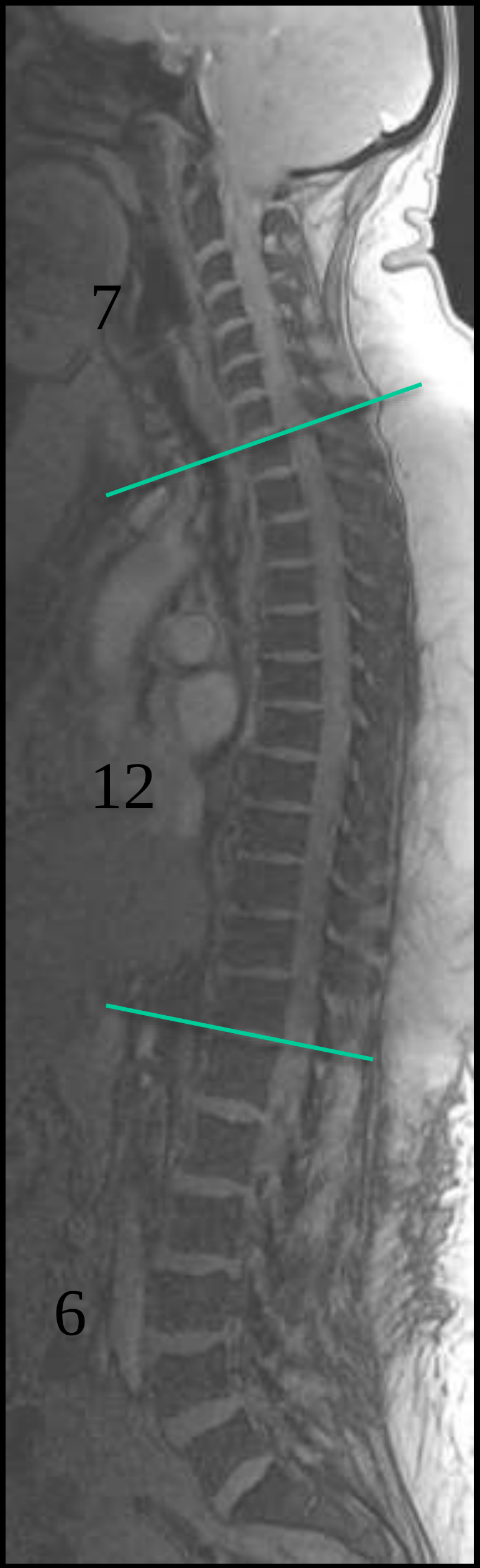

-
-

Courtesy of Tim Maus, M.D.

71, F Right Hip Pain

Schemes of Numbering Lumbar Vertebrae

Count from top using whole spine localizer

Use lumbosacral angle to discern transition point

Identify iliolumbar ligament arising from last lumbar vertebrae

IlioLumbar Ligament (ILL)

Summary

Because of phylogenetic variation the ILL does not always denote the level of L5 but rather simply identifies the lowest lumbar type vertebral segment.

LSTV are associated with anomalous number of presacral segments but TLTV are not

The presence of a TLTV is associated with a higher incidence of concomitant LSTV, and vice versa

Carrino et al. The Effect of Spinal Segment Variants on Numbering Vertebral Levels Using Lumbar MRI. Radiology 2011.

Contents

Joints of upper C-spine

Atlanto-occipital joint: occipital condyles and lateral atlantal mass.

Lateral atlanto-axial joint (lateral masses of atlas and sup. articular surface of axis)

Median atlanto-axial joint (dens and anterior arch of atlas and transv. ligament.

Joints of Upper Cervical Spine

- Atlanto-occipital joint: occipital condyles and lateral atlantal mass.
- Lateral atlanto-axial joint: lateral mass, atlas and articular pillar, axis
- Median atlanto-axial joint: dens and anterior arch of atlas, transverse ligament.

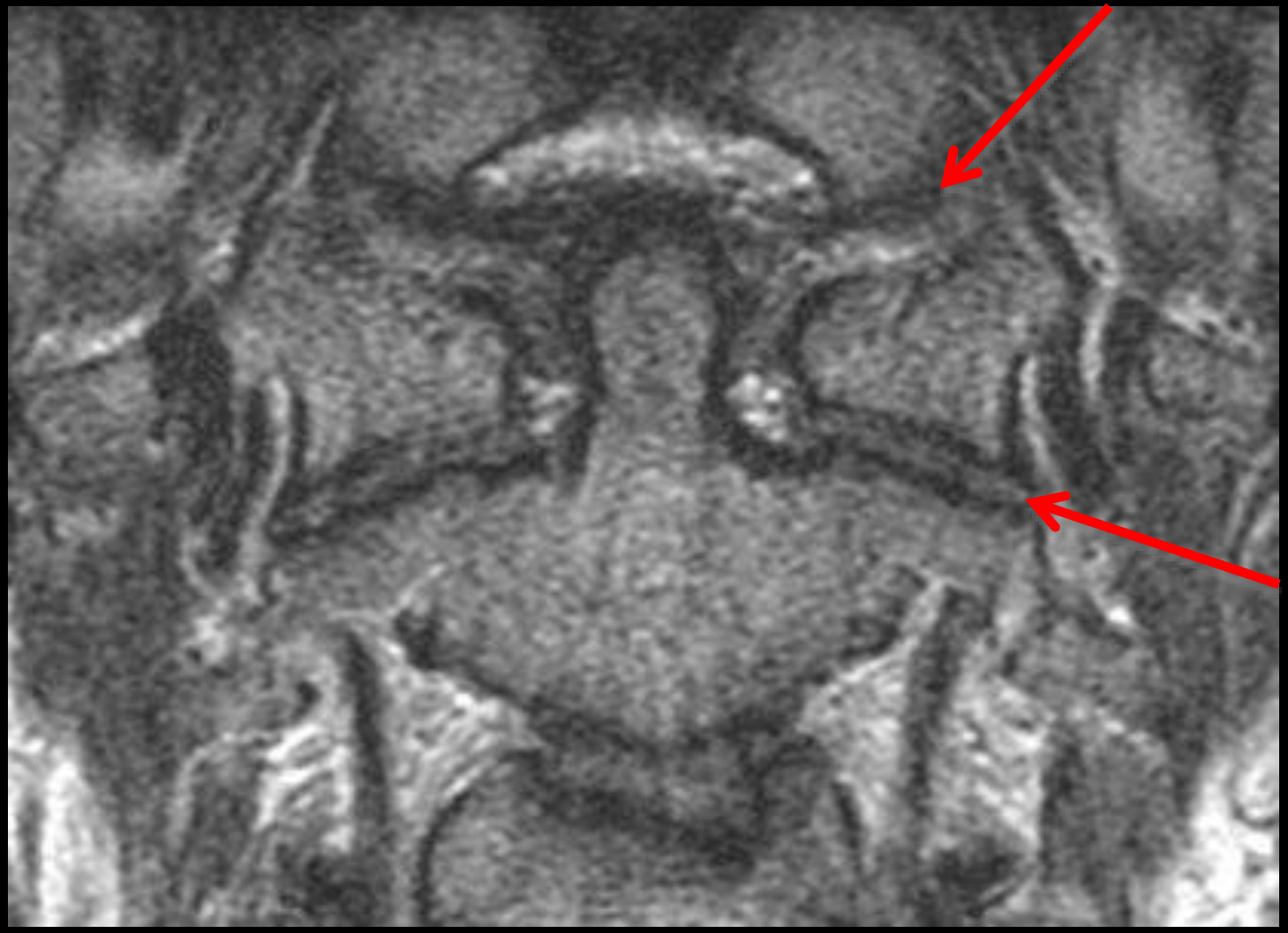




Joints of Upper Cervical Spine

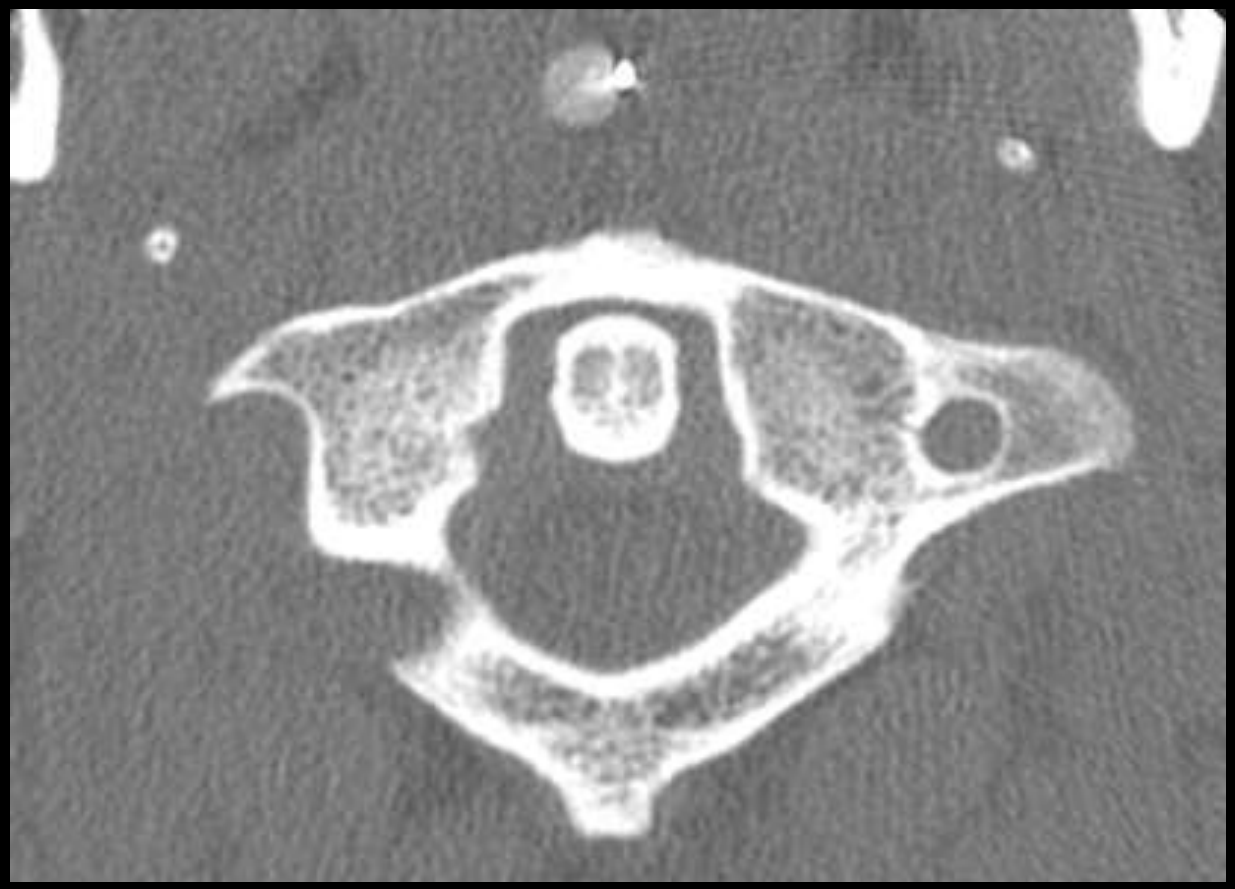

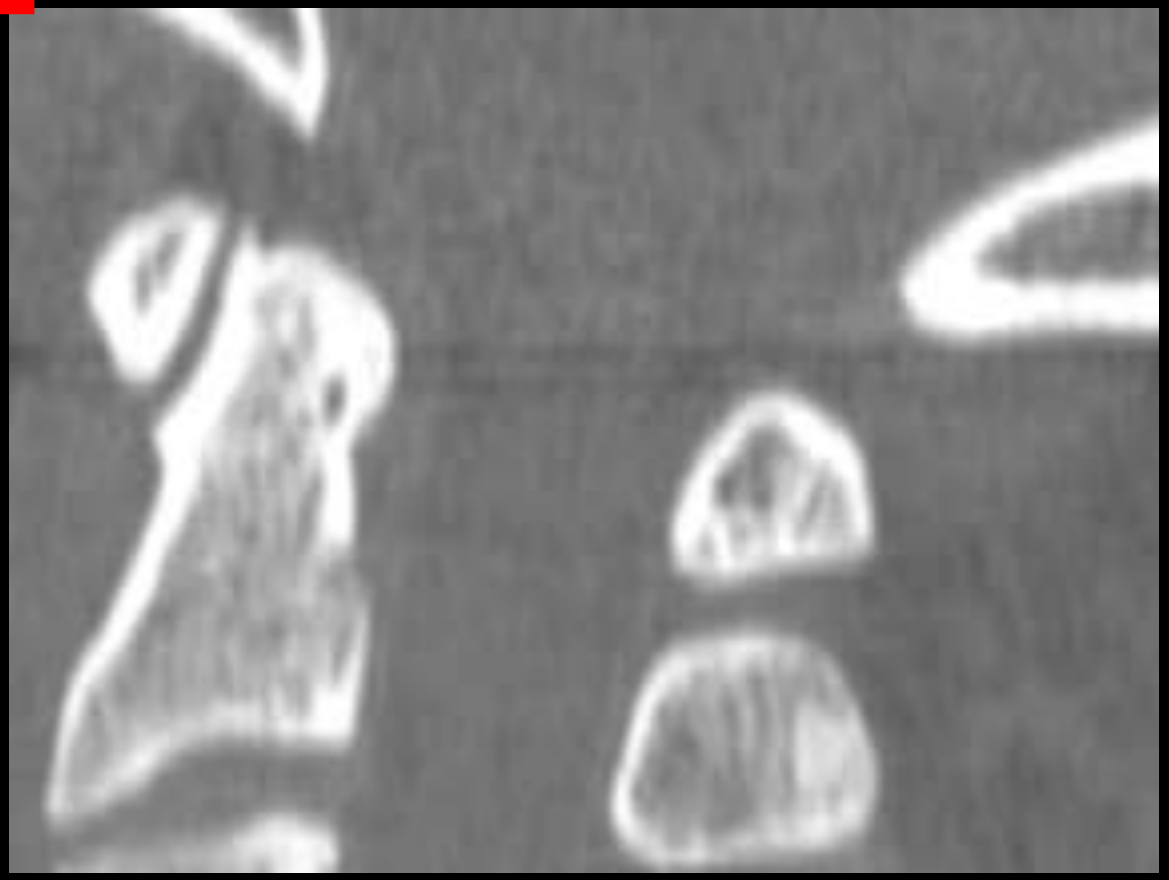

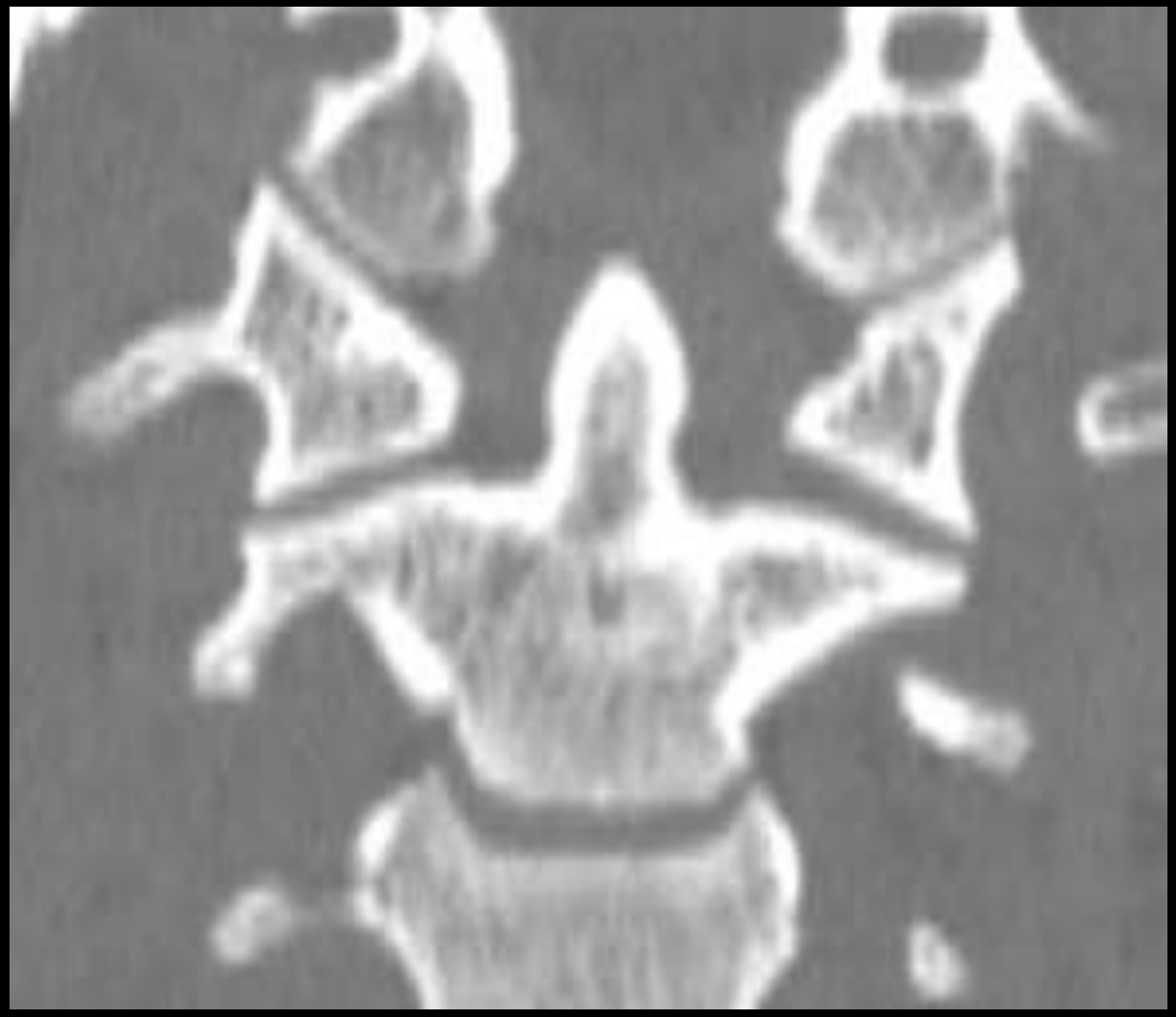

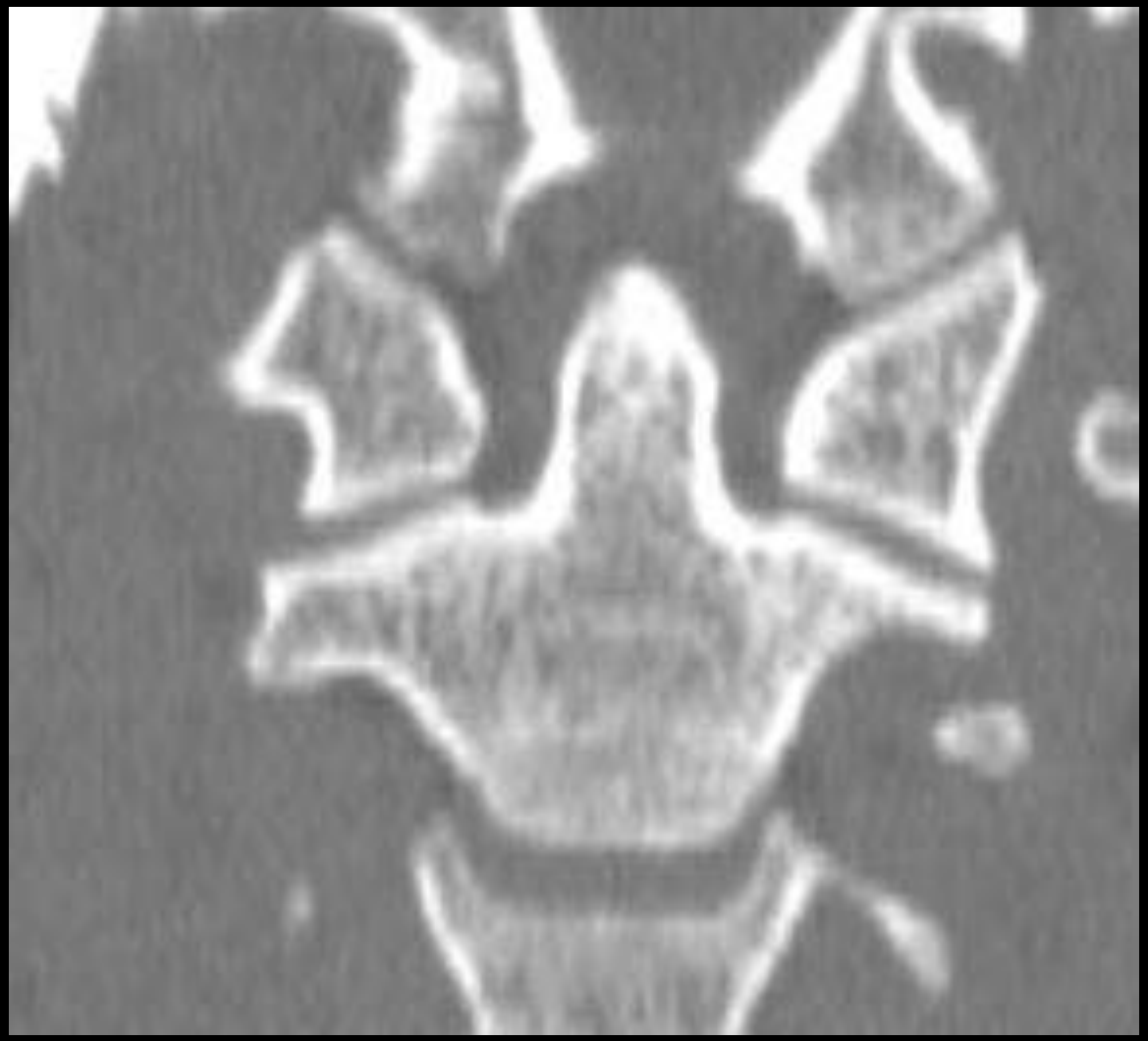

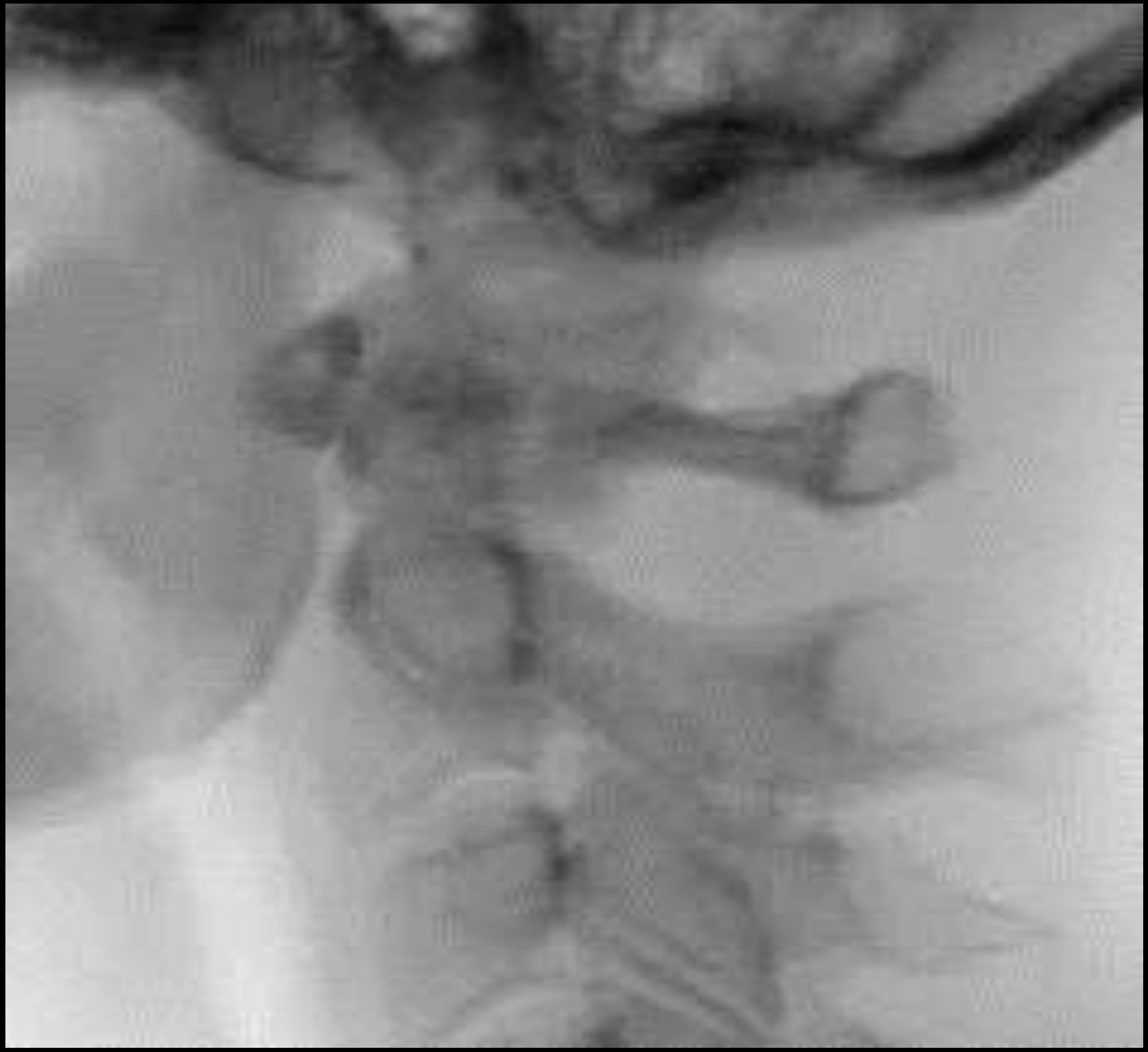

Lateral view upper cervical spine

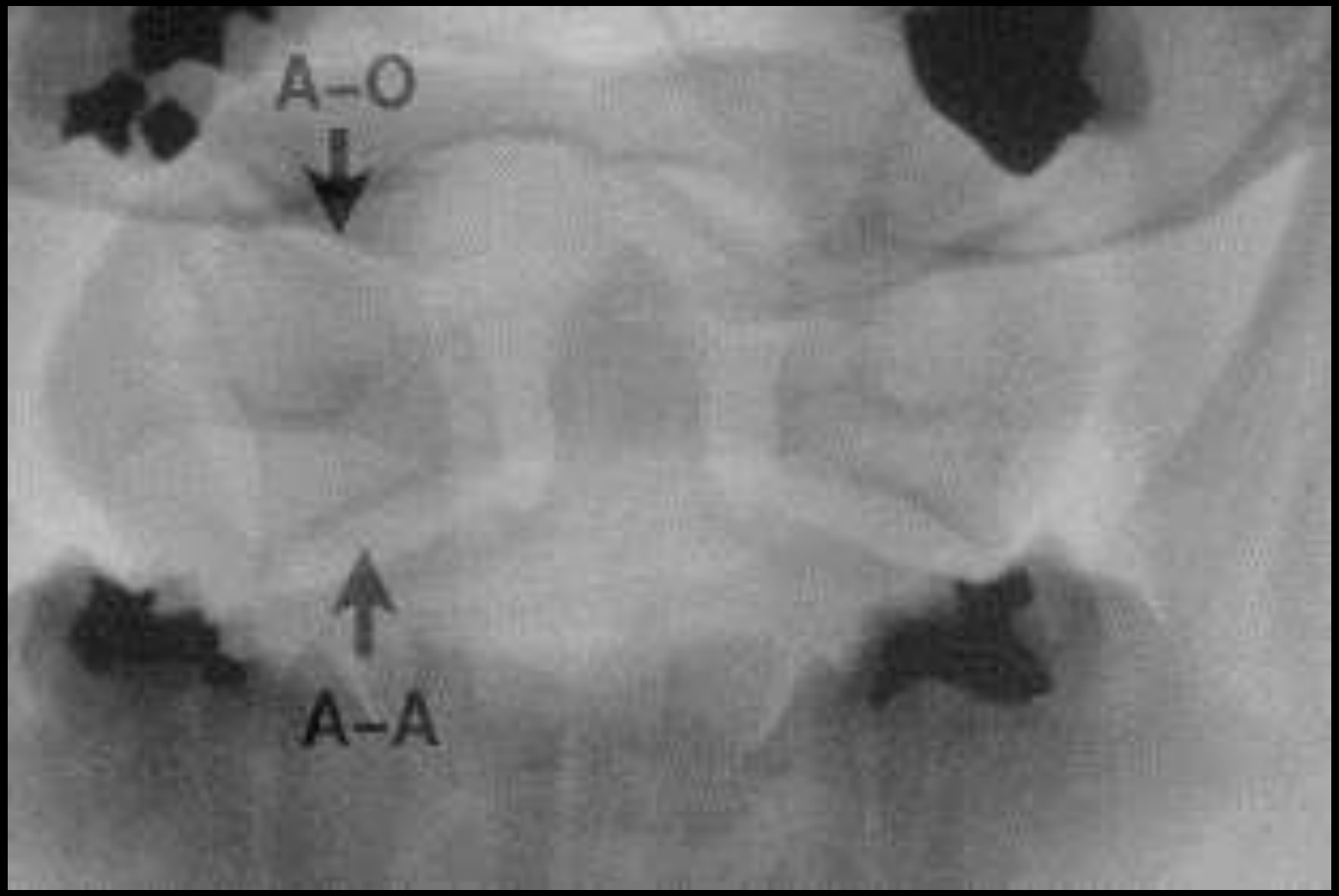

“Open mouth” Odontoid view

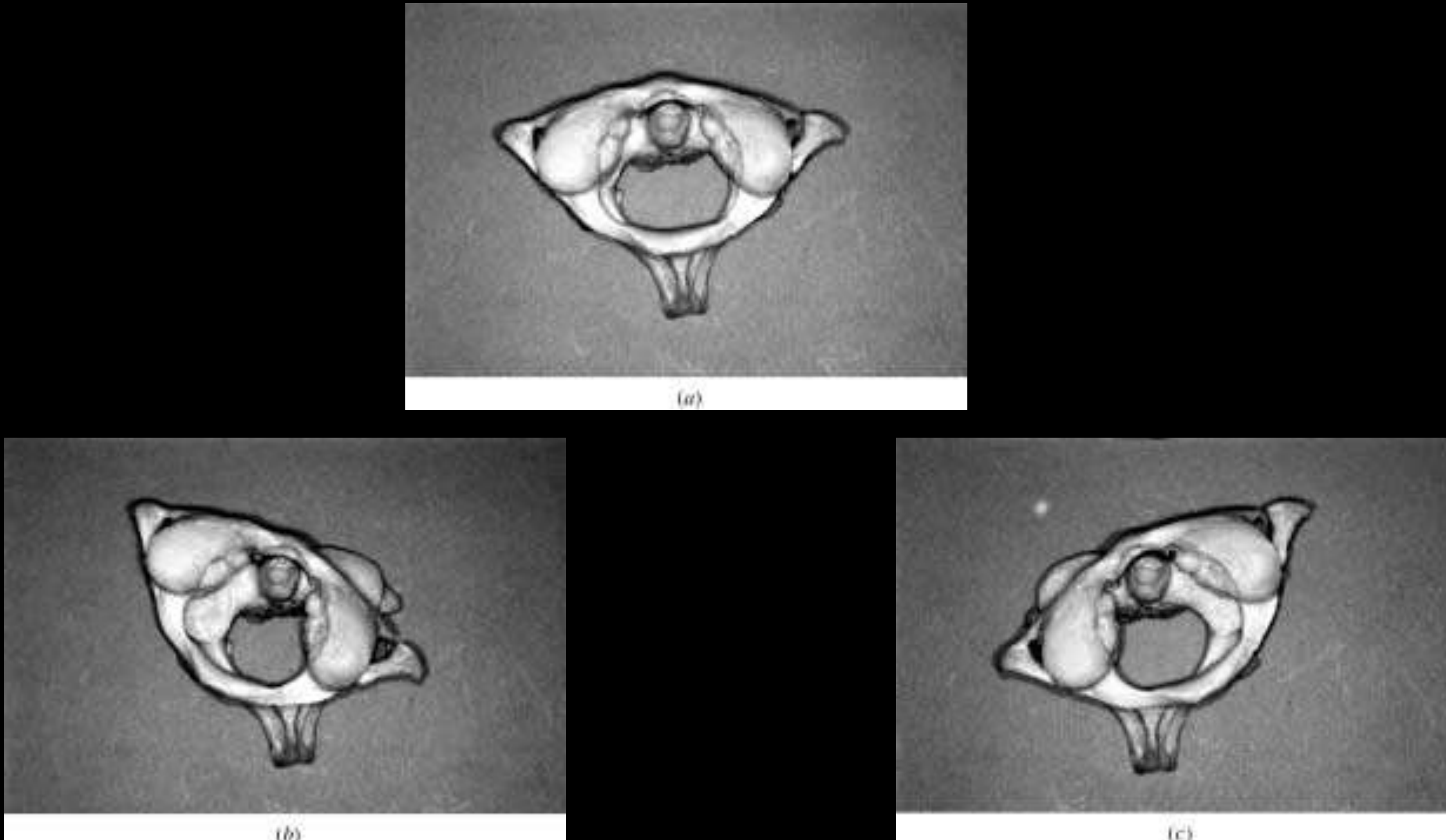

Roche CJ, King SJ, Dangerfield PH, Carty HM. The atlanto-axial joint: physiological range of rotation on MRI and CT. Clin Radiol. 2002 Feb;57(2):103-8.

C1-C2 Injection

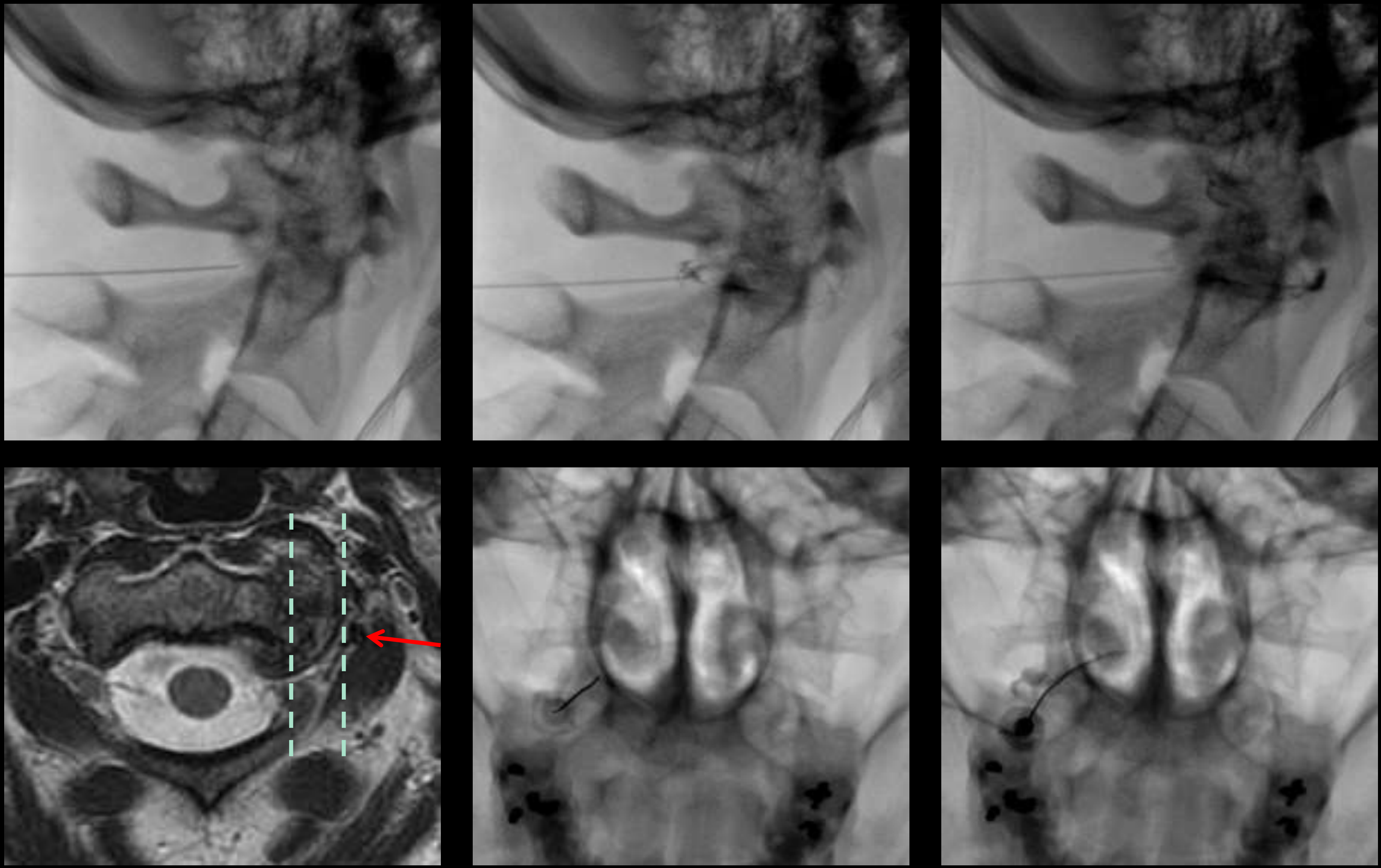

Spinal Organization: Subaxial

C2 to sacrum: organized in a similar pattern with three types of joints

1. *Intervertebral discs* (fibrocartilaginous symphyses) between vertebrae
2. *Facet jt (zygapophysial jt)* between sup and inf articular processes, a synovial joint
3. *Fibrous joints* include ligamentum flava, interspinous ligaments, and supraspinous ligaments

Systematic Nomenclature

"DISC"

Anterior intervertebral joint

Intervertebral amphiarthroses (intervertebral symphyses)

Inter-body joint

"FACET"

Posterior intervertebral joint

Intervertebral diarthroses

Zygoapohysial joints

Intervertebral Discs

- Found from the axis to the sacrum
  - Different characteristics
- Immensely strong fibrocartilaginous structures which are strongest bonds between adjacent vertebrae.
- Outer anulus fibrosis and inner nucleus pulposus
- Concentric lamellae

INTERVERTEBRAL DISC

- Anterior or posterior longitudinal ligaments
- Periosteofascial tissue
- Intrinsic fibers of the anulus fibrosis
- Deep core of fibrocartilagnous material

Mercer S. The Ligaments and Anulus Fibrosis of Human Adult Cervical Intervertebral Discs. Spine 1999;24:619.

Cervical Intervertebral Discs

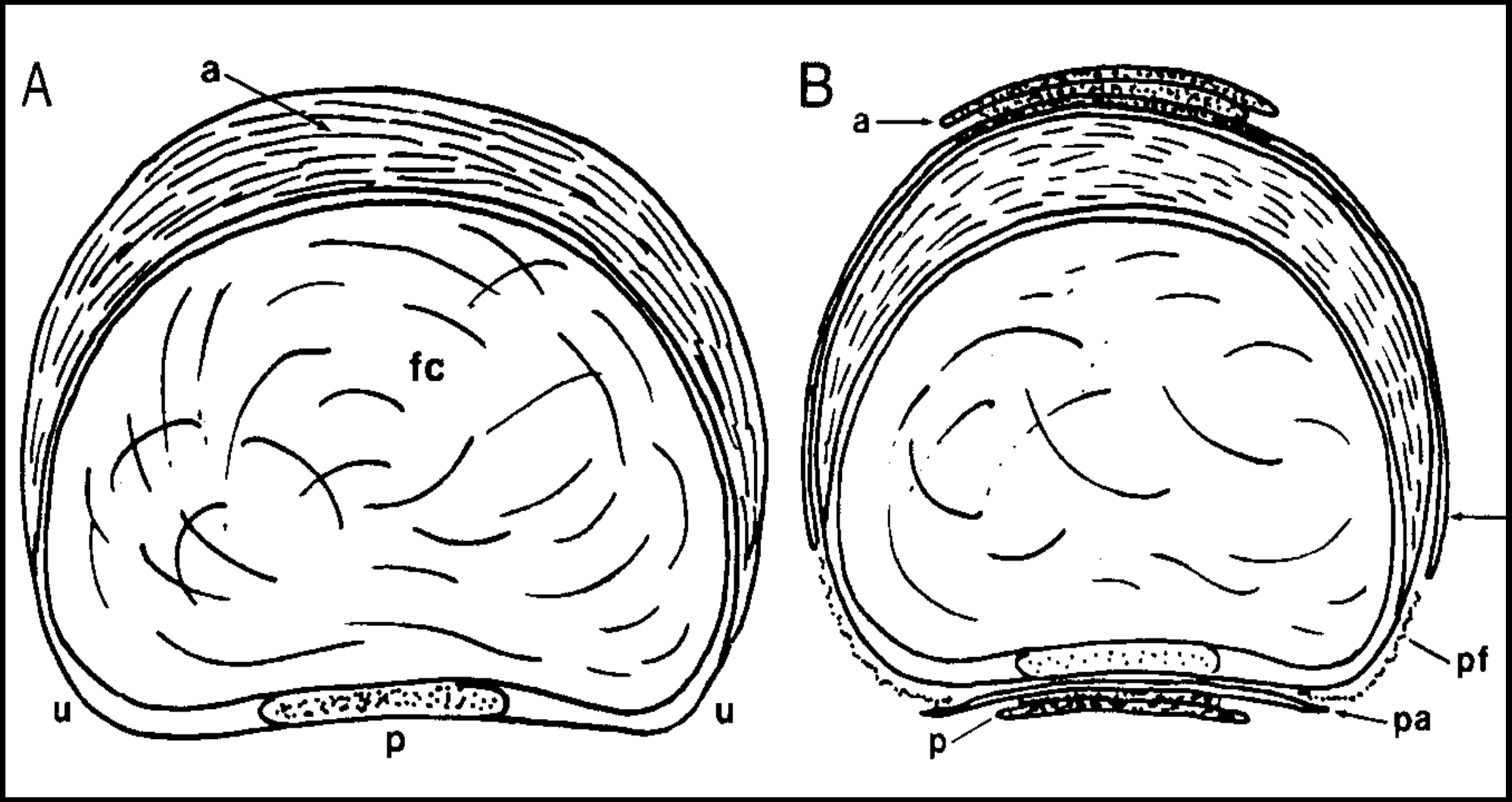

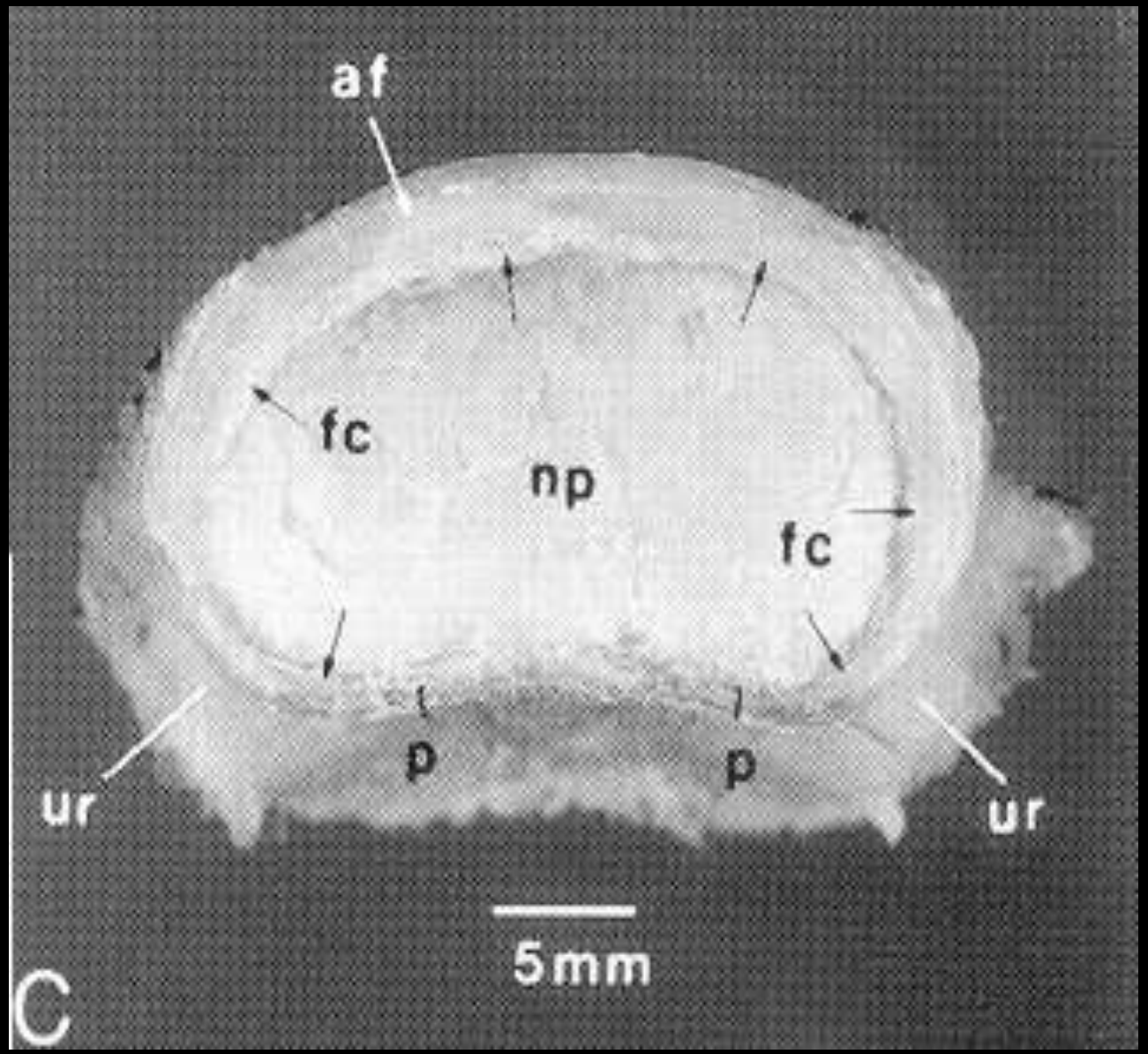

- Anulus fibrosus is much thicker anteriorly with crescentic mass of collagen (No ring of fibers surrounding the nucleus pulposus)
- Anulus fibrosus essentially deficient posterolaterally

Mercer S. The Ligaments and Anulus Fibrosis of Human Adult Cervical Intervertebral Discs. Spine 1999;24:619.

C-spine Biomechanics



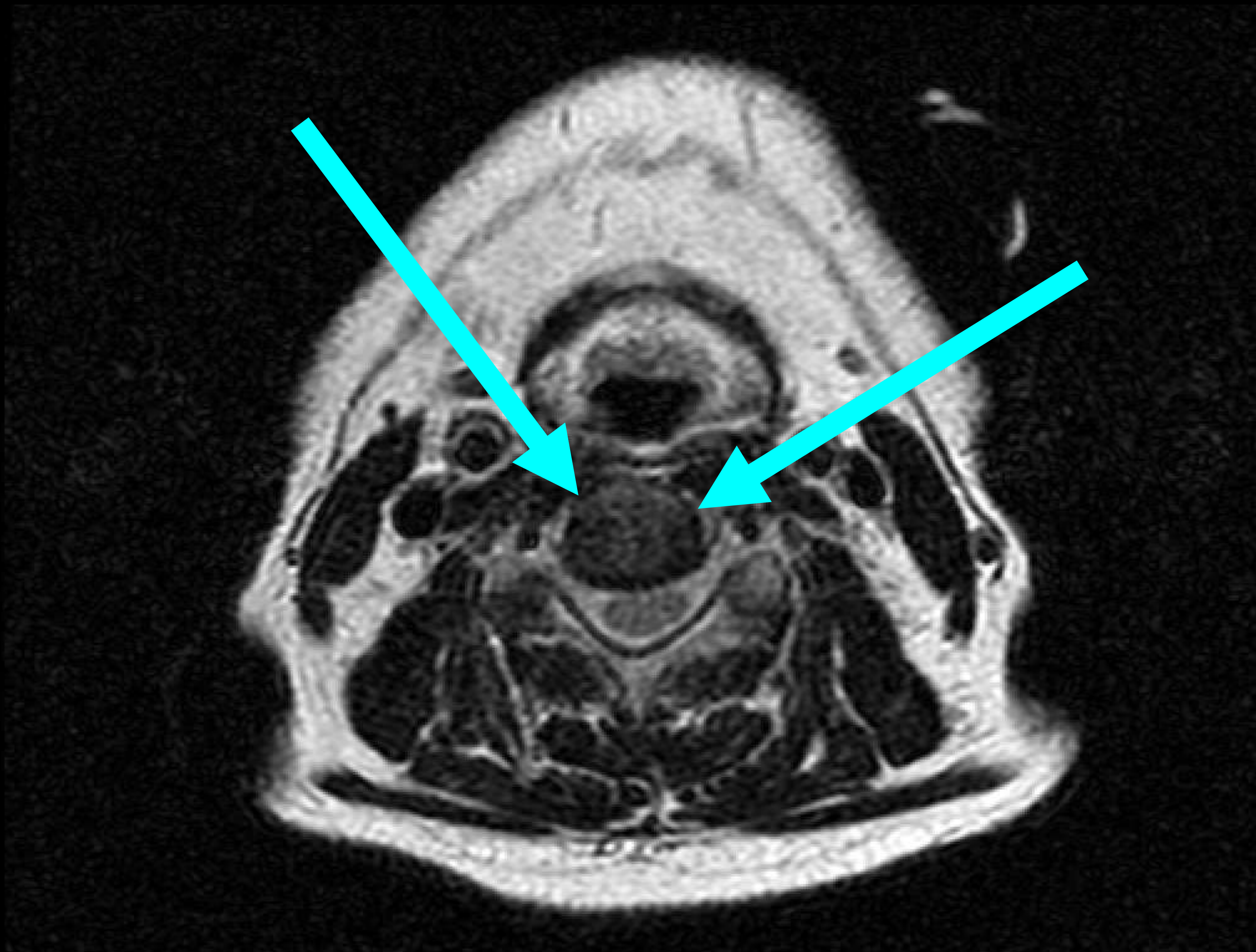

C-spine discography: approach

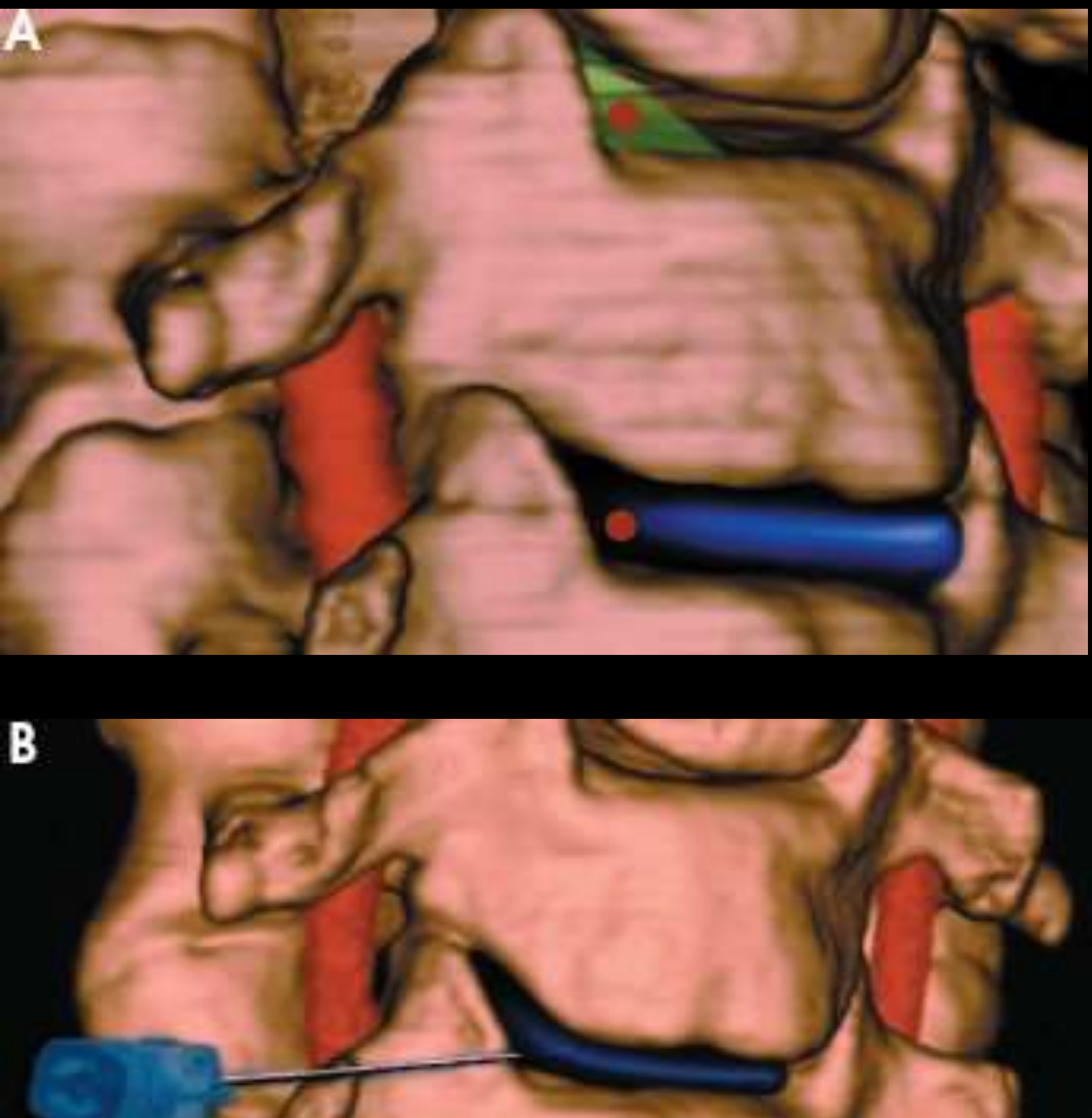

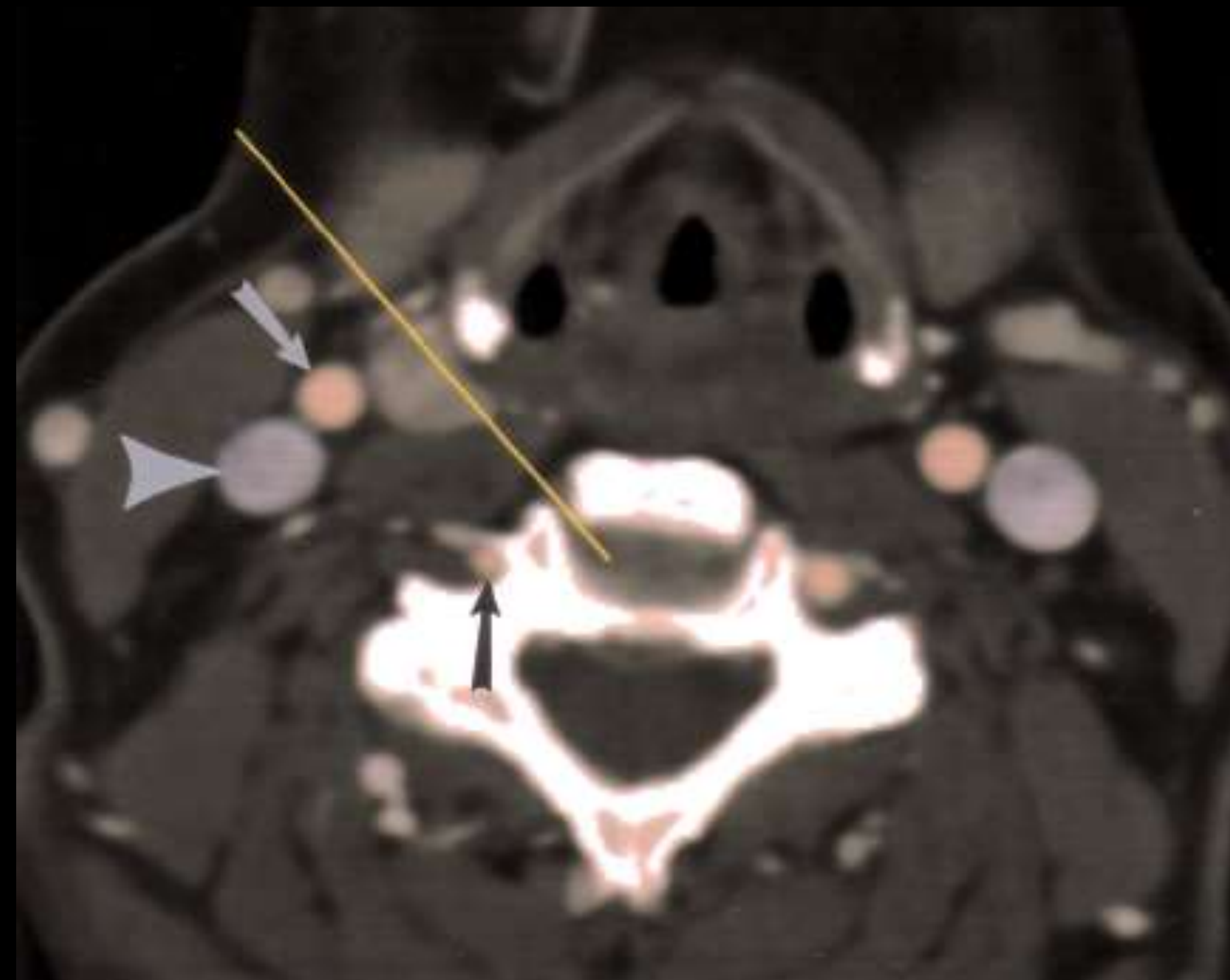

Simplified approach to discography: Two triangles and a box

Vibhu Kapoor, MD; William E. Rothfus, MD; Stephen Z. Grahovac, MD

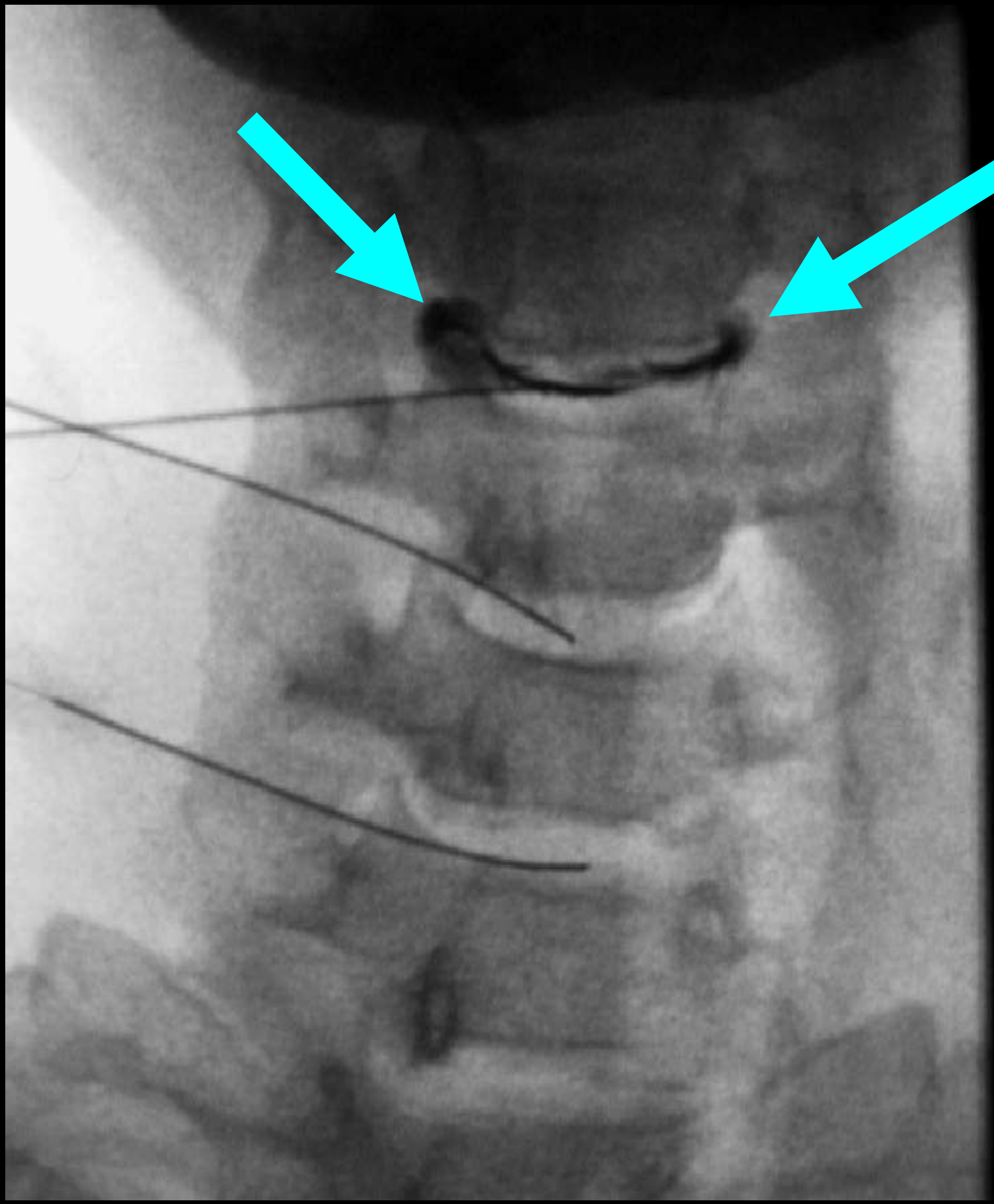

uncoveretebral
joint
opacification

C-spine
discography

Sub-Axial Cervical Spine: Uncinate Processess

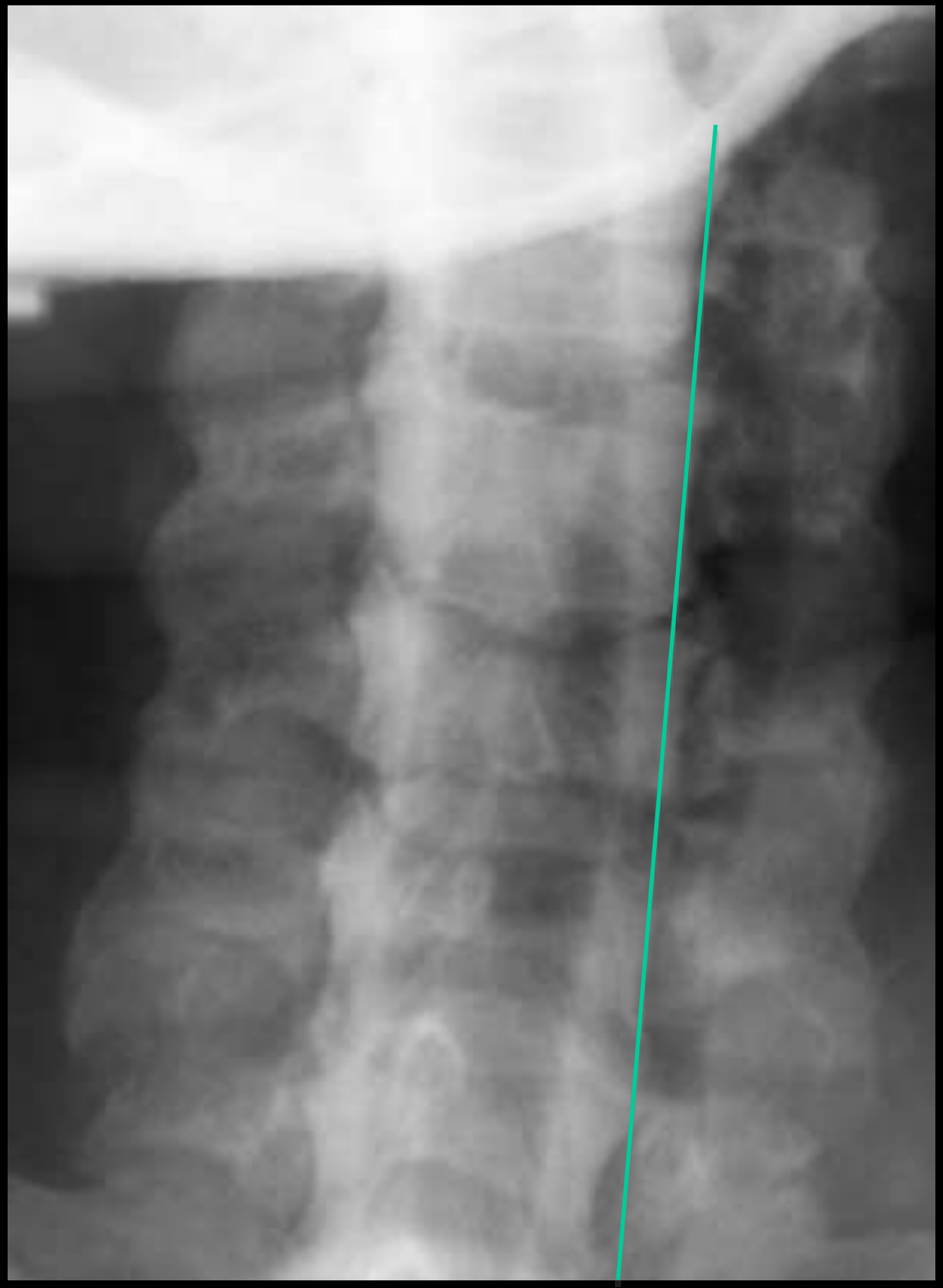

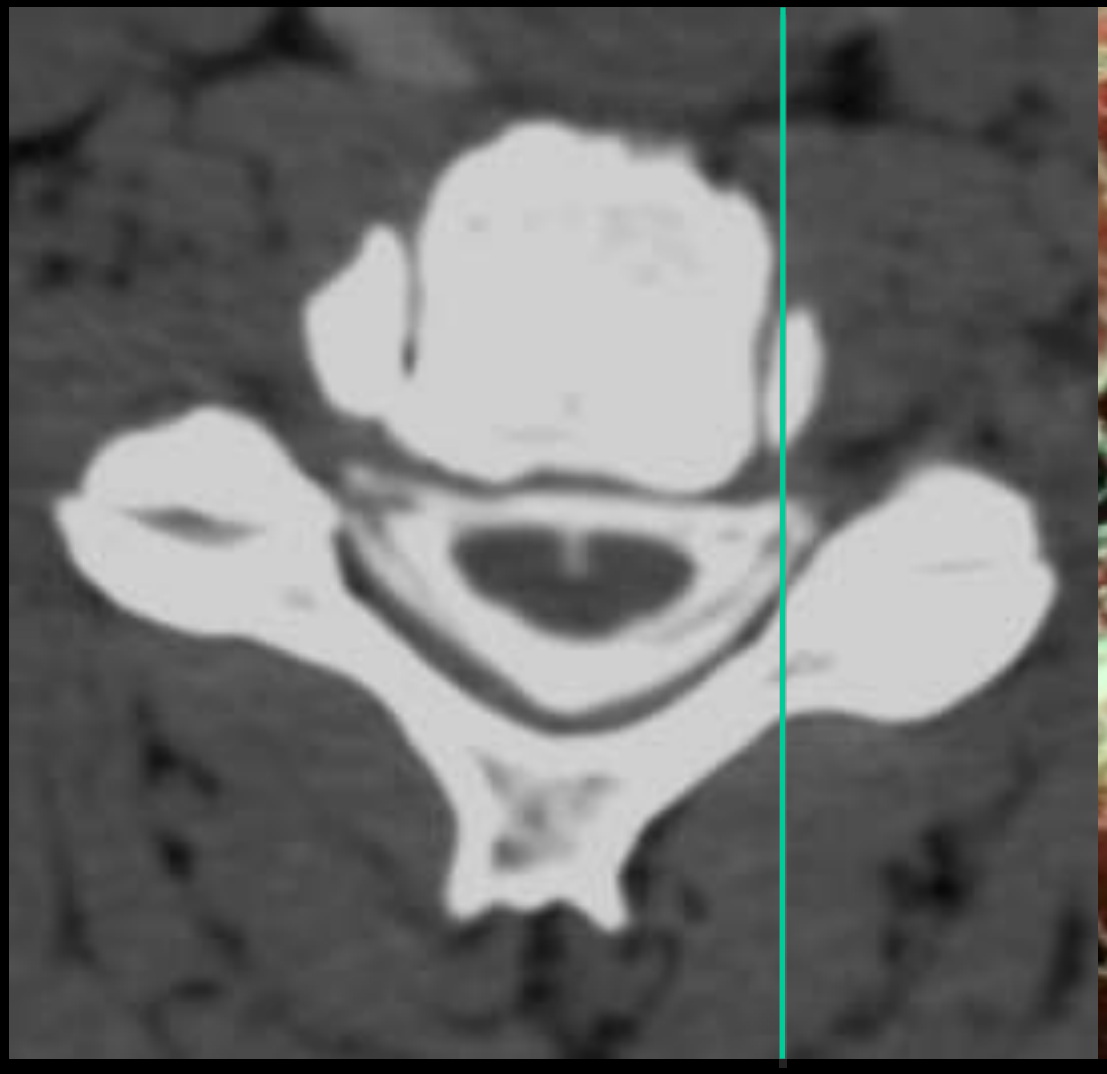

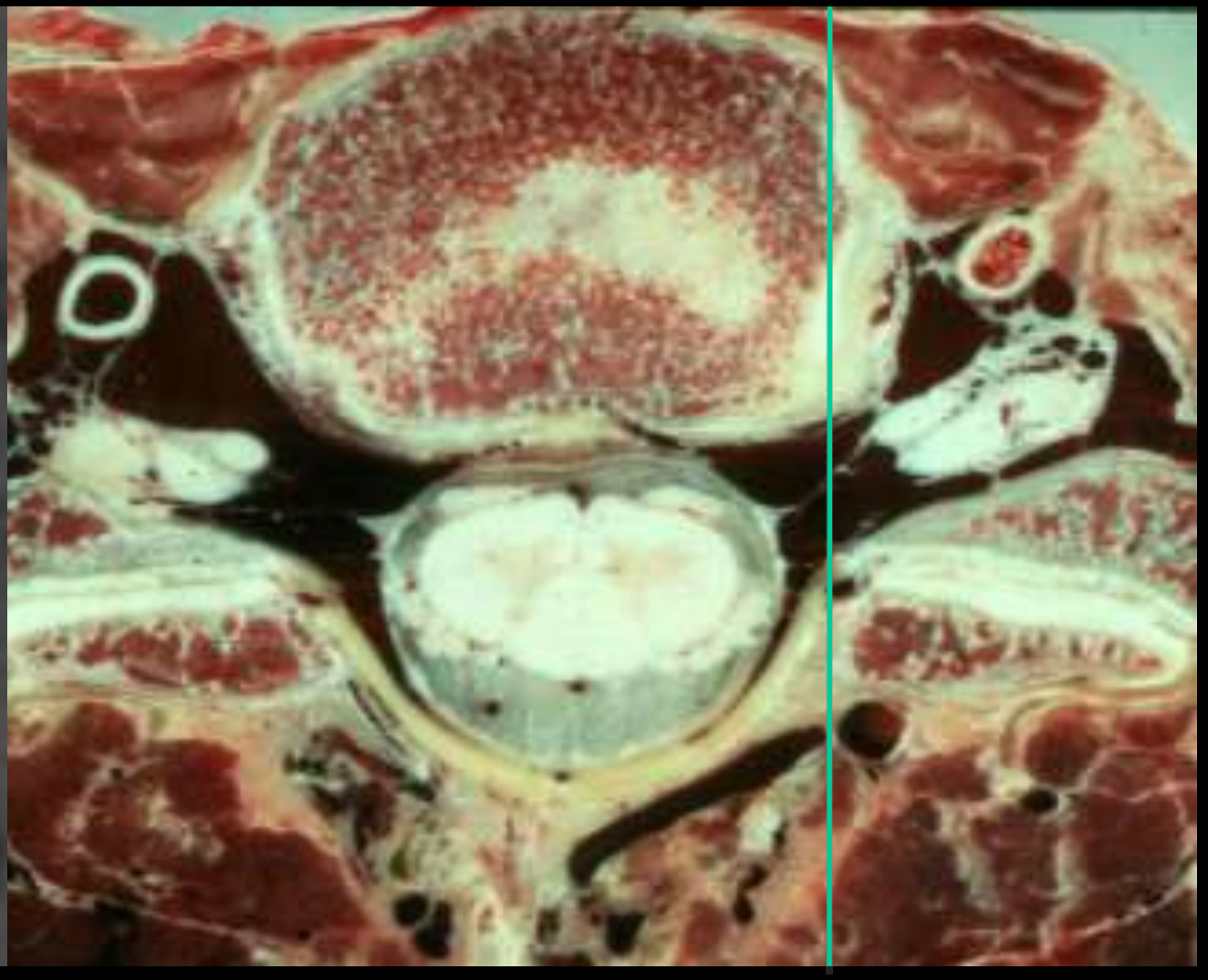

Intervertebral Discs

Normal discs are hyperintense on T2 (predominately the nucleus pulposus)

With advancing age the water content of the nucleus pulposus decreases, manifested as decreased T2 signal in the disc

Lumbar Intervertebral Disc: component structures

Nucleus Pulposus

Anulus Fibrosus

Cartilagenous Endplate

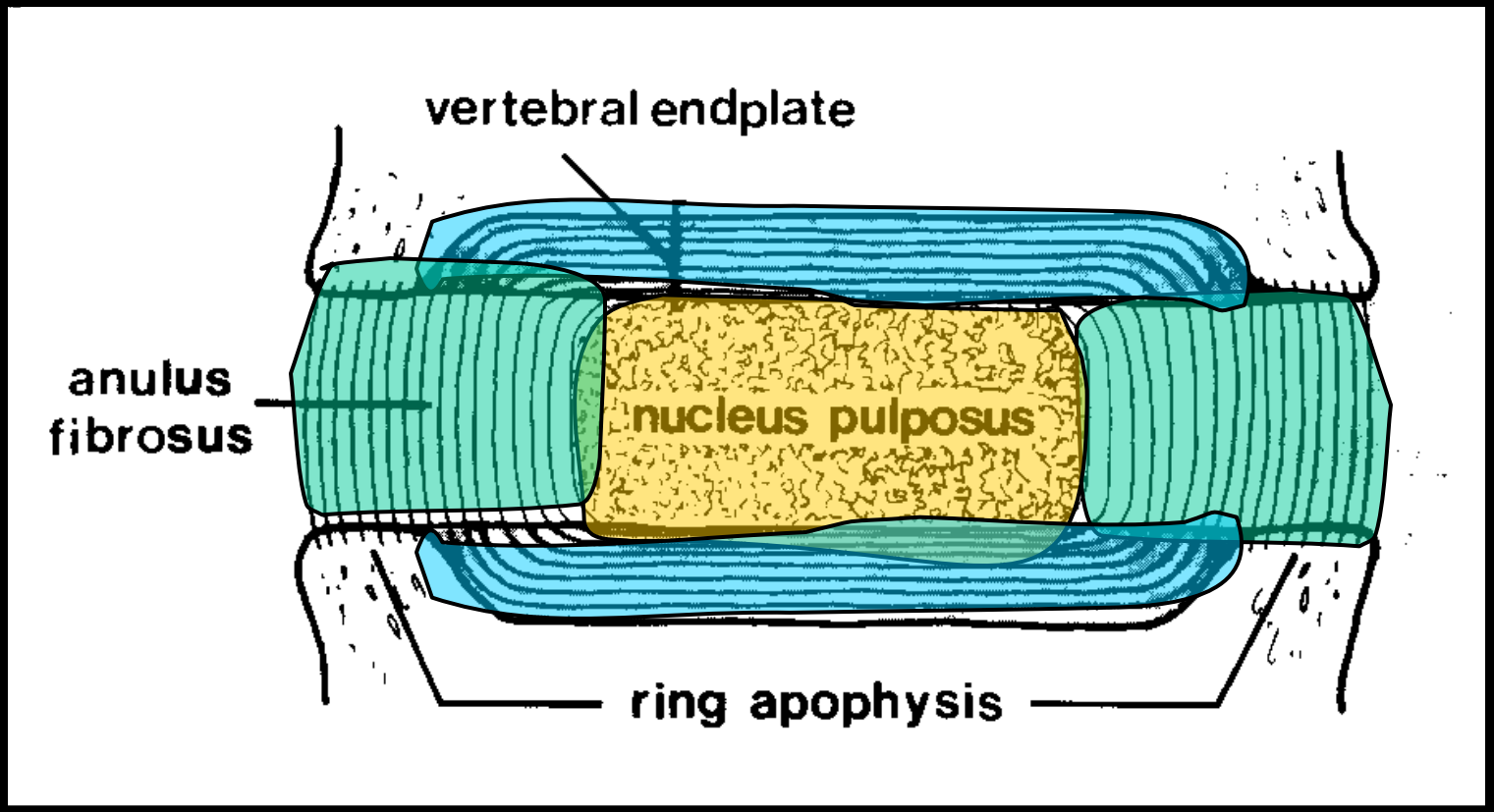

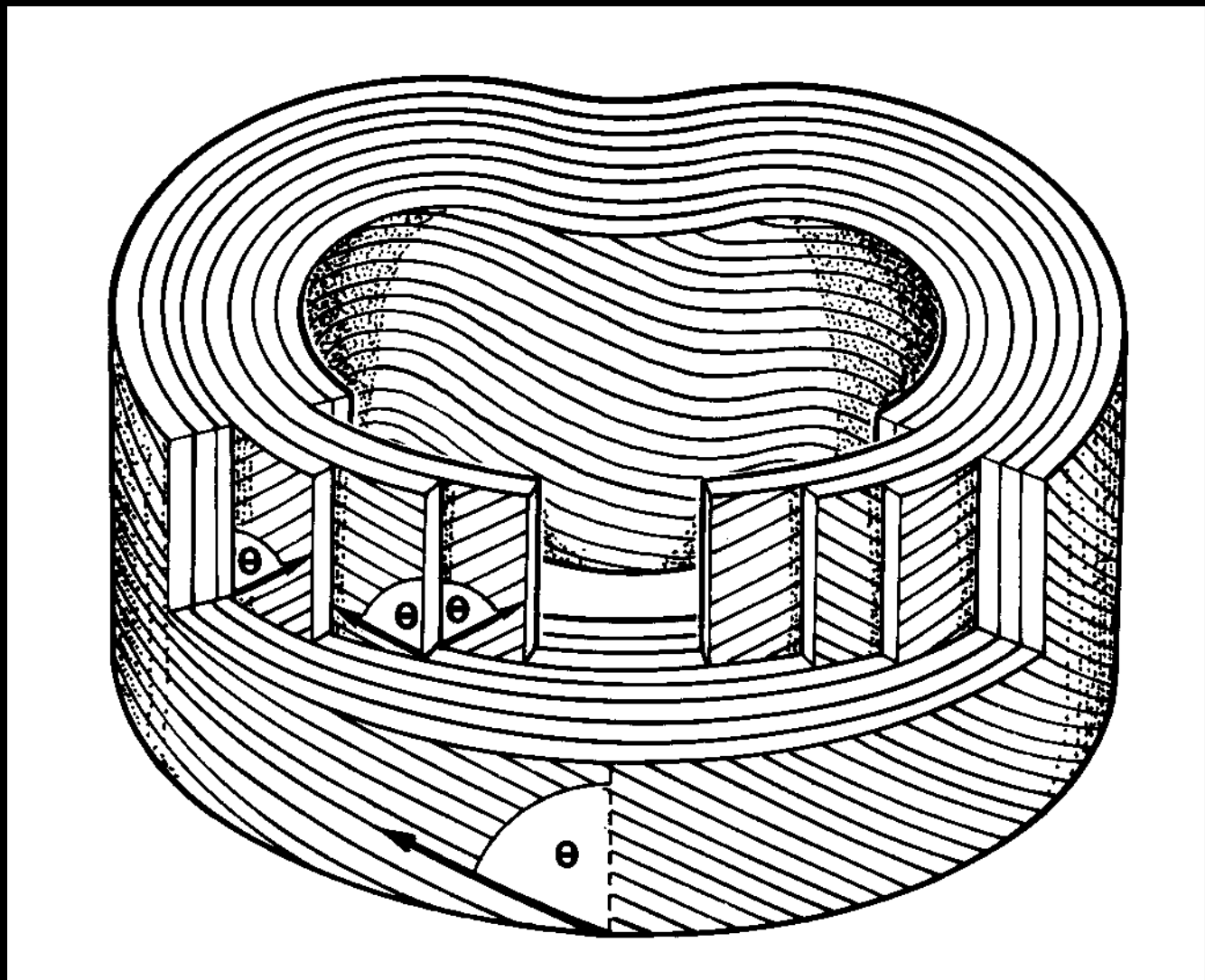

Lumbar intervertebral Discs

- Disc height gradually increases inferiorly except at L5-S1
- Posterior margin concave in upper lumbosacral spine
- Post. margin straight or convex at L4-5 and L5-S1
- Post. margin projects no more than 1 mm beyond end plate

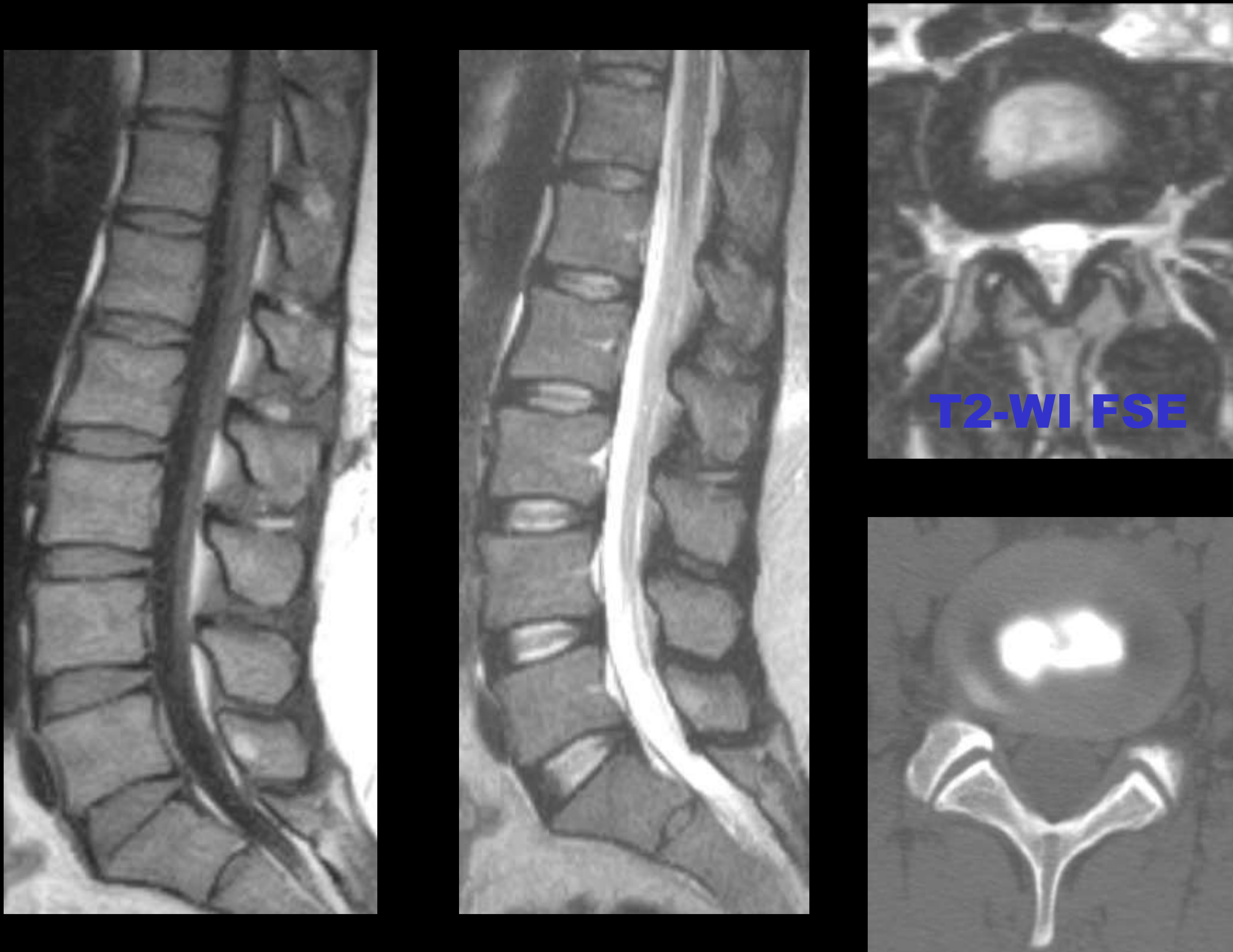
T2-WI FSE

Intervertebral Discs: clefts

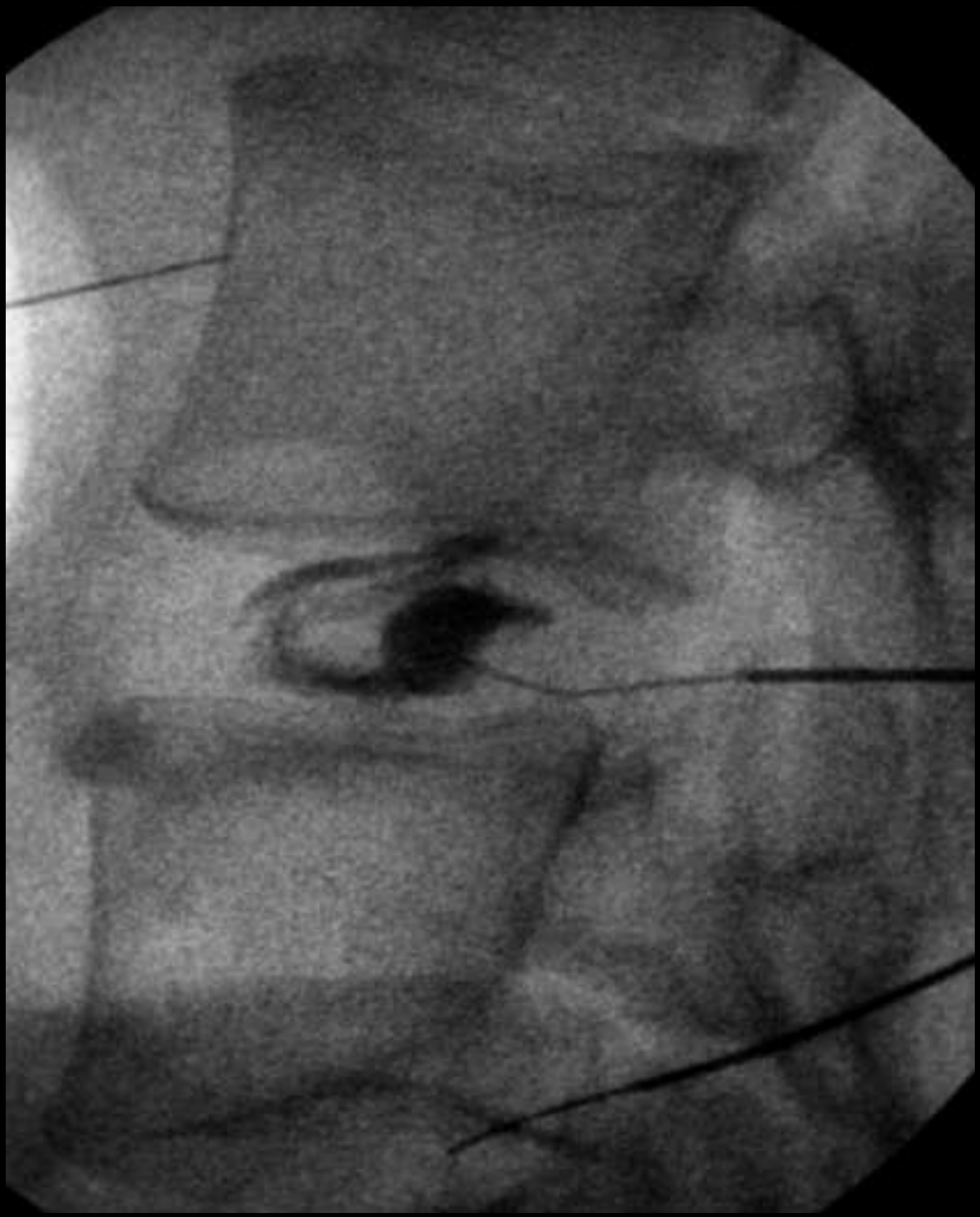

T1-WI CSE

T2-WI FSE

Normal Variant: Schmorls Node

T1-WI SE

T2-WI FSE

Facet Joints

articulation of the inferior articular process of the posterior elements of a vertebra with the superior articular process of the posterior elements of the next vertebra

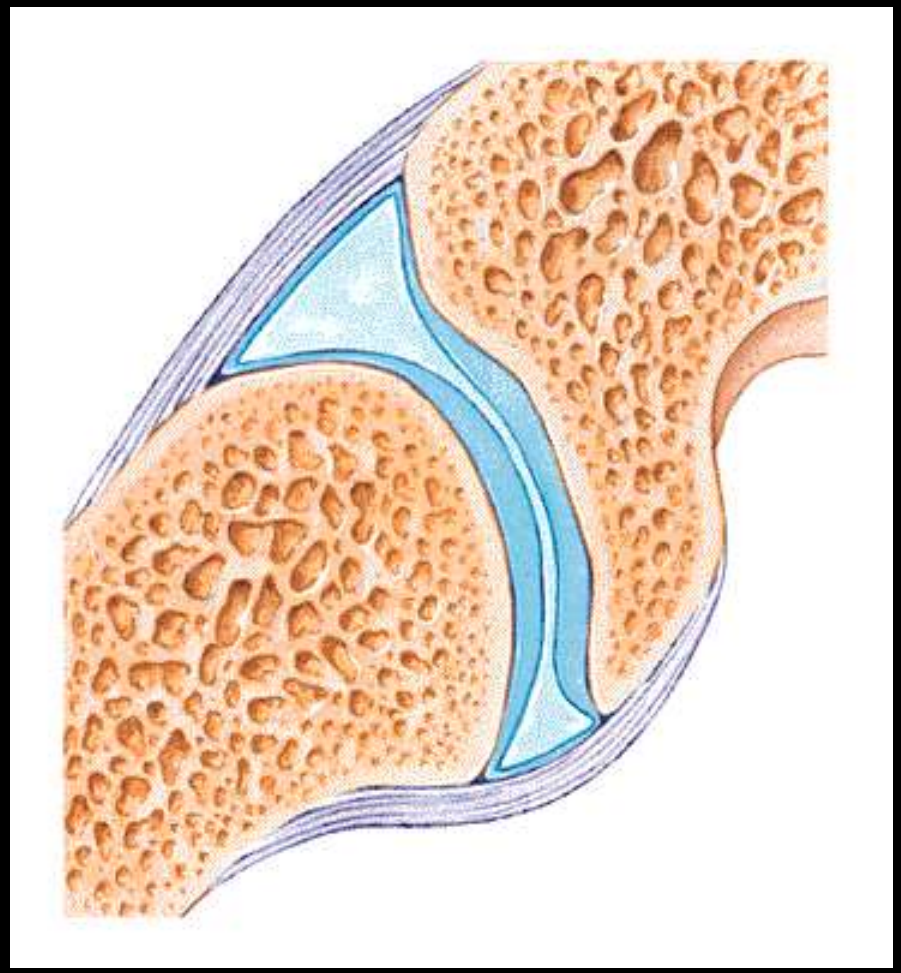

synovial type joint

- capsule,
- synovium
- reciprocating surfaces lined by hyaline (articular) cartilage
- menisci

Facet Joints

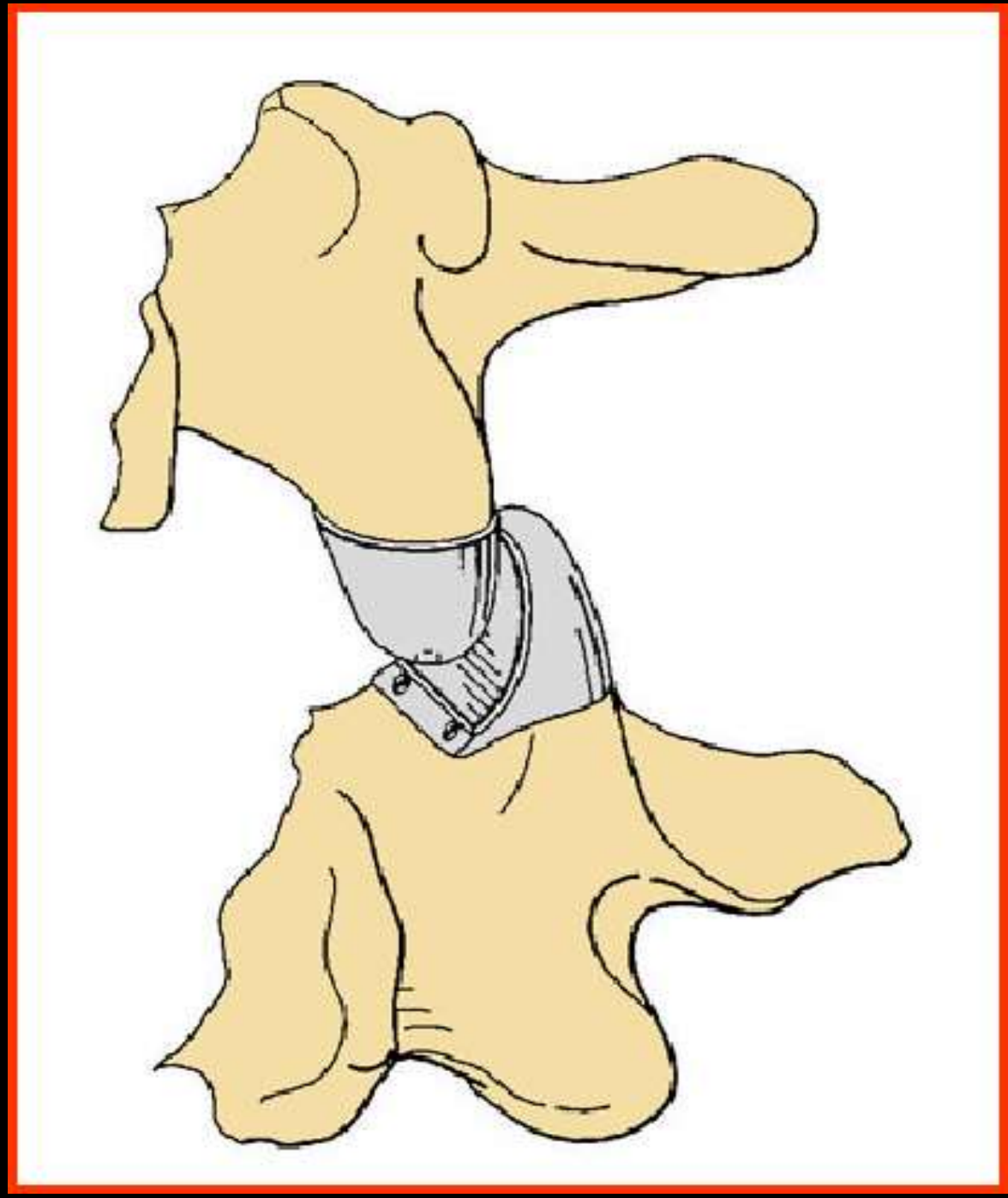

Zygapophysial joint (z-joint)

- more appropriate term
- "facet" actually only represents the articular cartilage surface of the joint

Z-Joint Anatomy: Orientation

Oriented differently throughout spine due to varying biomechanical stress

Lumbar → Sagittal/Oblique

Cervical ➔ Transverse/Oblique

Thoracic ➔ Coronal

Lumbar ➔ Sagittal/Oblique

Cervical Z-joints

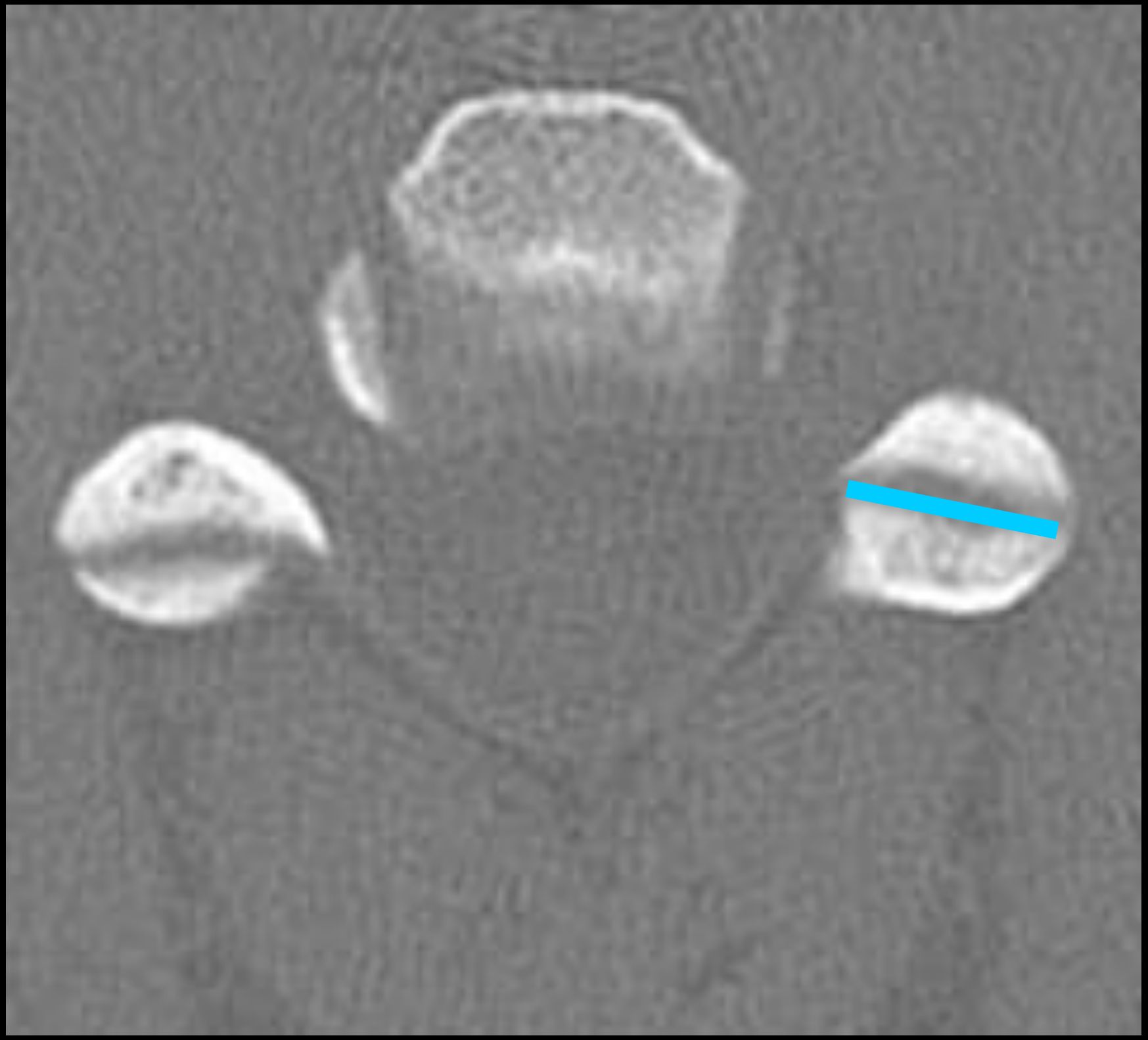



Cervical Zygapophyseal Joints

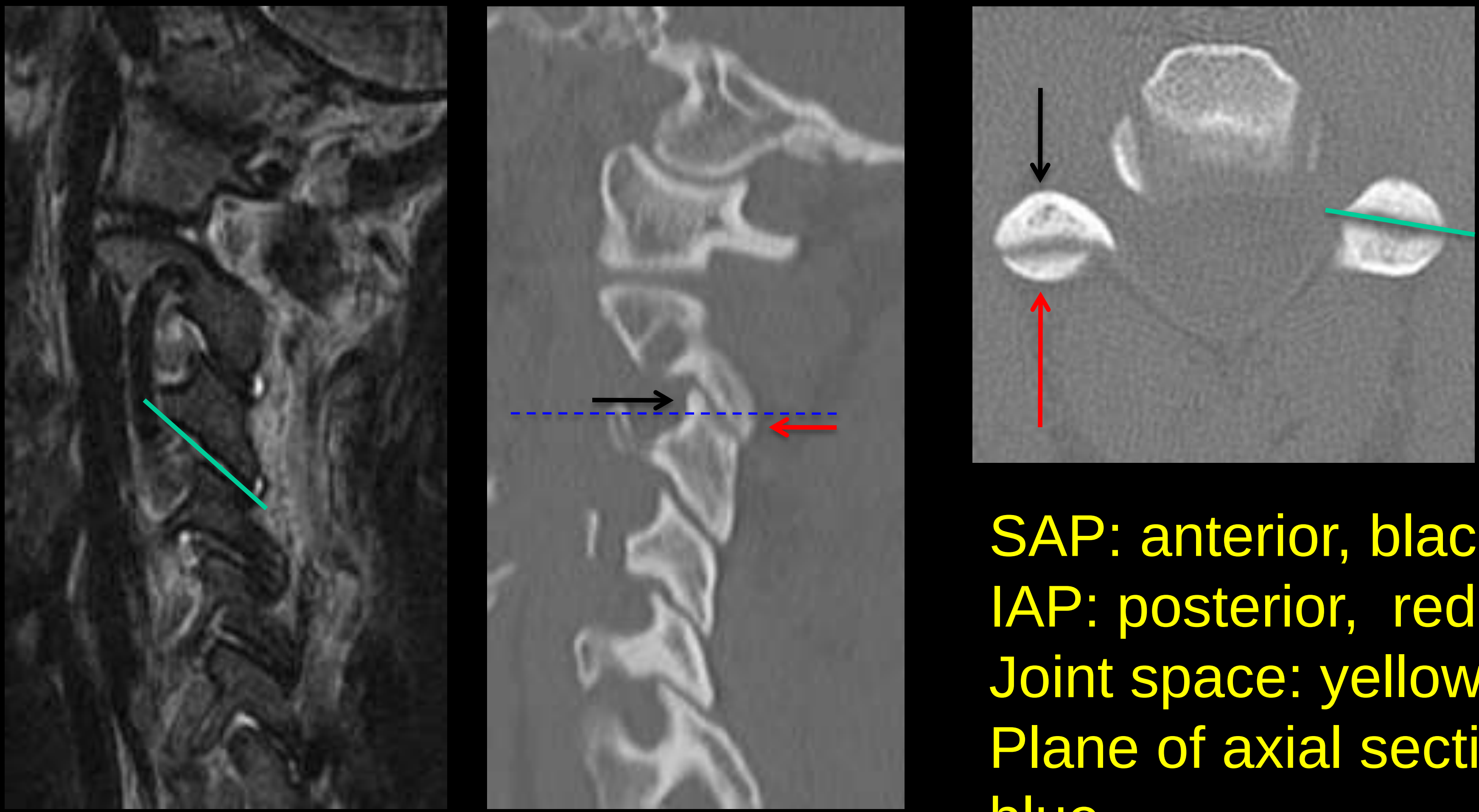

SAP: anterior, black
IAP: posterior, red
Joint space: yellow
Plane of axial section: blue

Lumbar Z-joints

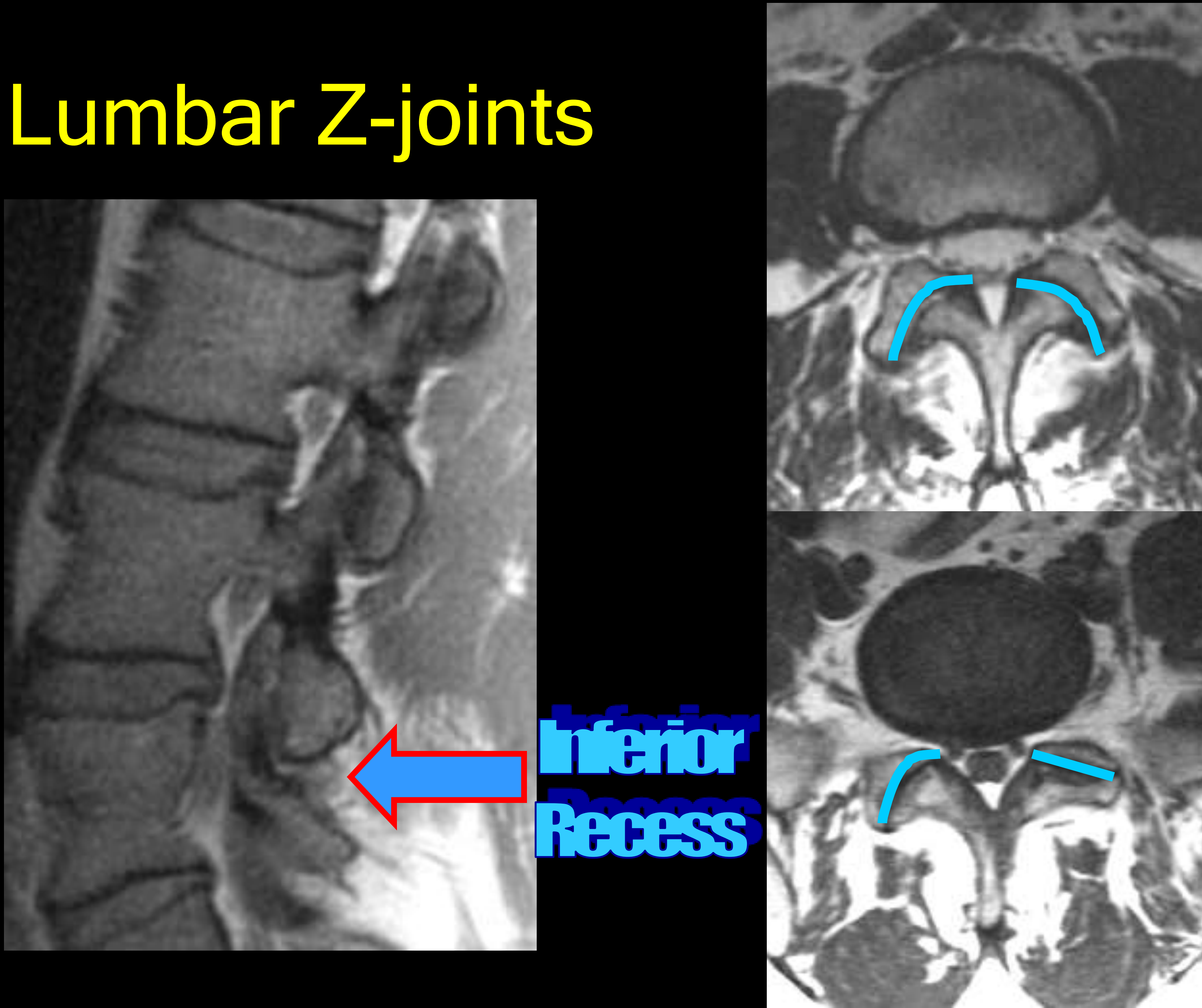

Z-Joint Tropism

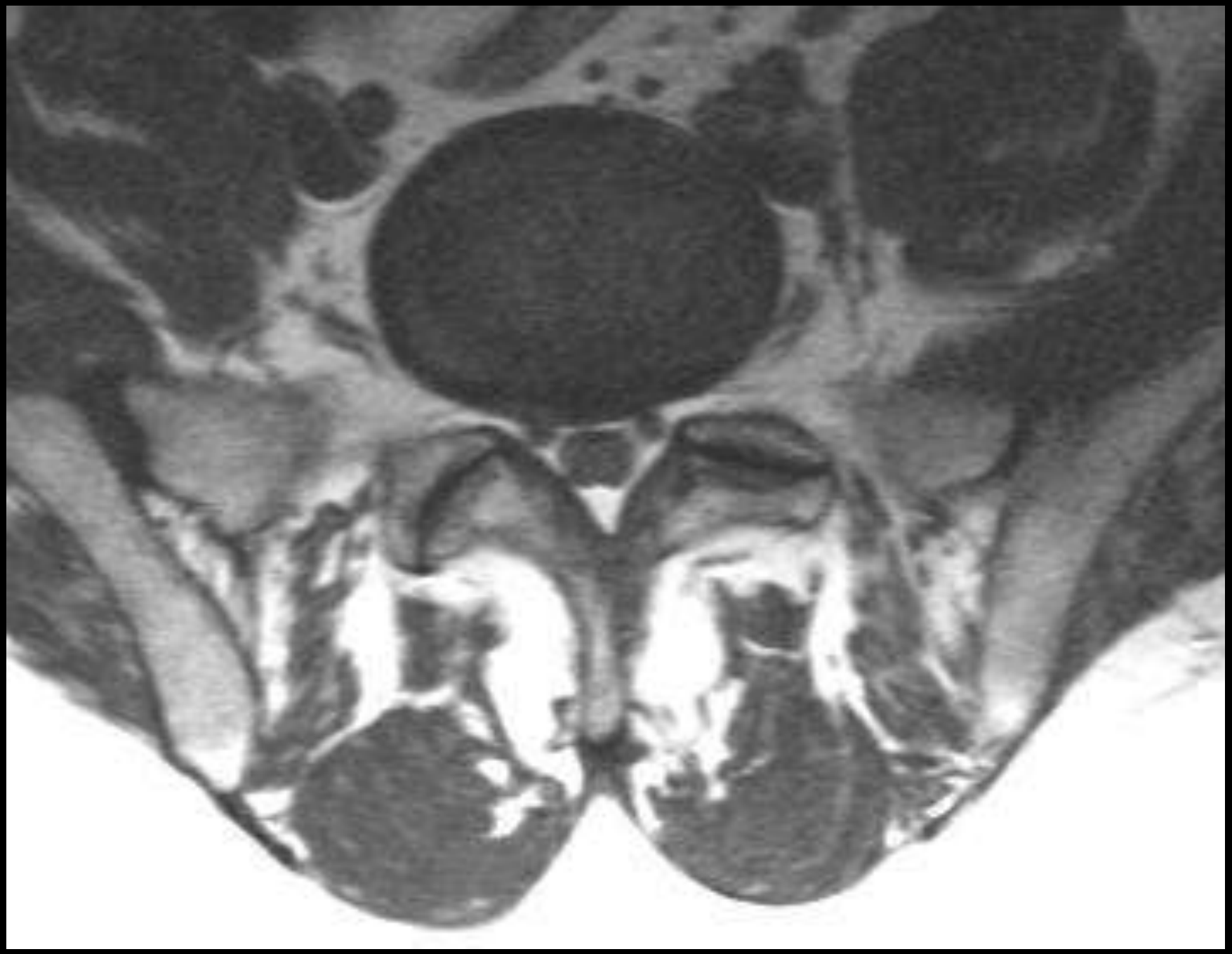

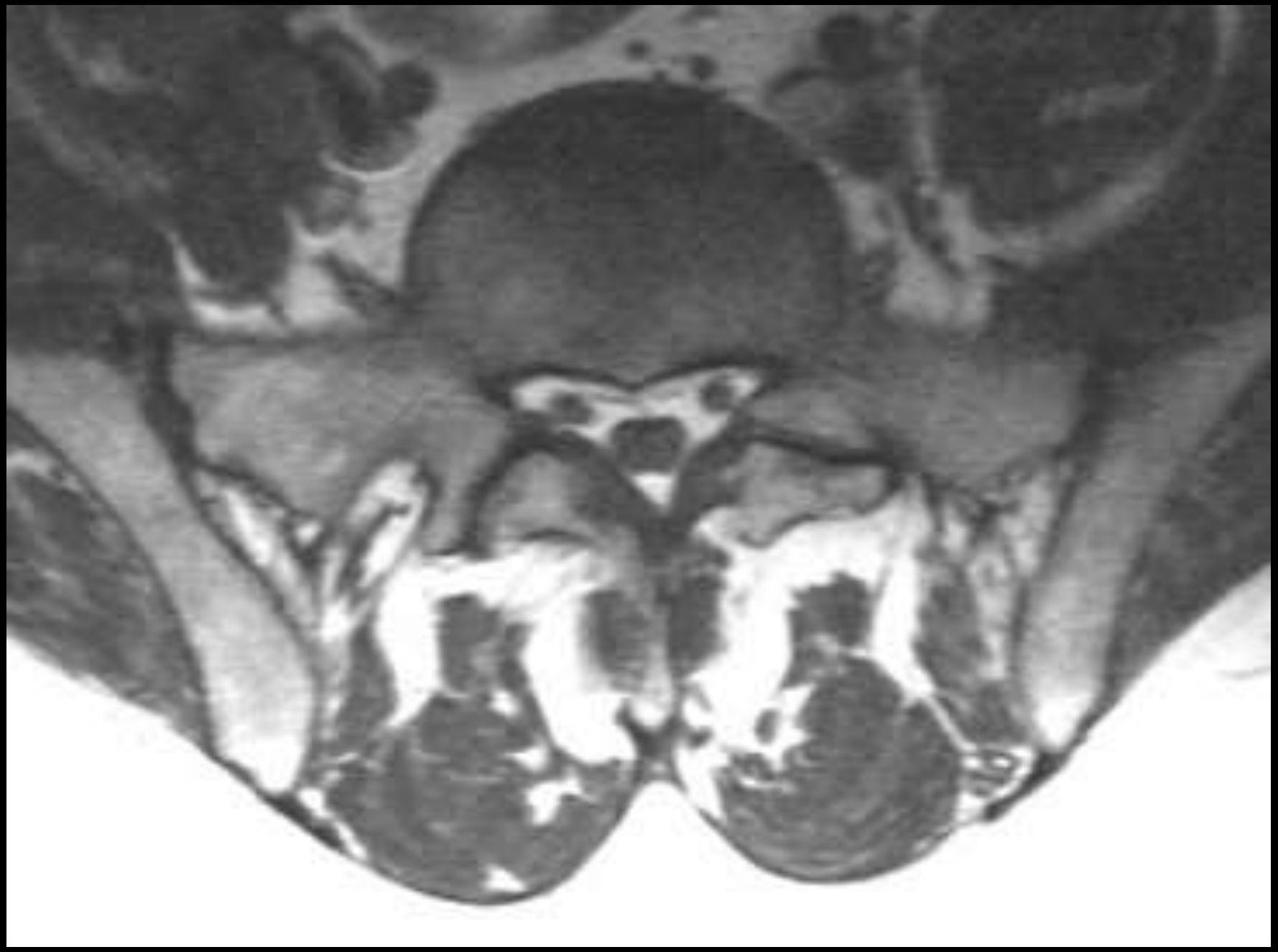

Sacroiliac Joint

Small range of motion

No muscle that execute active movements

Passive movements

"Stress relieving"

SI Joint: Biomechanics

Axes of movement passes obliquely across pelvis

Flexion: axis passes backwards from pubic symphysis to sciatic notch

Extension: axis passes from pubic symphysis through pelvis between ischium and coccyx

complex movements

SI Joint: MR

SI Joint: MR

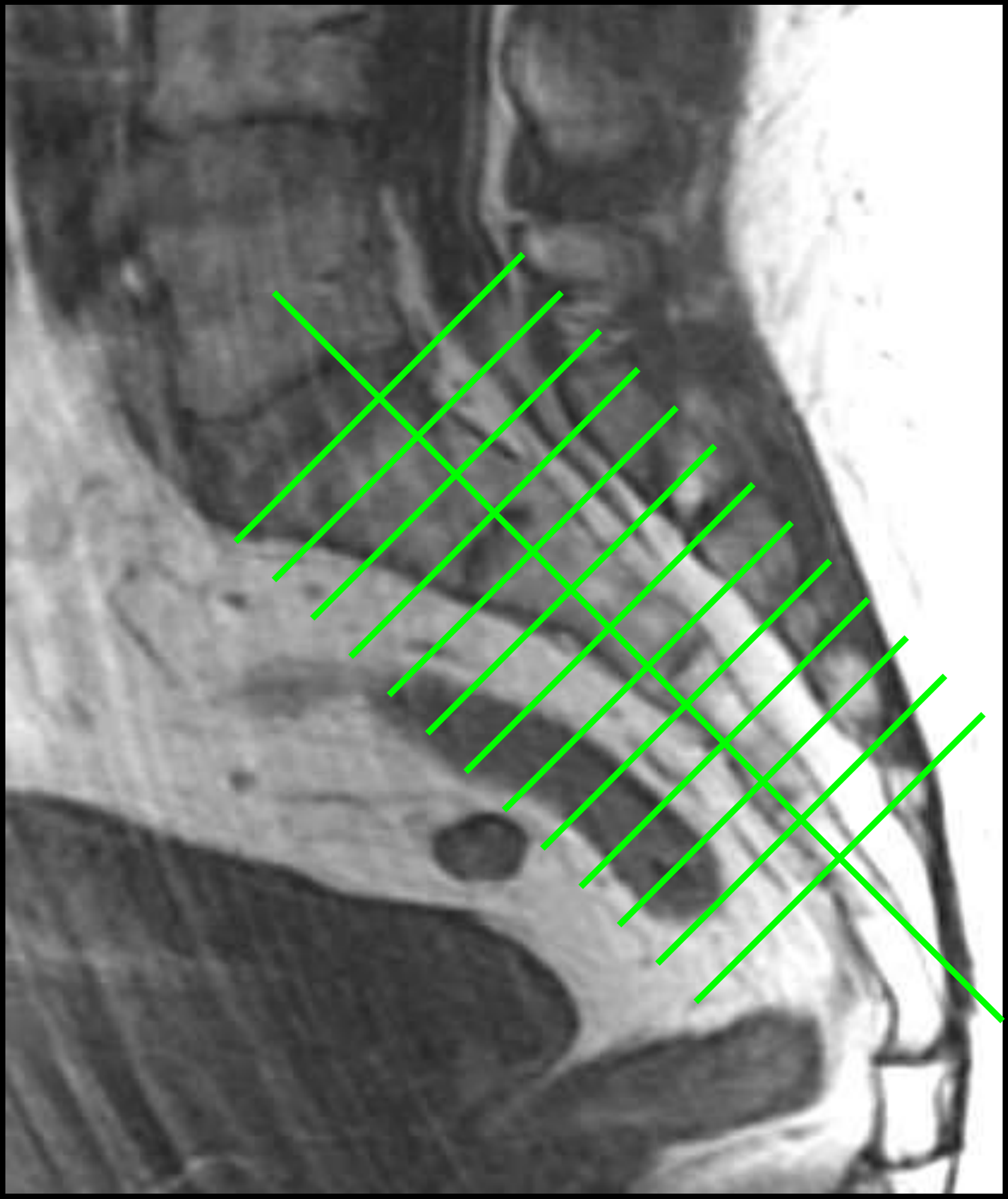

SI Joint: Age Changes

Embryo: strip of mesenchyme → cavitation

1st decade: joint enlarges but surface flat

2nd decade: corrugation of joint surfaces

5th and 6th decade: osteophytes

8th decade: large interdigitating osteophytes

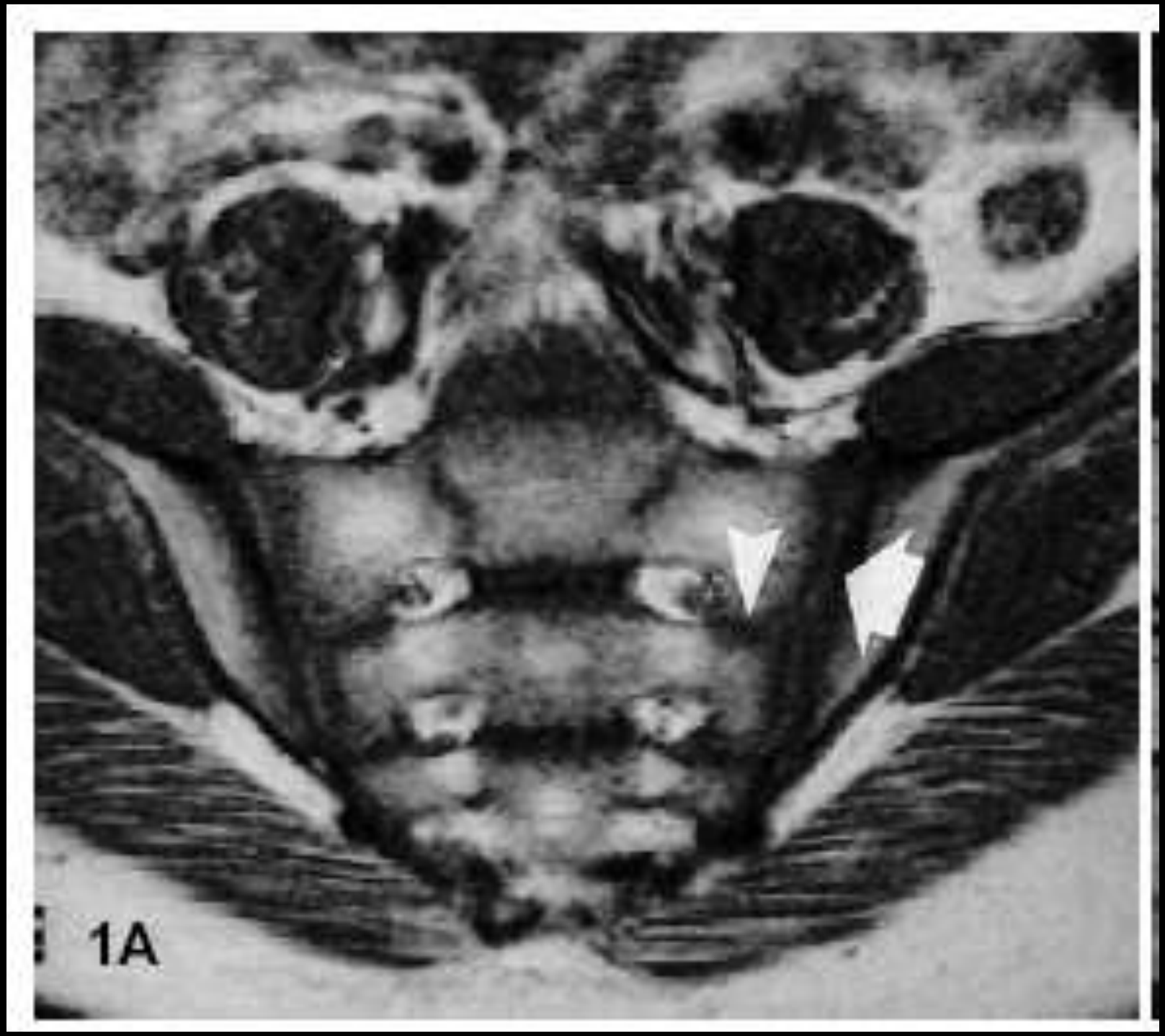

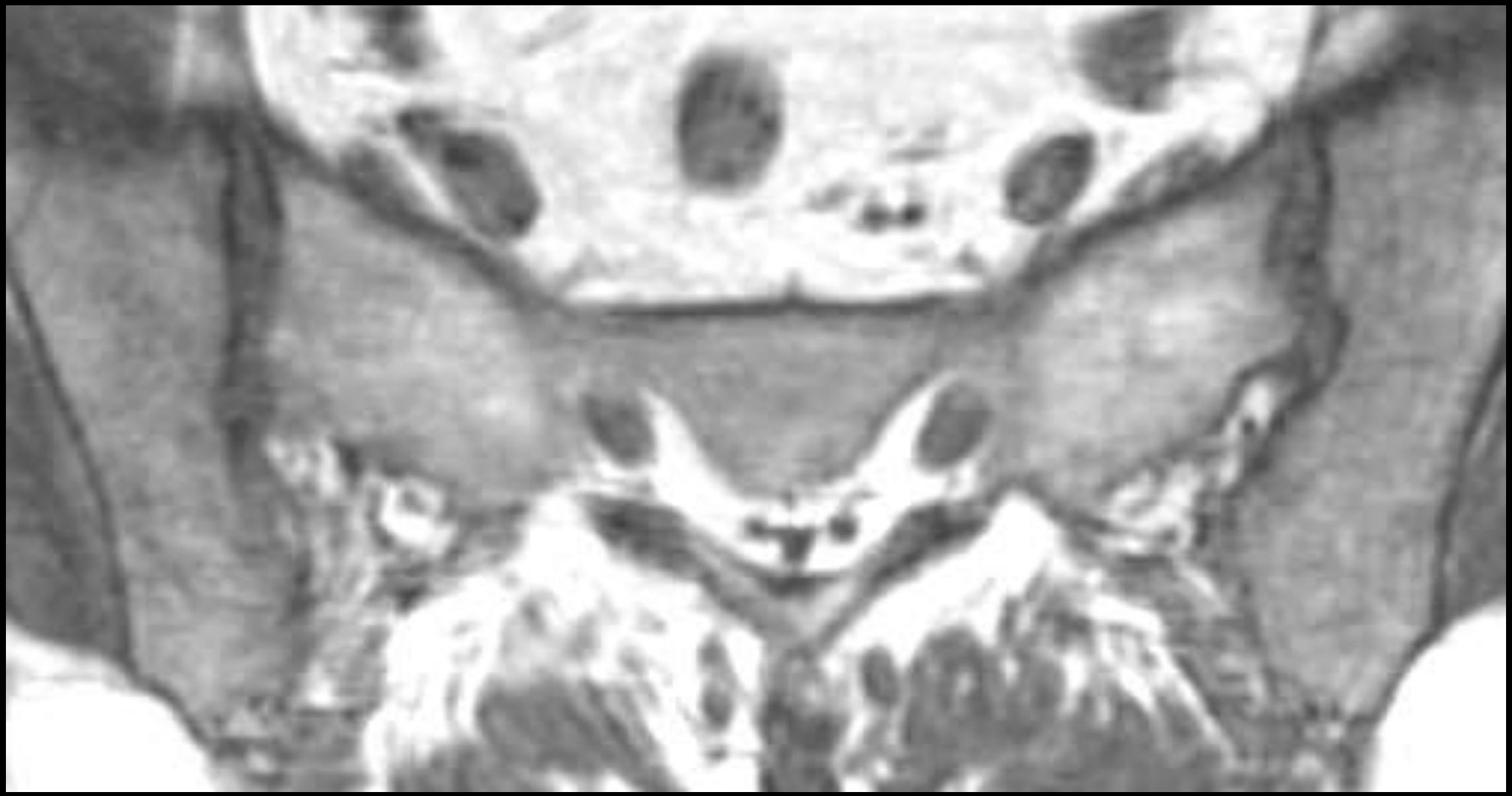

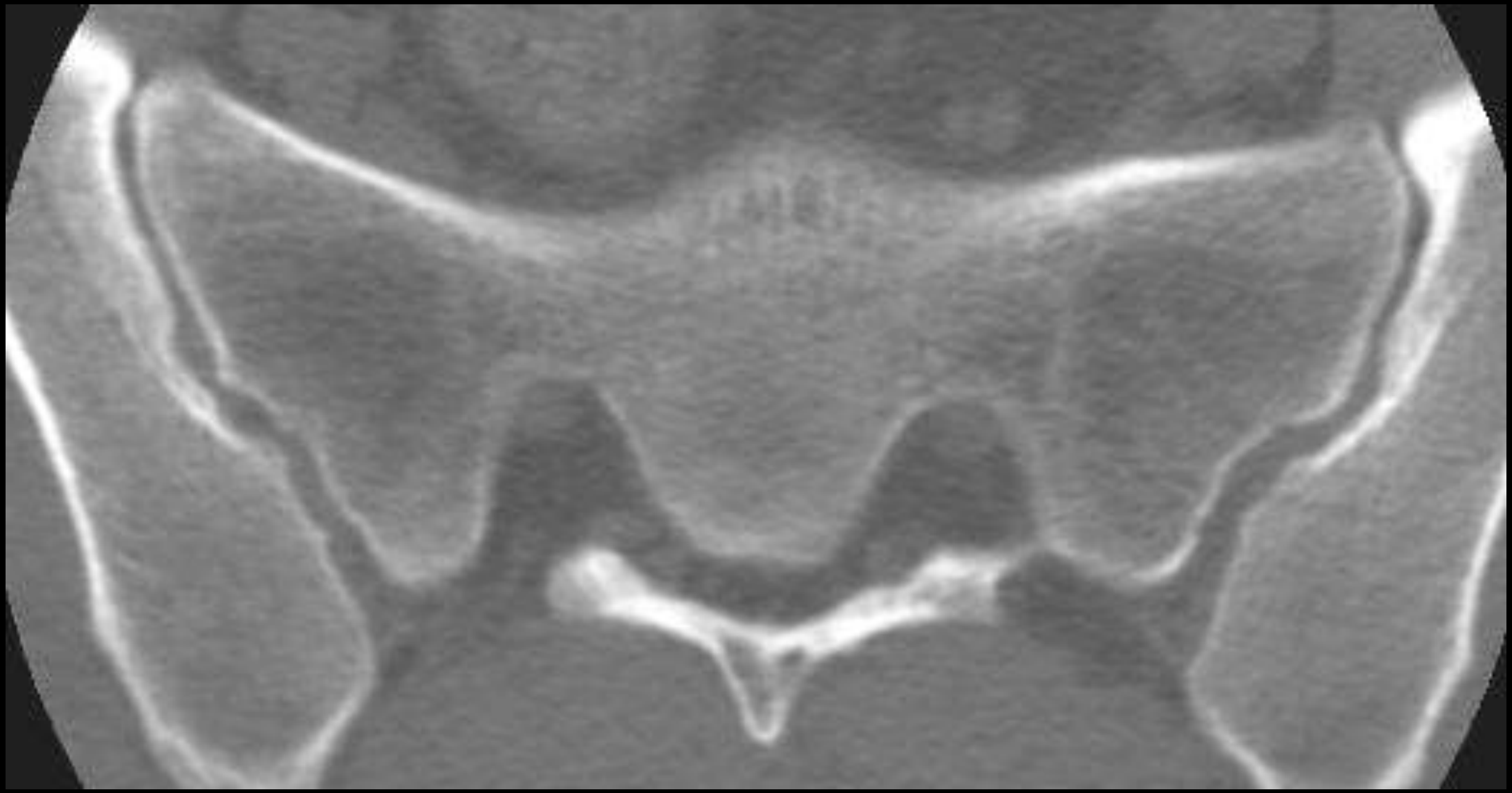

Contents

Bones

Joints

Ligaments

Muscles/tendons

Spinal Canal: Epidural/Intradural

Neural Canals/Neuroforamina

Neural Elements

Vascular Anatomy

Ligamentous Structures of Skull Base

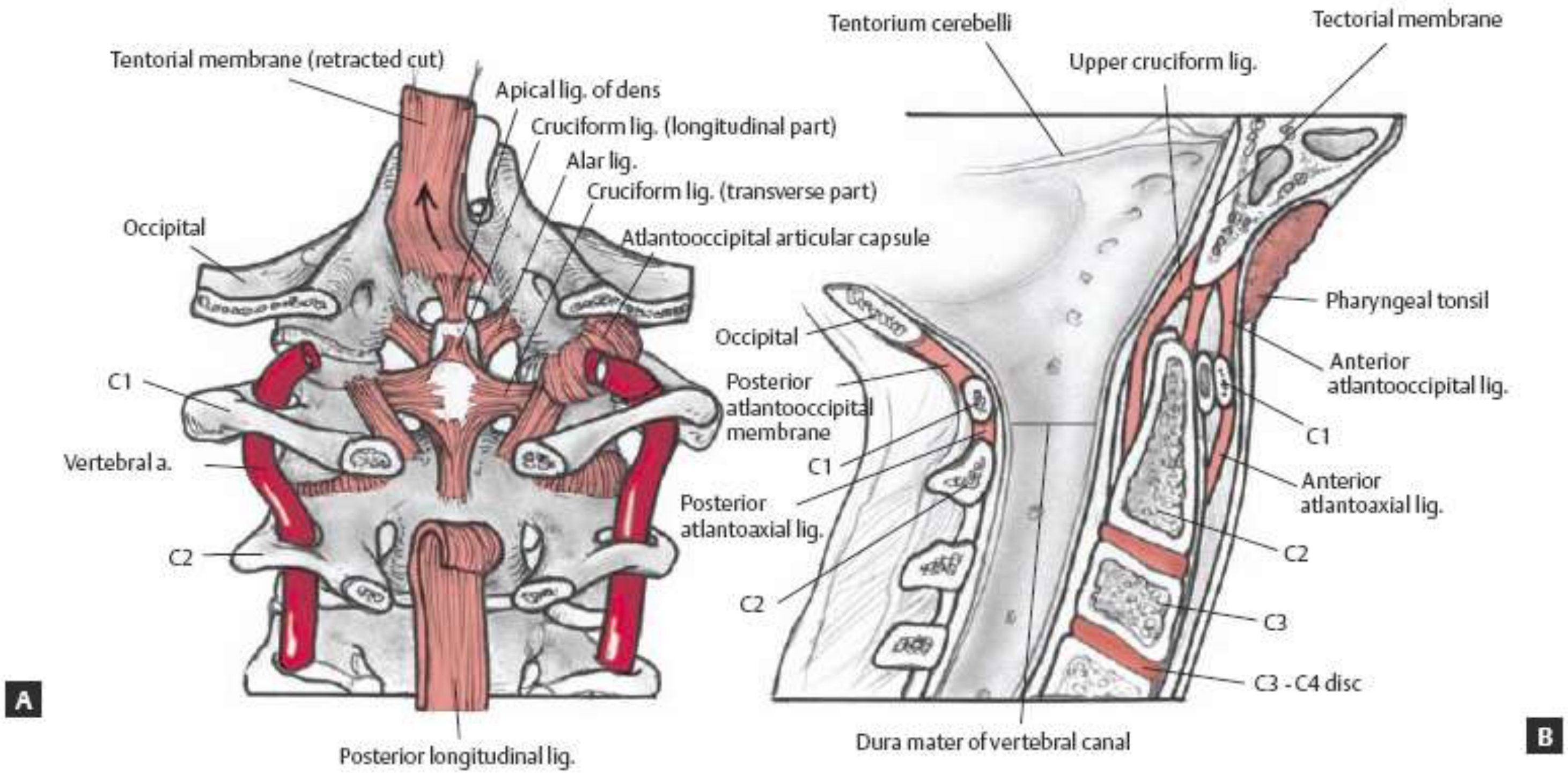

Fig. 2.65 Posteroanterior **(A)** and sagittal **(B)** illustrations showing the ligamentous structures of the skull base and cervical spine, including the alar ligament, cruciform ligament, and atlantooccipital ligaments.

Khanna AJ, ed. MRI for Orthopaedic Surgeons. 2010

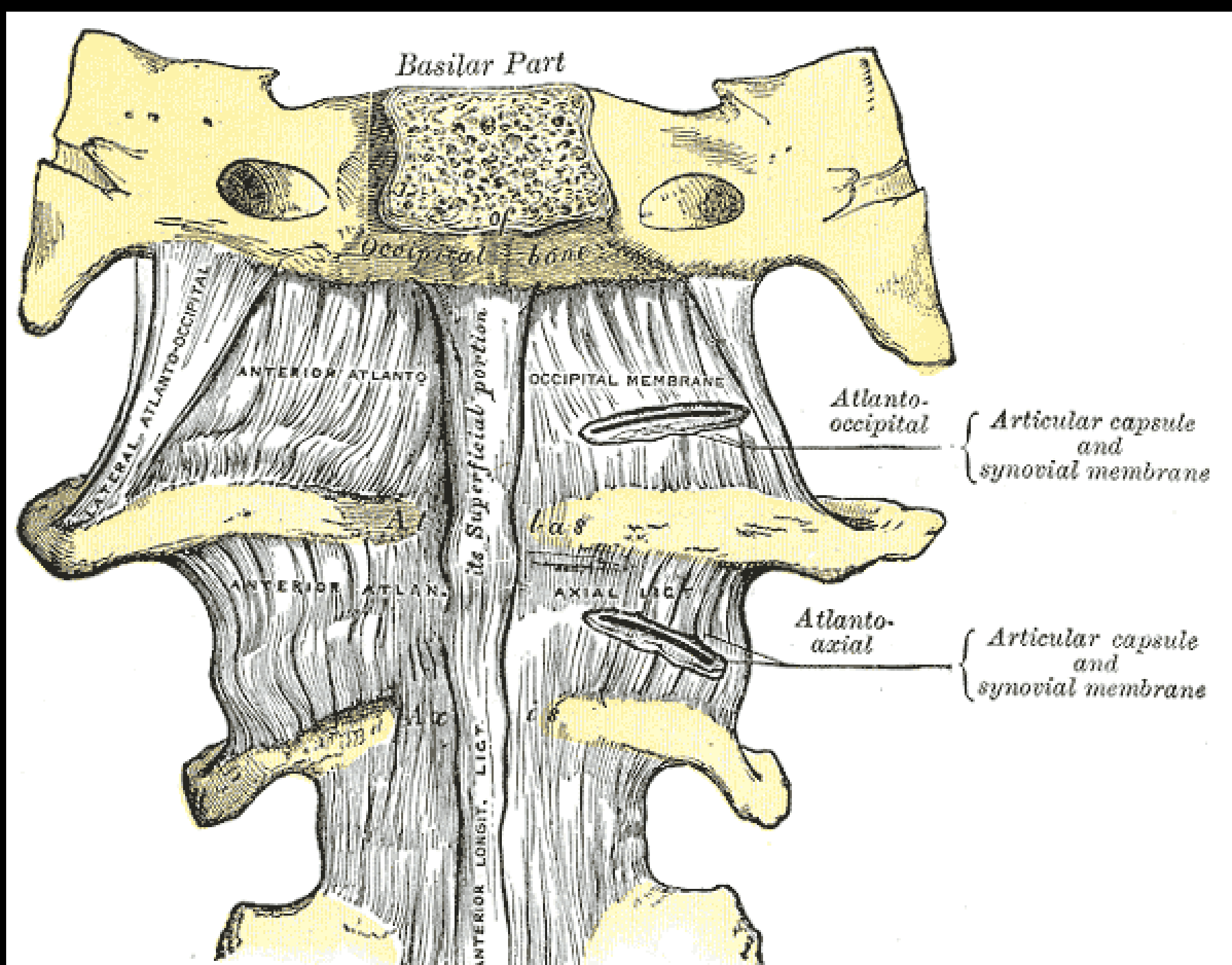
Basilar Part
Occipital bone
LATERAL ATLANTO-OCCIPITAL
ANTERIOR ATLANTO
OCCIPITAL MEMBRANE
its Superficial portion
Atlas
ANTERIOR ATLAN.
AXIAL LIGT.
Axis
ANTERIOR LONGIT. LIGT.
Atlanto-occipital
Articular capsule and synovial membrane
Atlanto-axial
Articular capsule and synovial membrane

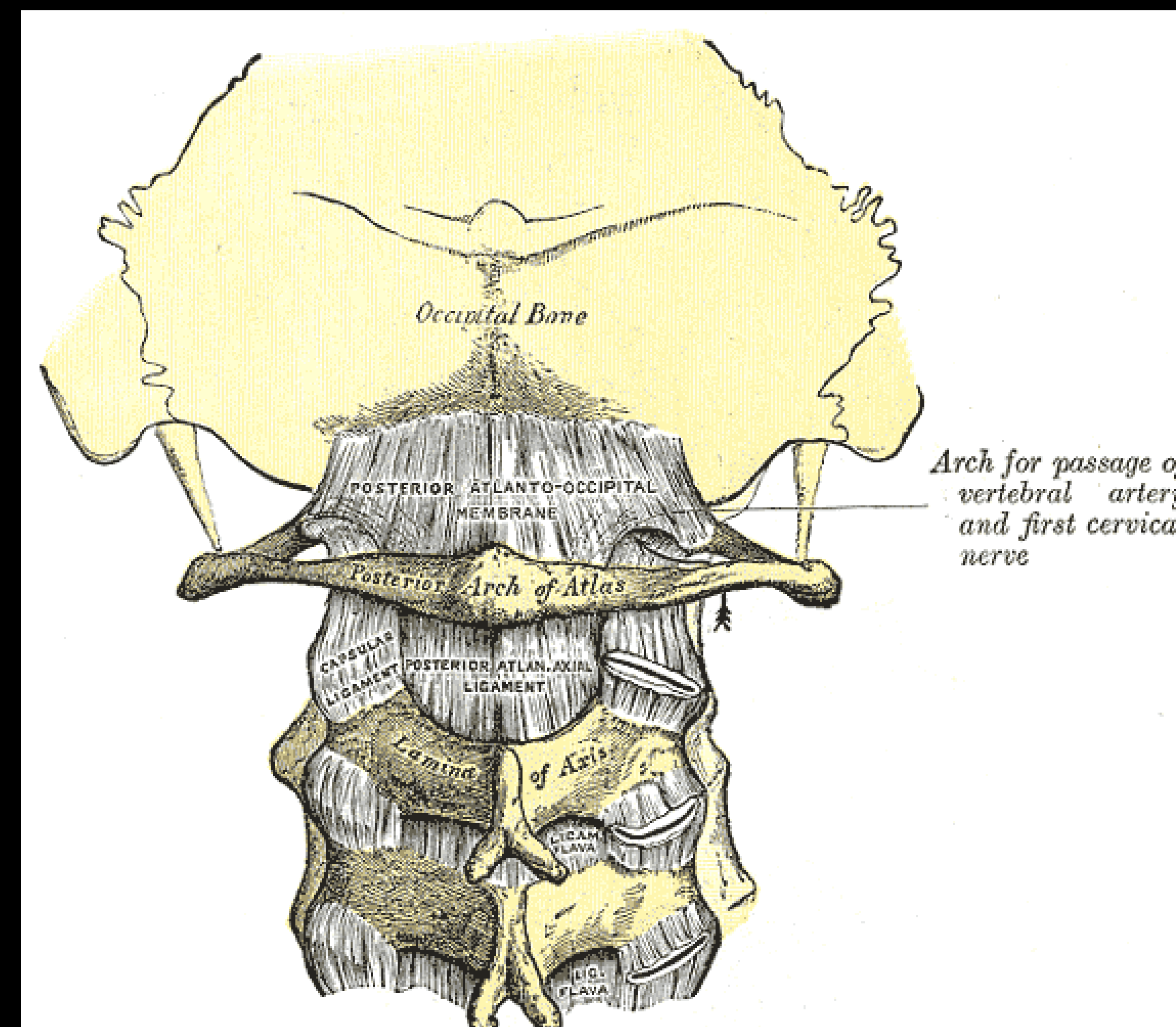
Occipital Bone
POSTERIOR ATLANTO-OCCIPITAL MEMBRANE
Arch for passage of vertebral artery and first cervical nerve
Posterior Arch of Atlas
CAPSULAR LIGAMENT
POSTERIOR ATLAN. AXIAL LIGAMENT
Lamina of Axis
LIGAM. FLAVA
LIG. FLAVA

Ligaments of upper C-spine

- Membrana tectoria
- Alar ligaments
- Transverse ligament
- Apical ligament of dens

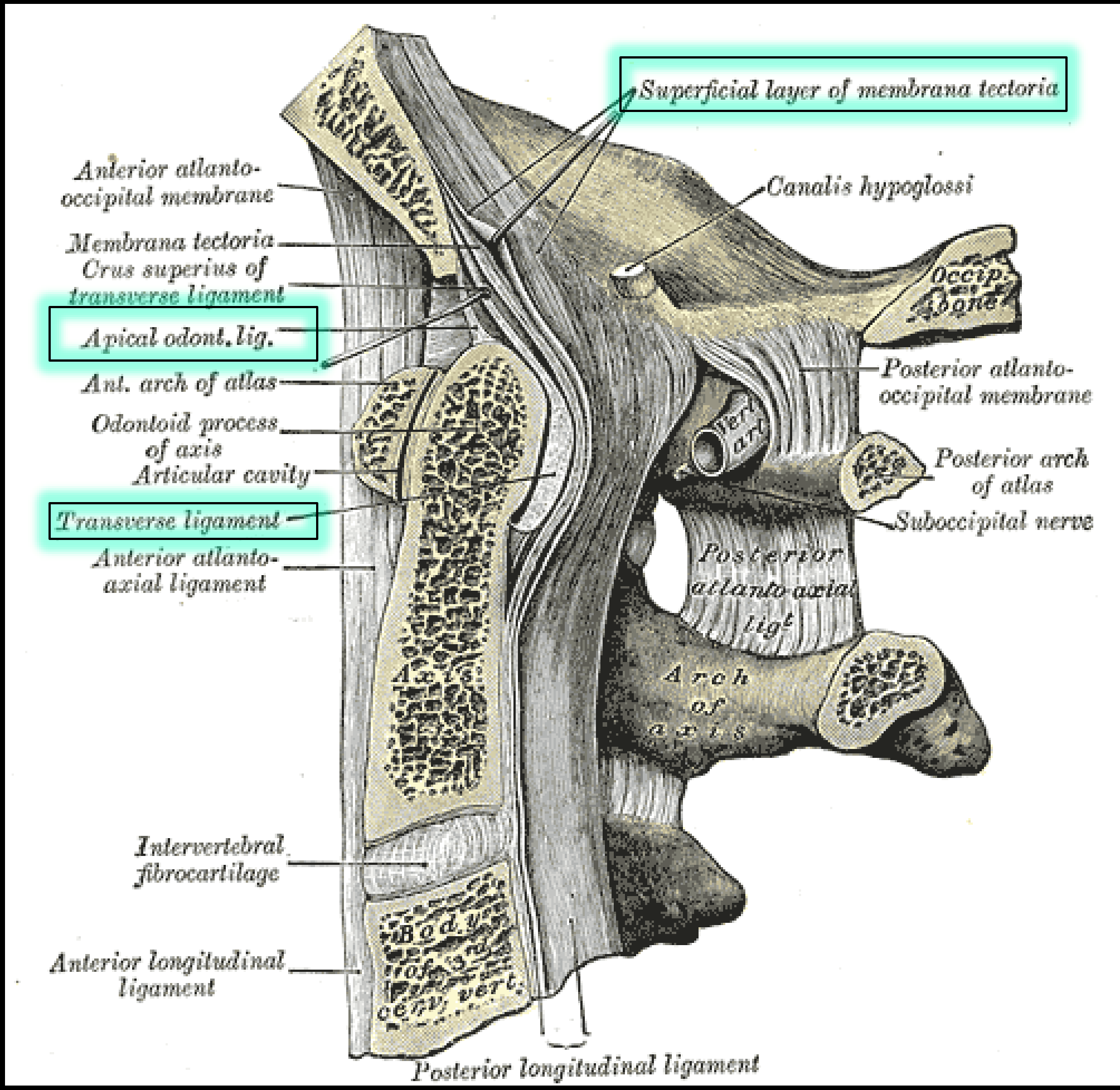

Transverse Ligament

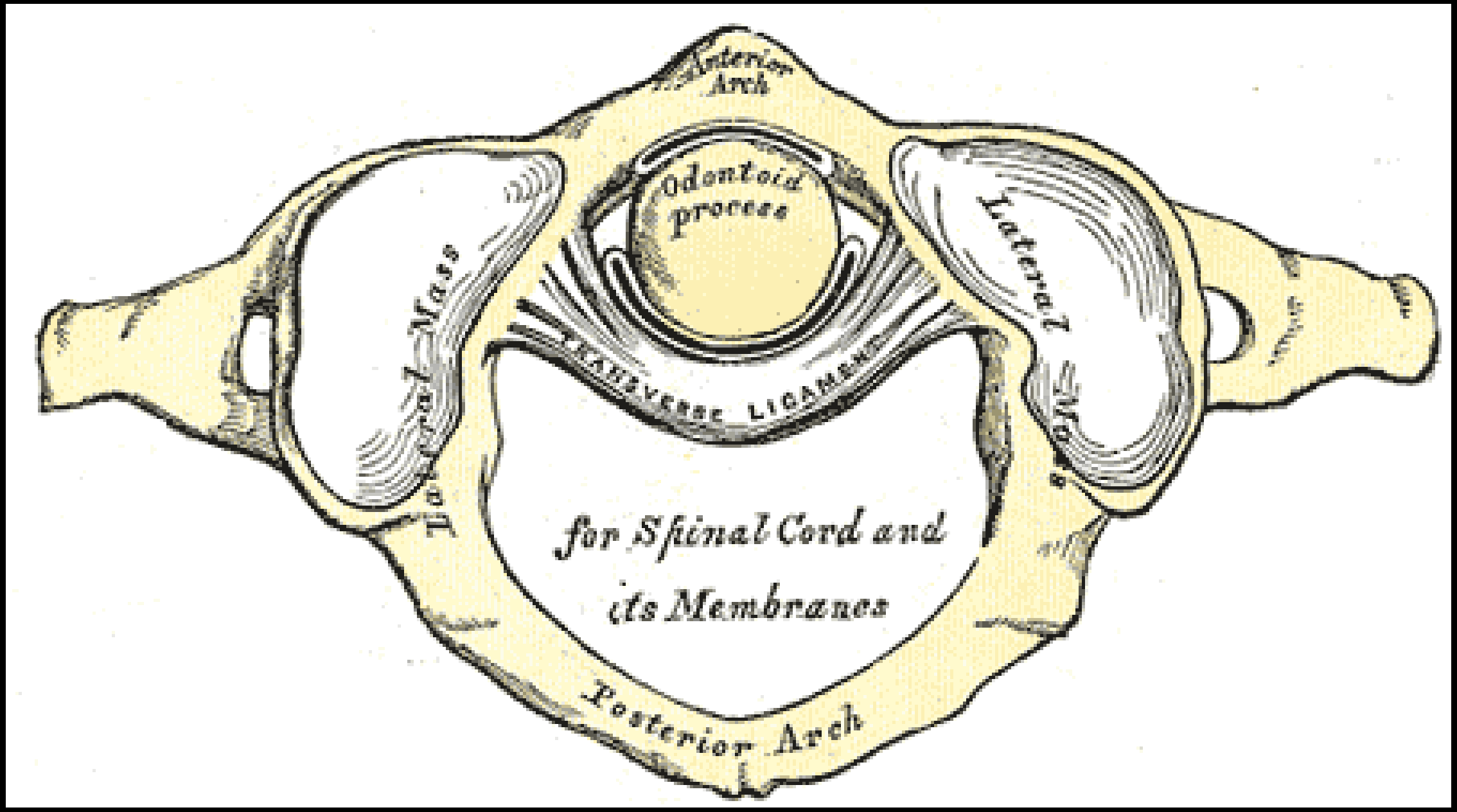

Normal

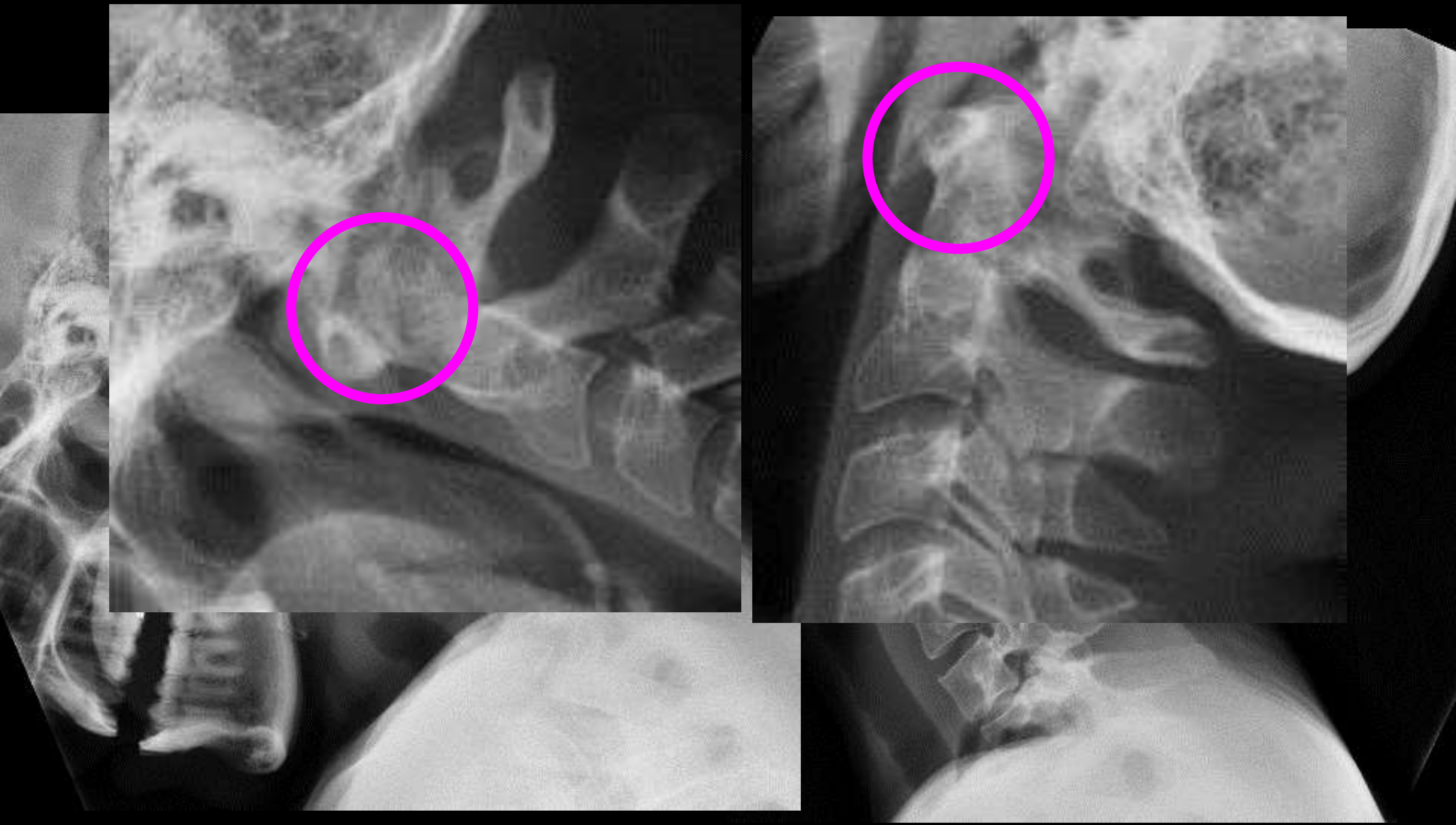

Table 1

Table 1. Active and Passive Normative Range of Motion (°) Using Subjects From a Limited Age Range of ~20 to ~50 Years Old

Reference	Instrument	Tot AR	Rt AR	Lt AR	Tot LB	Rt LB	Lt LB	Tot FE	Flx	Ext	Age Range†	n
Active RoM studies												
Newell[49]‡	Visual estimation	169	84	85	107	54	53	146	73	73	[~18, 40]	48
Sharpe[63]‖		99									Not given	16
Kaufman[32]		138			77			100			[24, 45]	10
Ferlic[18]		140			71			124			[25, 44]	199
Bennett[7]		151	76	75							[18, 24]	50
Buck[8]	Two-arm goniometry	147	73	74							[18, 23]	100
Rosen[60]‡		140			133			76	43	33	[20, 40]	15
Guth[22]‡‖		162	81	81							Dec 2	80
Lind[39]‖	Compass	142									[12, 79]	70
Youdas[71]‡		136	70	66							Dec 3–5	125
Bennett[7]								148	54	93	[18, 24]	50
Alaranta[2]‡‖		150	75	75	76	38	38	122			[35–54]	125
Buck[8]‡								144	67	77	[18, 23]	100
Glanville[21]‡		157	77	80	82	39	43	121	60	61	[20, 40]	10
Fisher[19]	Single inclinometry							134			Dec 3	10
Kuhlman[34]‡		186	93	93	98	49	49	140	69	71	Dec 3	73
Mayer[41]‡		174	88	86							YG	58
O'Driscoll[53]		133			194			116			Dec 3–5	60
Ordway[54]‡								127	48	79	30 [20, 49]	20
Rosen[60]‡		166			108			150	69	81	[20, 40]	15
Youdas[71]‡					85	44	41			75*	Dec 3–5	125
Mayer[41]‡	Dual inclinometry				85	44	41	120	50	70	YG	29
Ordway[54]‡								106	38	68	30 [20, 49]	20
Trott[64]‡	Electromagnetic	145	76	69	86	44	42	118	51	67	Dec 3–5	80
Walmsley[67]		149									[18, 30]	120
Alund[4]‖		153			91			140			32 [24, 58]	10
Dvorak[15]	Potentiometry	175			91			141			[23, 35]	12
Sandler[61]		179			84			139			[27, 32]	5
Fisher[19]								109	46	63	Dec 3	10
Askin[5]‡§								113	50	63	28 [21, 33]	20
Lind[39]‖	Radiography: Occiput to C7				122			129			[12, 79]	70
VanMam[66]								116			YG	10
Sharpe[63]¶§#					36			48	45	50	Not given	16
Ordway[54]‡								107	35	72	30 [20, 49]	20
Penning[56]§¶					80			145			YG	20
Johnson[30]§	C0 to T1							137	69	68	26 [20, 36]	44
Lai[35]‡	3-D: C0–C7	98	49	49							28 [27, 40]	20
Penning[56]‡§**	CT: C0–T1	145	71	74							Dec 3	28
Passive RoM studies												
McClure[44]		143									27 [23, 35]	20
Nilsson[52]	Compass	169									Dec 3–5	<90
McClure[44]						47*			59*		27 [23, 35]	20
Glanville[21]‡	Single inclinometry	192	97	95	126	61	65	153	76	77	[20, 40]	10
Nilsson[52]					110			120			Dec 3–5	<90
Dvorak[15]		175			96			145			Dec 3–5	108
McClure[44]	Potentiometry	155				39*			60*		27 [23, 35]	20
Sandler[61]		190			102			141			[27, 32]	5

* One study did not measure Lt LB and Flx half-cycles; thus, the half-cycle values were excluded from the descriptive statistics.
† Mean and/or [range]. Range for decades is inclusive. When possible, we selected data for all subpopulations within the age range of 20 to 50 years.
‡ Total RoM values were derived by summing mean half-cycle values.
§ Radiographic measurements were summed from segmental RoM values.
‖ Data excluded from Table 2 because the age range was beyond our criterion of 20 to 50 years or subsets of data were not provided.
¶ For lateral bending, n = 5
# The large discrepancy between total FE and the respective half-cycles is likely due to their measurement method.
** This study only measured AR to either the right or left in each subject.
Rt = right; Lt = left; Flx = flexion; Ext = extension; Tot = total; AR = axial rotation; LB = lateral bending; FE = flexion-extension; n = number of subjects per study; CO = occiput; CT = computerized tomography; Dec = decade; YG = younger group.
Note: For some studies, not all motions were investigated. As a result, many cells are empty.

Meta-Analysis of Normative Cervical Motion.

Chen, Jasper; Solinger, Alan; Poncet, Jacques; Lantz, Charles; DC, PhD

Spine. 24(15):1571, August 1, 1999.

Table 1 . Active and Passive Normative Range of Motion ([degrees]) Using Subjects From a Limited Age Range of \f20 to \f50 Years Old* One study did not measure Lt LB and Flx half-cycles; thus, the half-cycle values were excluded from the descriptive statistics.+ Mean and/or [range]. Range for decades is inclusive. When possible, we selected data for all subpopulations within the age range of 20 to 50 years.++ Total RoM values were derived by summing mean half-cycle values.[S] Radiographic measurements were summed from segmental RoM values.[//] Data excluded from Table 2 because the age range was beyond our criterion of 20 to 50 years or subsets of data were not provided.[P] For lateral bending, n = 5# The large discrepancy between total FE and the respective half-cycles is likely due to their measurement method.** This study only measured AR to either the right or left in each subject.Rt = right; Lt = left; Flx = flexion; Ext = extension; Tot = total; AR = axial rotation; LB = lateral bending; FE = flexion-extension; n = number of subjects per study; CO = occiput; CT = computerized tomography; Dec = decade; YG = younger group.Note: For some studies, not all motions were investigated. As a result, many cells are empty.

Table 2

Table 2. Overall Means (°) and Standard Deviations (SD°) Derived From Table 1 and Organized by Technology

		Rotation			Lateral Bending			Flexion-Extension		
RoM Studies	n§	Total	Right	Left	Total	Right	Left	Total	Flexion	Extension
Active normative RoM studies										
Visual estimation	3	149 (17)	84	85	85 (18)	54	53	119 (21)	73	73
Two-arm goniometry	3	146 (6)	75 (2)	75 (1)	133			76	43	33
Compass	1	136	70	66						
Single inclinometry†	9	171 (12)	86 (8)	86 (7)	93 (12)	44 (5)	44 (4)	138 (11)	61 (9)	77 (11)
Dual inclinometry	1				85	44	41	121	51	70
Electromagnetic	3	147 (3)	76	69	86	44	42	112 (8)	45 (9)	68 (1)
Potentiometry	2	177 (3)			88 (5)			140 (1)		
Radiography	8	122 (33)	60 (16)	62 (18)	80			121 (16)	50 (14)	67 (4)
Overall mean (SD) for technologies*	25‖	151 (23)	73 (11)	71 (11)	86 (5)	44 (0)	42 (2)	126 (12)	52 (7)	71 (5)
Largest difference between technologies‡		55	26	24	78	10	12	64	30	44
Passive normative RoM studies										
Compass	2	156 (18)								
Single inclinometry	2	192	97	95	118 (12)	61	65	137 (23)	76	77
Potentiometry	3	173 (18)			99 (4)			143 (3)		
Overall mean for technologies	6‖	174 (18)			109 (13)			140 (4)		

* Visual estimation and two-arm goniometry were excluded because of validity issues. Inclusion of these technologies would give the following total, right/flexion and left/extension RoM means and (standard deviations) for rotation: 150° (19°), 75° (10°), 74° (10°); lateral bending: 93° (18°), 47° (5°), 45° (5°); and flexion-extension: 119° (21°), 54°, (11°), 65° (16°).
† Data from O'Driscoll et al[52] was excluded because data collection did not appear to isolate cervical spine motion. Overall single inclinometry means for total active RoM would be 163° for AR, 113° for LB, and 135° for FE, if their data were included.
‡ Standard deviation based on estimates of RoM within each category.
§ Number of studies reporting RoM by technology.
‖ Total number of studies from Table 1 to create Table 2; Some studies report on more than one technology so this number is less than the total of the numbers in the column above.
RoM = range of motion.

Meta-Analysis of Normative Cervical Motion.
Chen, Jasper; Solinger, Alan; Poncet, Jacques; Lantz, Charles; DC, PhD

Spine. 24(15):1571, August 1, 1999.

Table 2 . Overall Means ([degrees]) and Standard Deviations (SD[degrees]) Derived From Table 1 and Organized by Technology* Visual estimation and two-arm goniometry were excluded because of validity issues. Inclusion of these technologies would give the following total, right/flexion and left/extension RoM means and (standard deviations) for rotation: 150[degrees] (19[degrees]), 75[degrees] (10[degrees]), 74[degrees] (10[degrees]); lateral bending: 93[degrees] (18[degrees]), 47[degrees] (5[degrees]), 45[degrees] (5[degrees]); and flexion-extension: 119[degrees] (21[degrees]), 54[degrees], (11[degrees]), 65[degrees] (16[degrees]).+ Data from O'Driscoll et al 53 was excluded because data collection did not appear to isolate cervical spine motion. Overall single inclinometry means for total active RoM would be 163[degrees] for AR, 113[degrees] for LB, and 135[degrees] for FE, if their data were included.++ Standard deviation based on estimates of RoM within each category.[S] Number of studies reporting RoM by technology.[//] Total number of studies from Table 1 to create Table 2; Some studies report on more than one technology so this number is less than the total of the numbers in the column above.RoM = range of motion.

Ligaments of upper C-spine

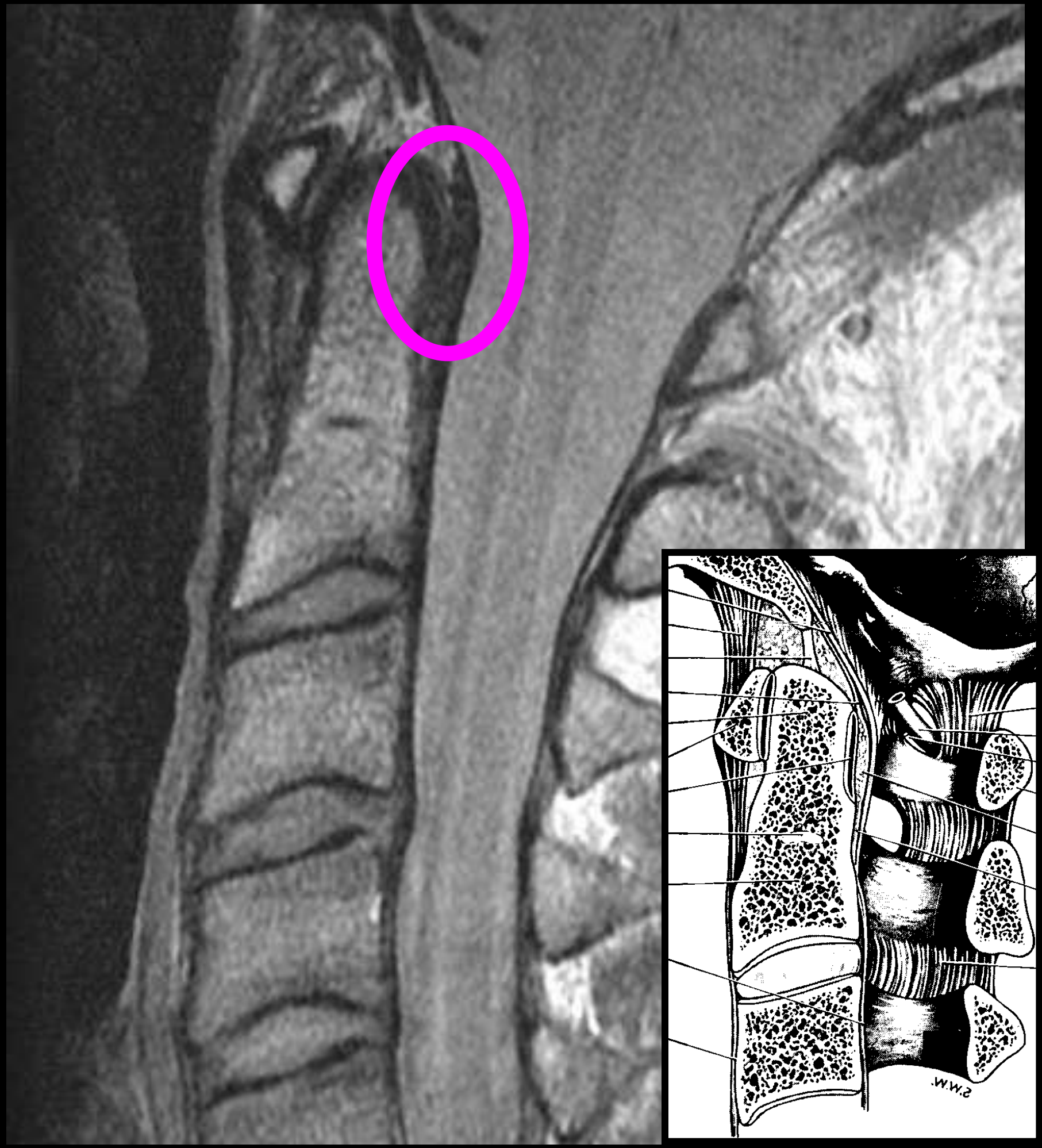

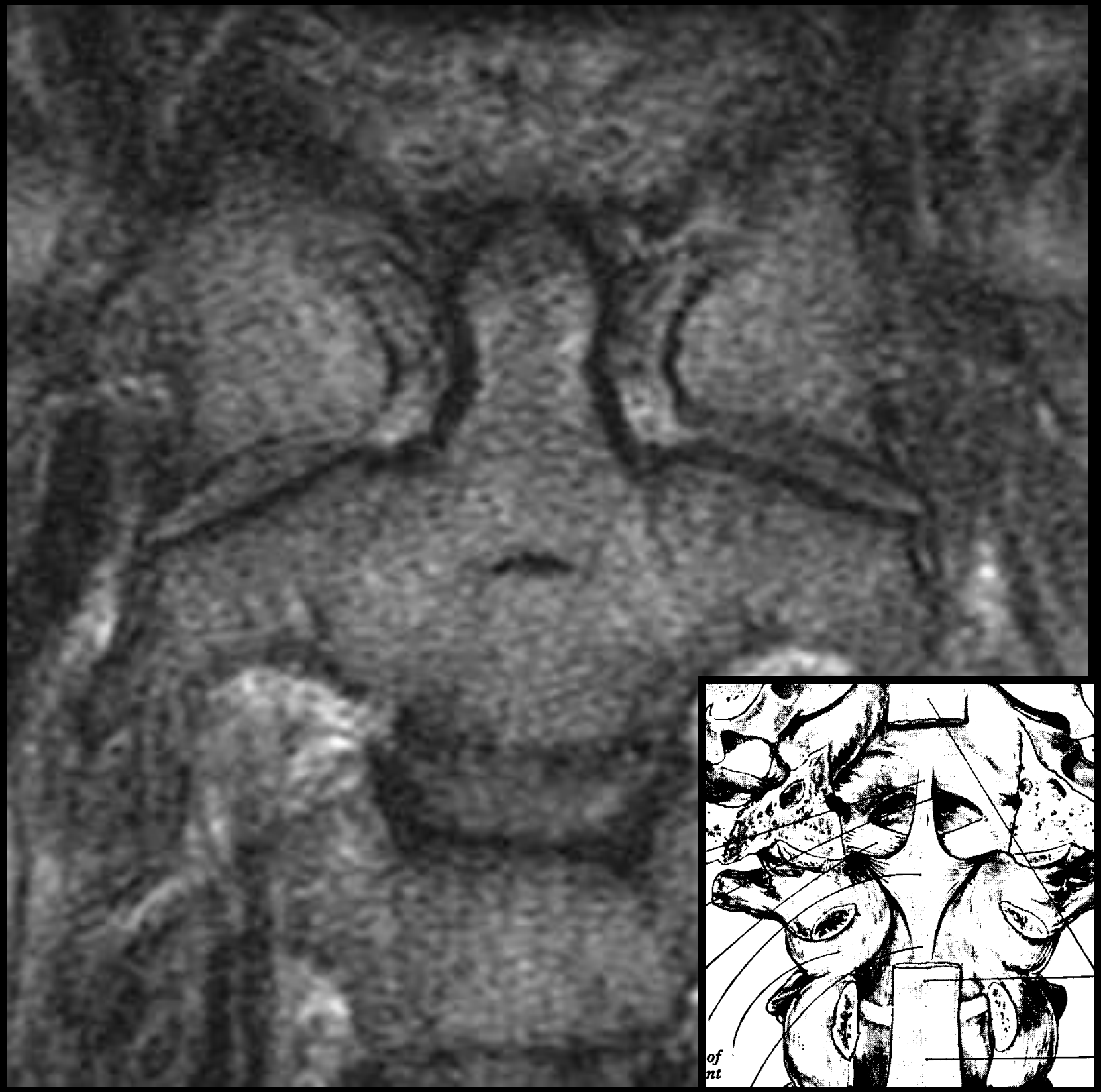


ALAR
ALAR

Ligaments of Upper Cervical Spine

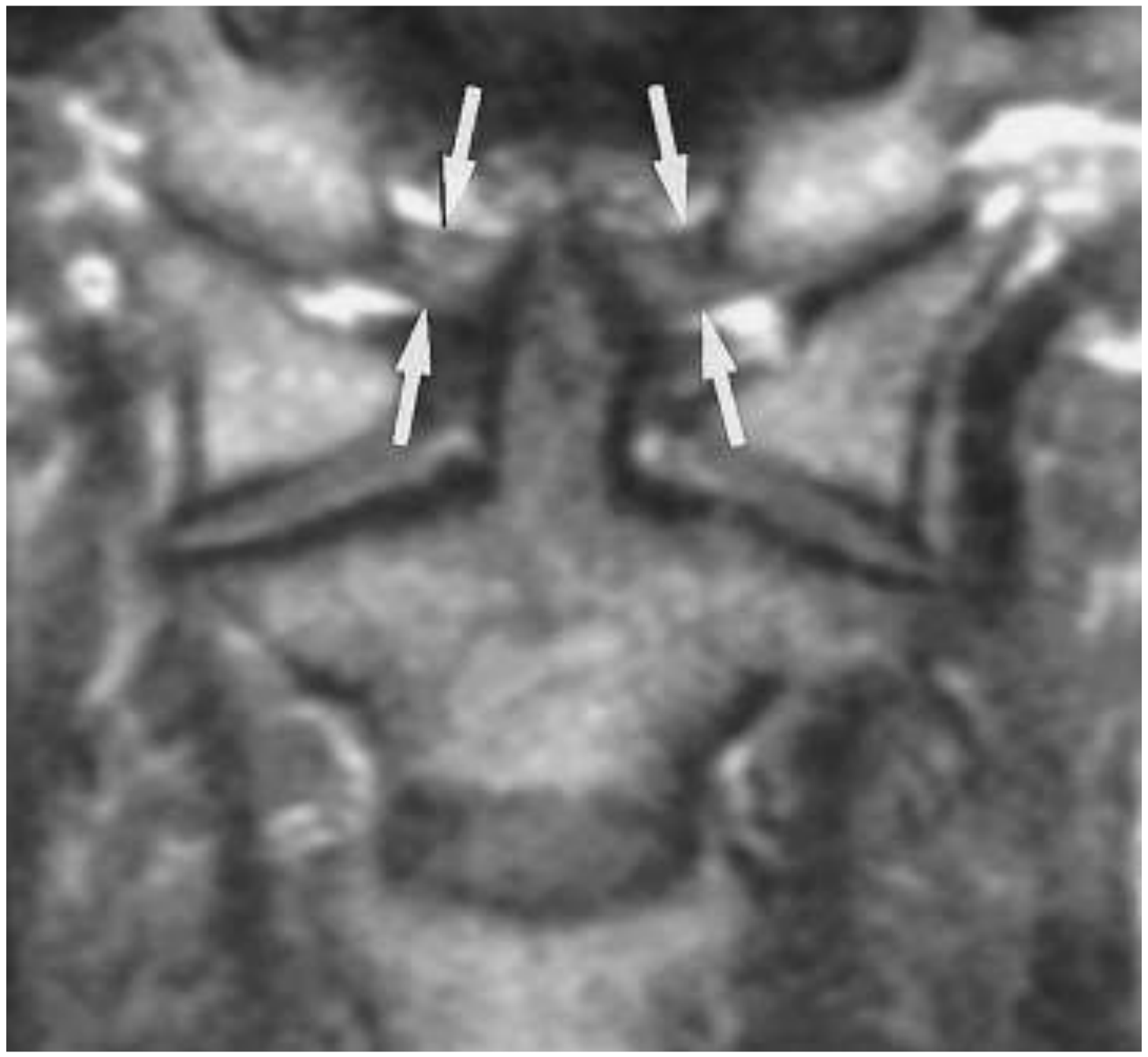

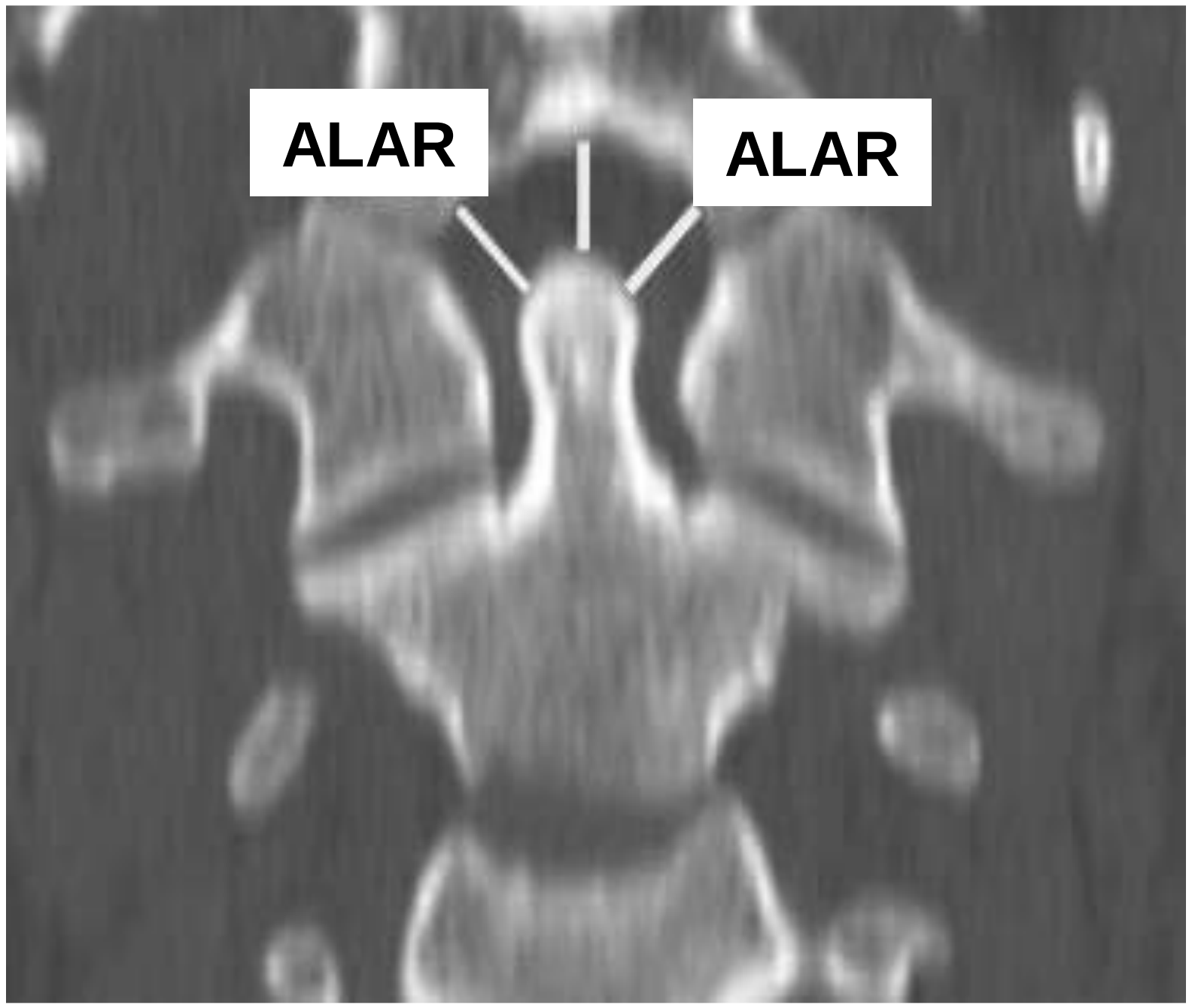

- Membrana tectoria
- Alar ligaments
- Transverse ligament
- Apical ligament of dens

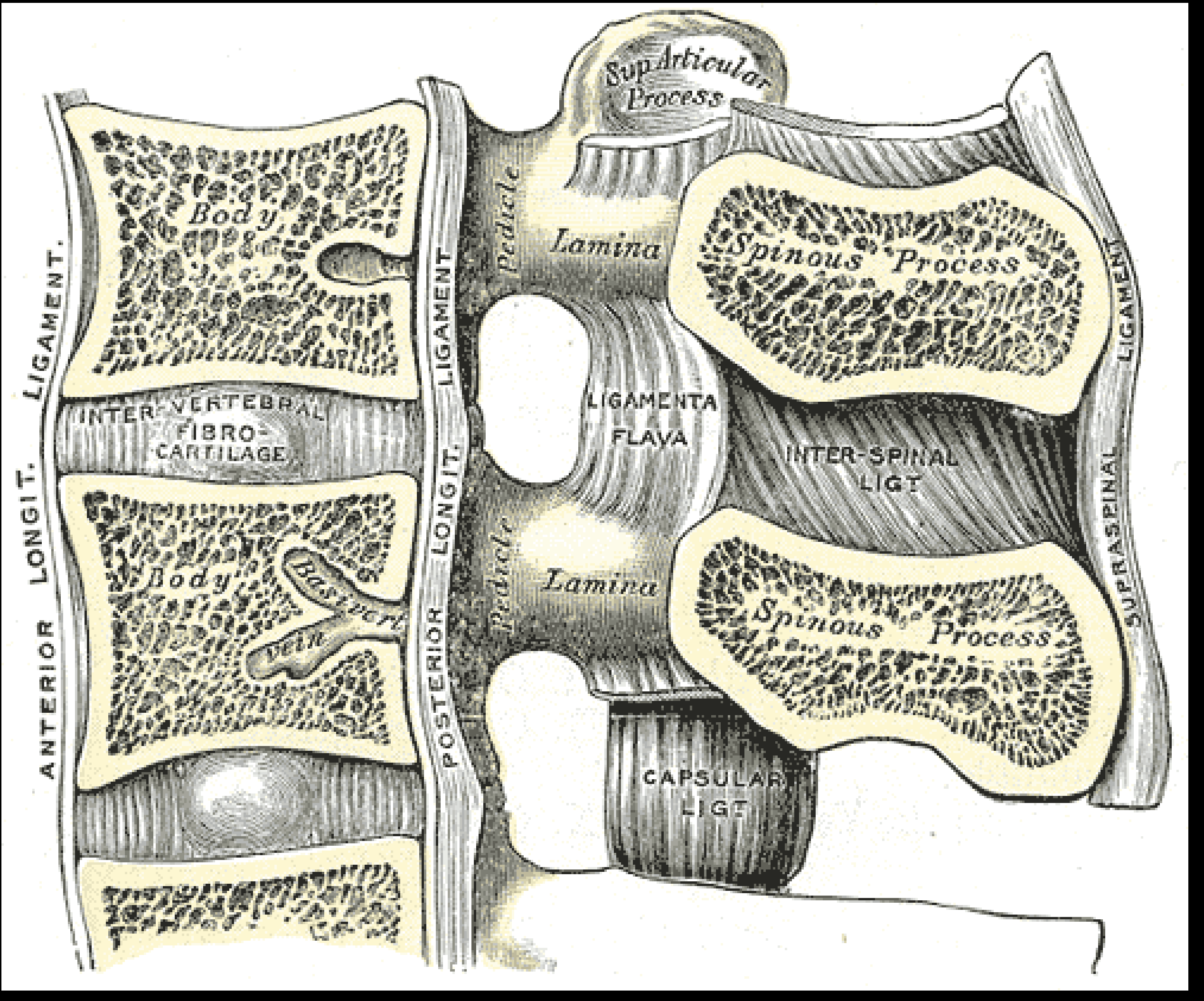

Sup. Articular Process
Body
ANTERIOR LONGIT. LIGAMENT.
POSTERIOR LONGIT. LIGAMENT
Pedicle
Lamina
Spinous Process
INTER-VERTEBRAL FIBRO-CARTILAGE
LIGAMENTA FLAVA
INTER-SPINAL LIGT
SUPRASPINAL LIGAMENT
Body
Basi-vert. vein
Pedicle
Lamina
Spinous Process
CAPSULAR LIGT

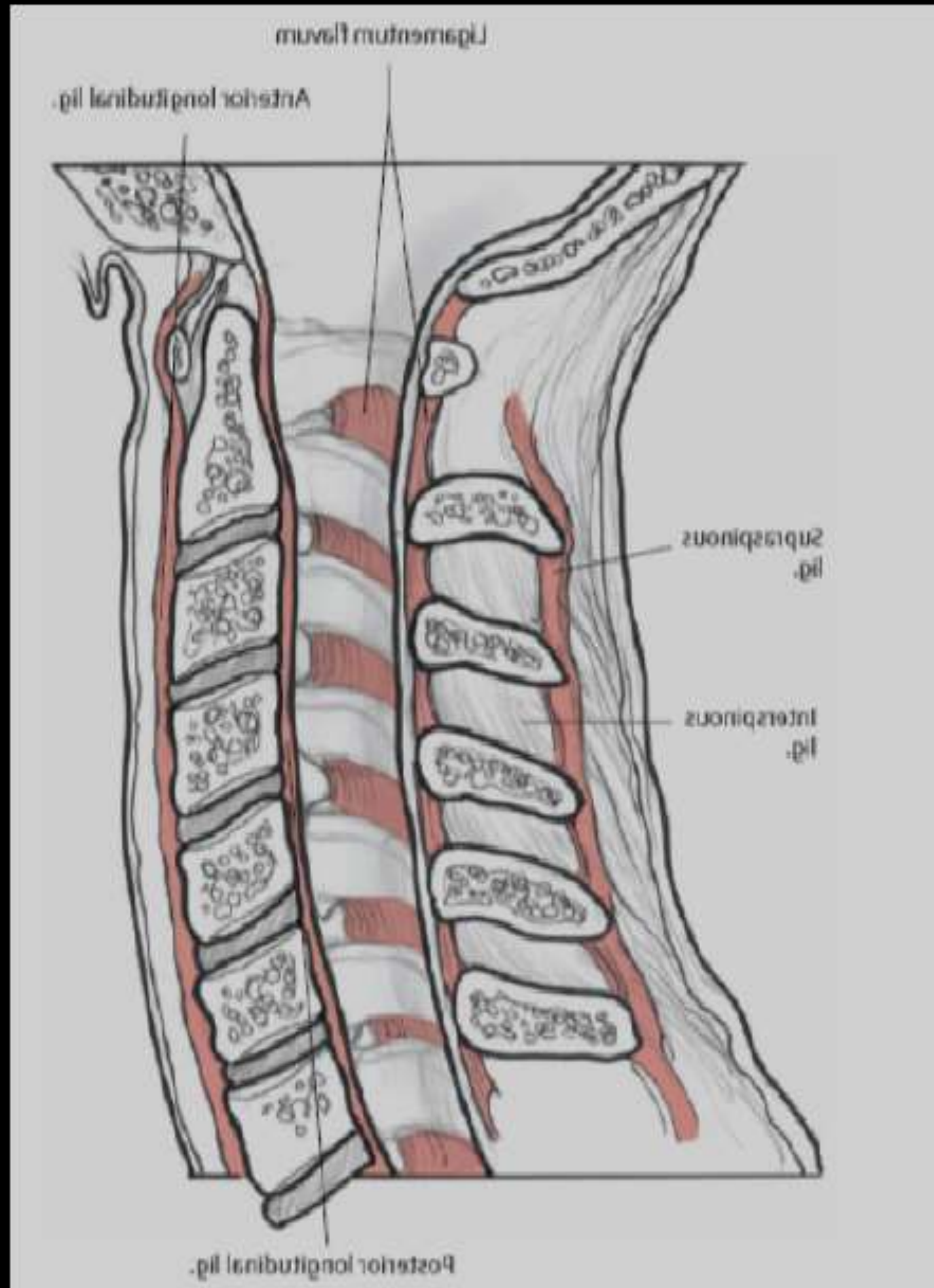

Khanna AJ, ed. MRI for Orthopaedic Surgeons. 2010

Anterior Longitudinal Ligament

From ant. margin of foramen magnum to S1.

Strongly adherent to margins of vertebral bones and loosely attached to discs.

Deep fibers span one intervertebral articulation, superf. fibers span up to 4 articulations.

Narrow in C-spine and broad at L-spine.

Low signal on MRI blends with peripheral portion of annulus fibrosus and cortical bone.

Ant. longitud. Ligament

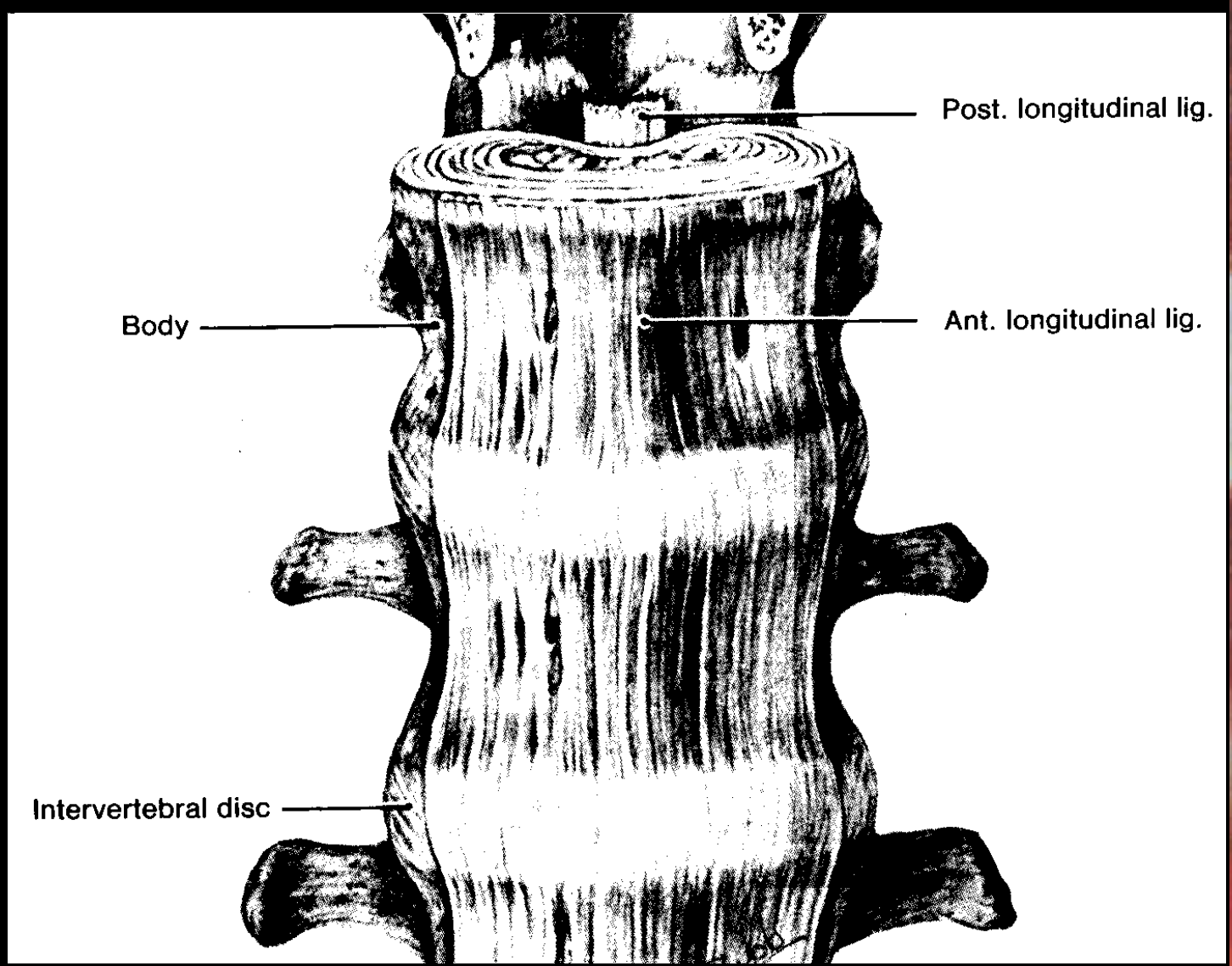

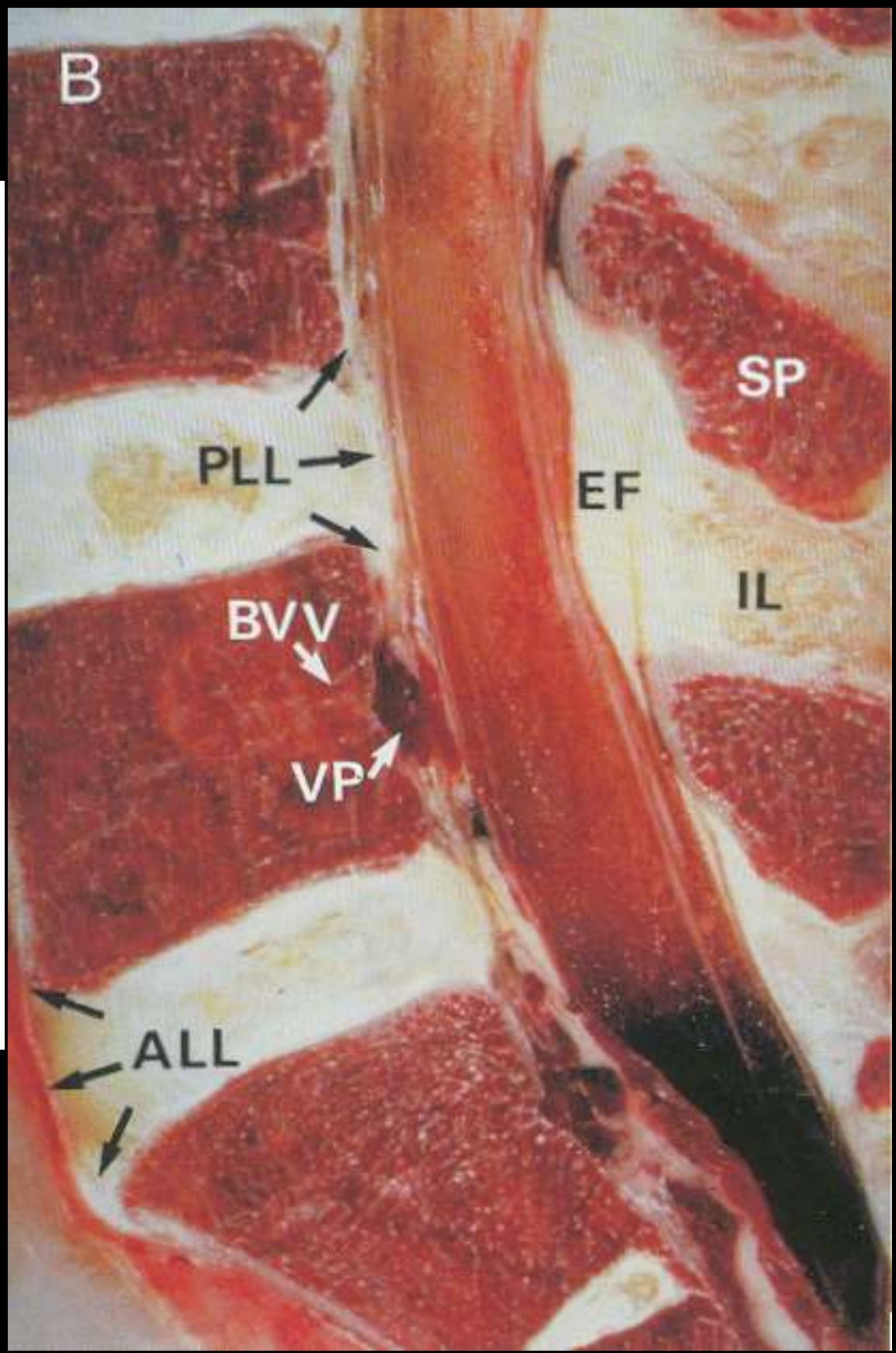

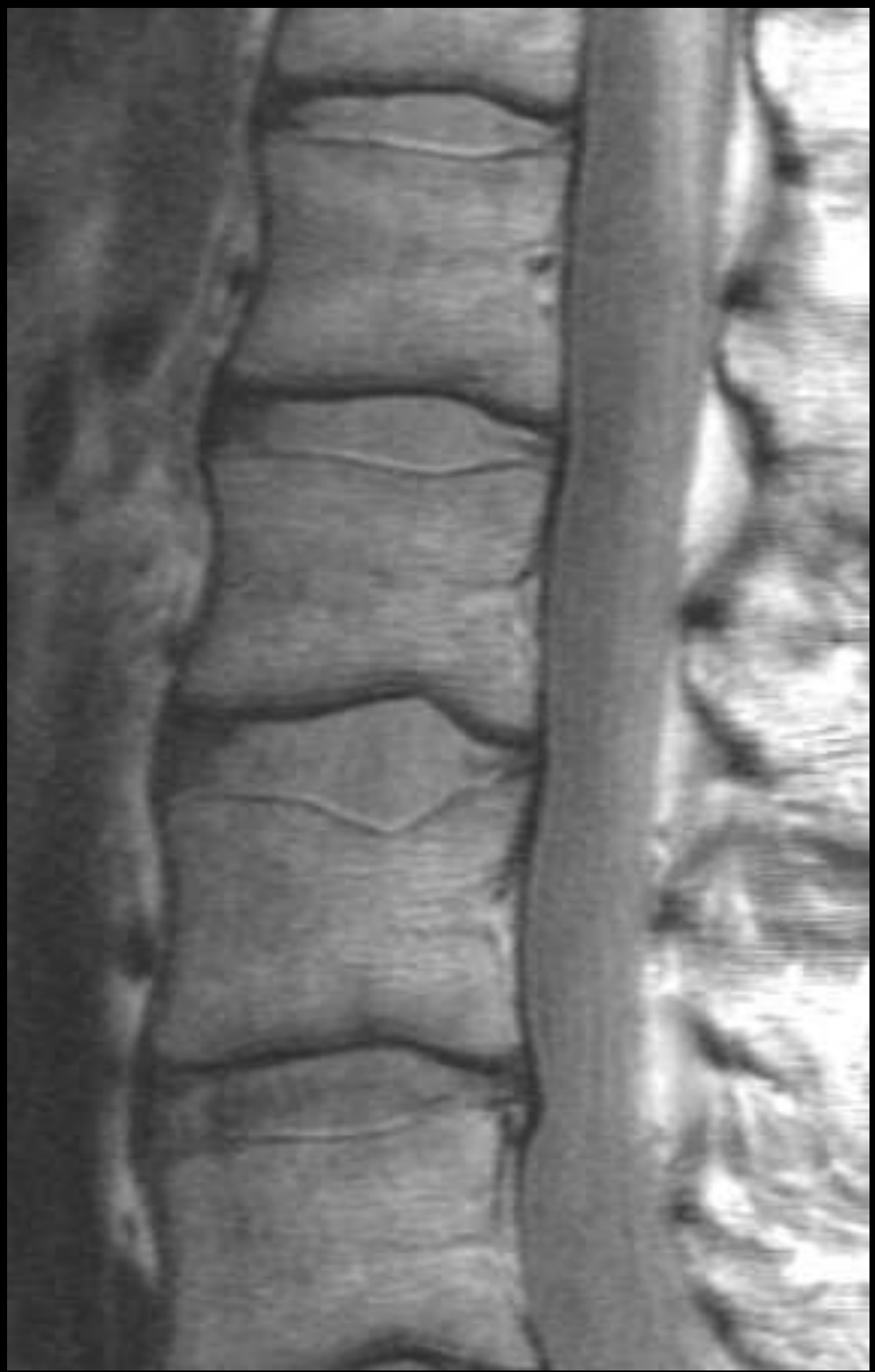

Posterior Longitudinal Ligament

- In anterior portion of the vertebral canal
- From the body of the axis to the sacrum
- Attached to intervertebral discs and margins of adjacent vertebral bodies. No attachment at center of vertebral bodies (basivertebral vein !)
- Superficial fibers bridge 3-4 bodies, deep fibers extend between adjacent vertebra.
- Low signal on T1 and T2 weighted images.

Posterior longitudinal Ligament

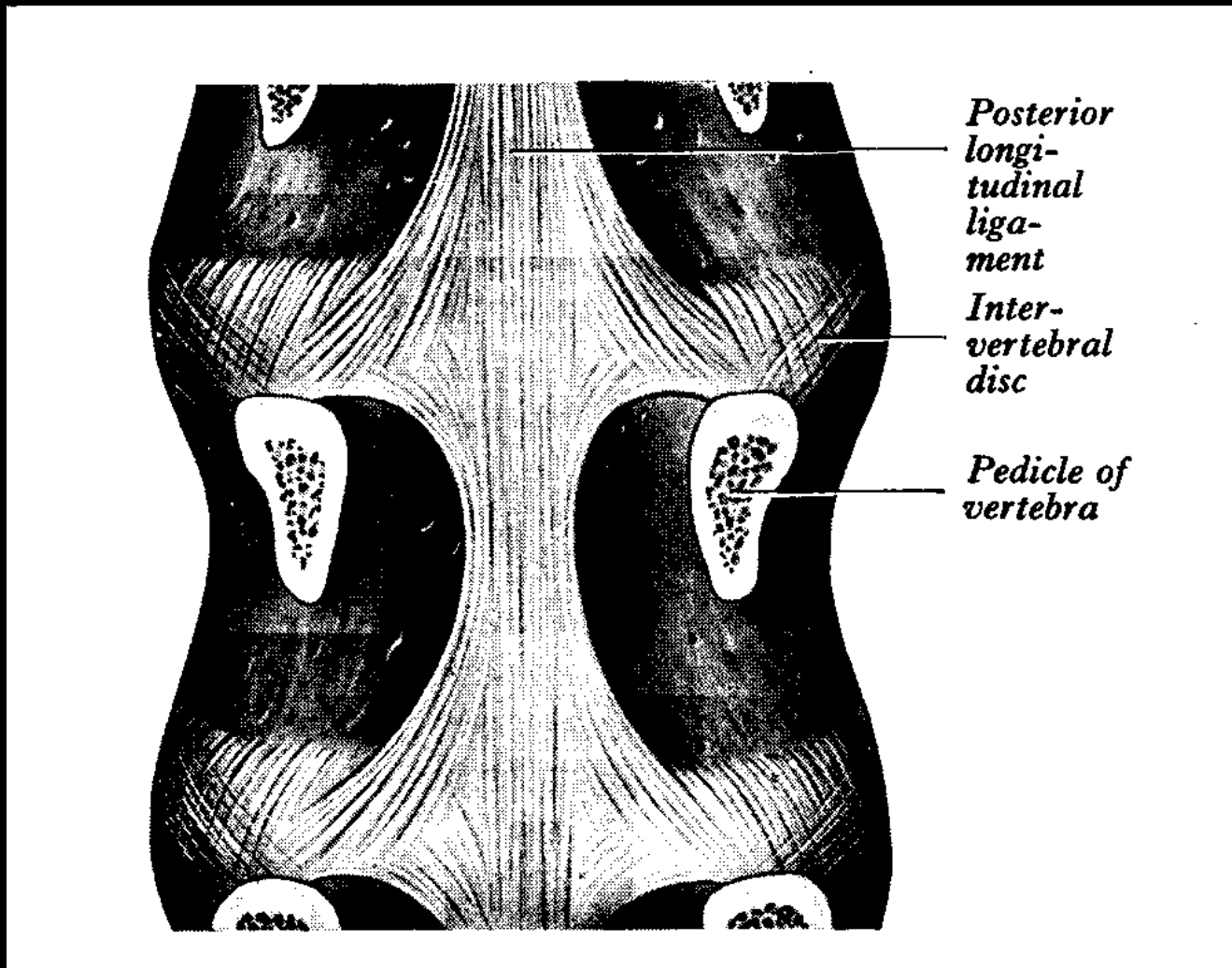

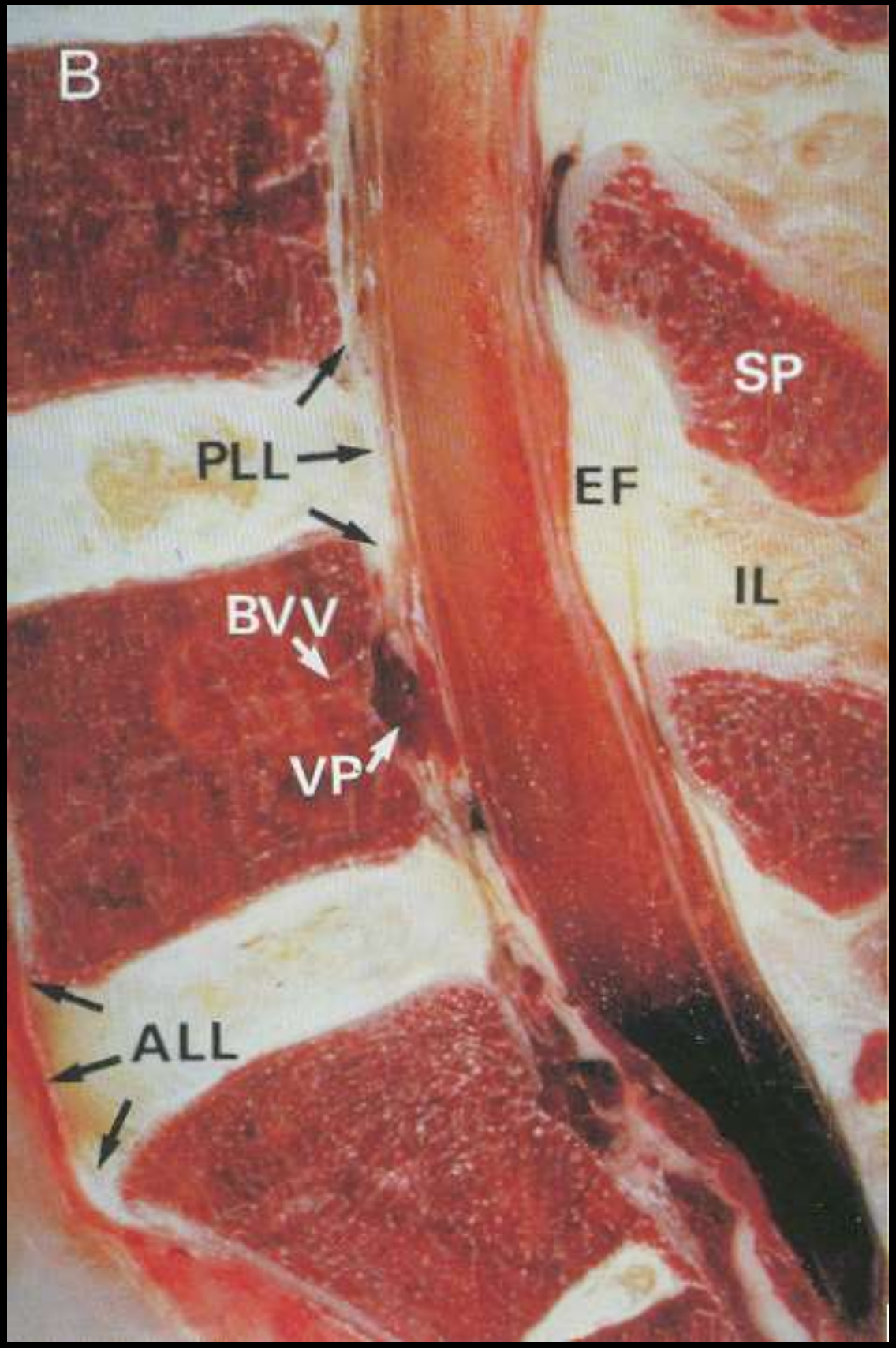

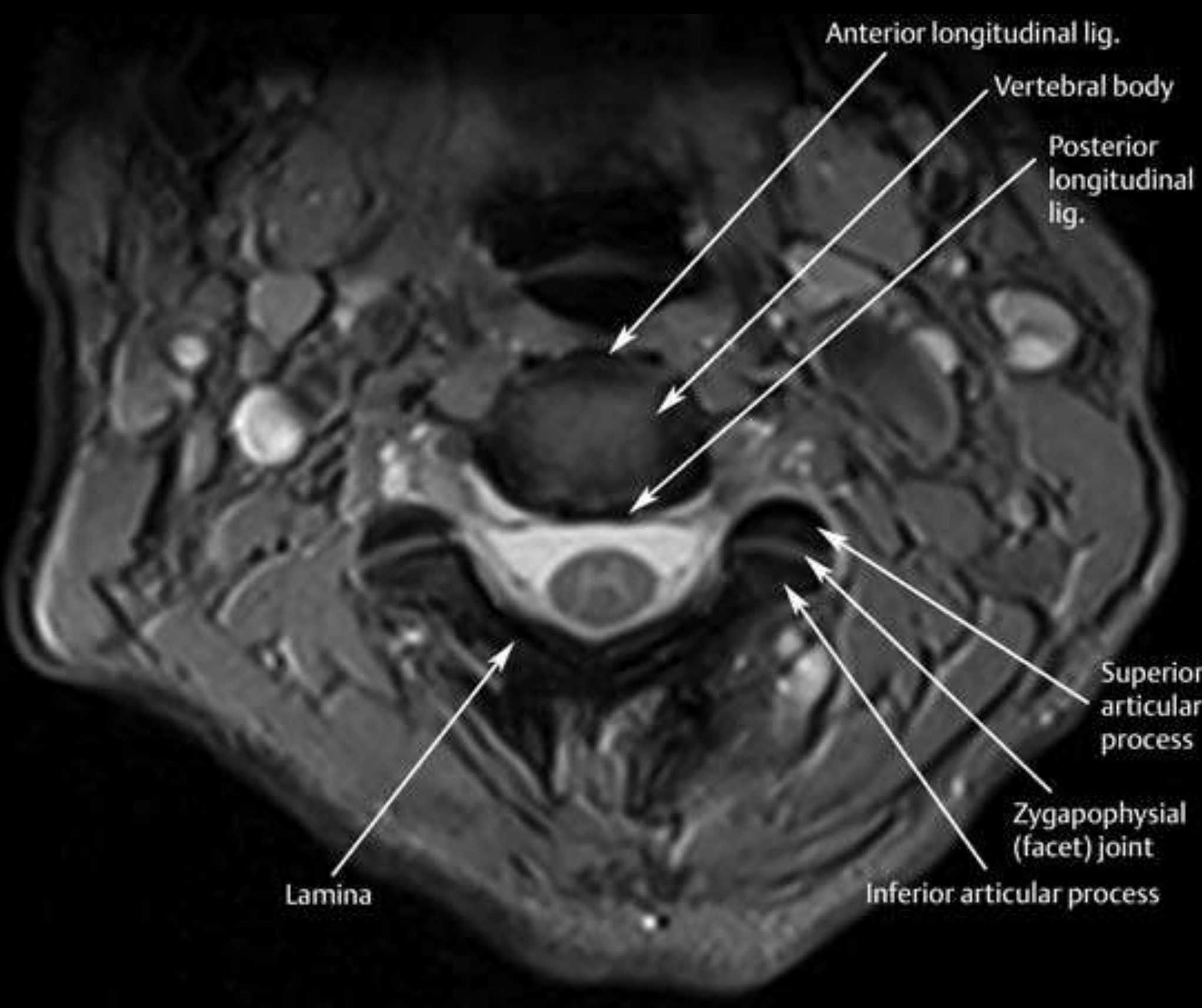

Khanna AJ, ed. MRI for Orthopaedic Surgeons. 2010

Ligamenta flava

- Connect laminae of adjacent vertebrae
- Blend with capsules of facet joints
- Thickness: cervical (1.5mm), lumbar (4-6mm).
- Heterogeneous signal may be due to outpouchings of facet joint capsules (Radiology 177:415-420)
- May calcify and lead to a bony spur in the neural foramen (Radiology 160:153-154) !

Ligamenta flava

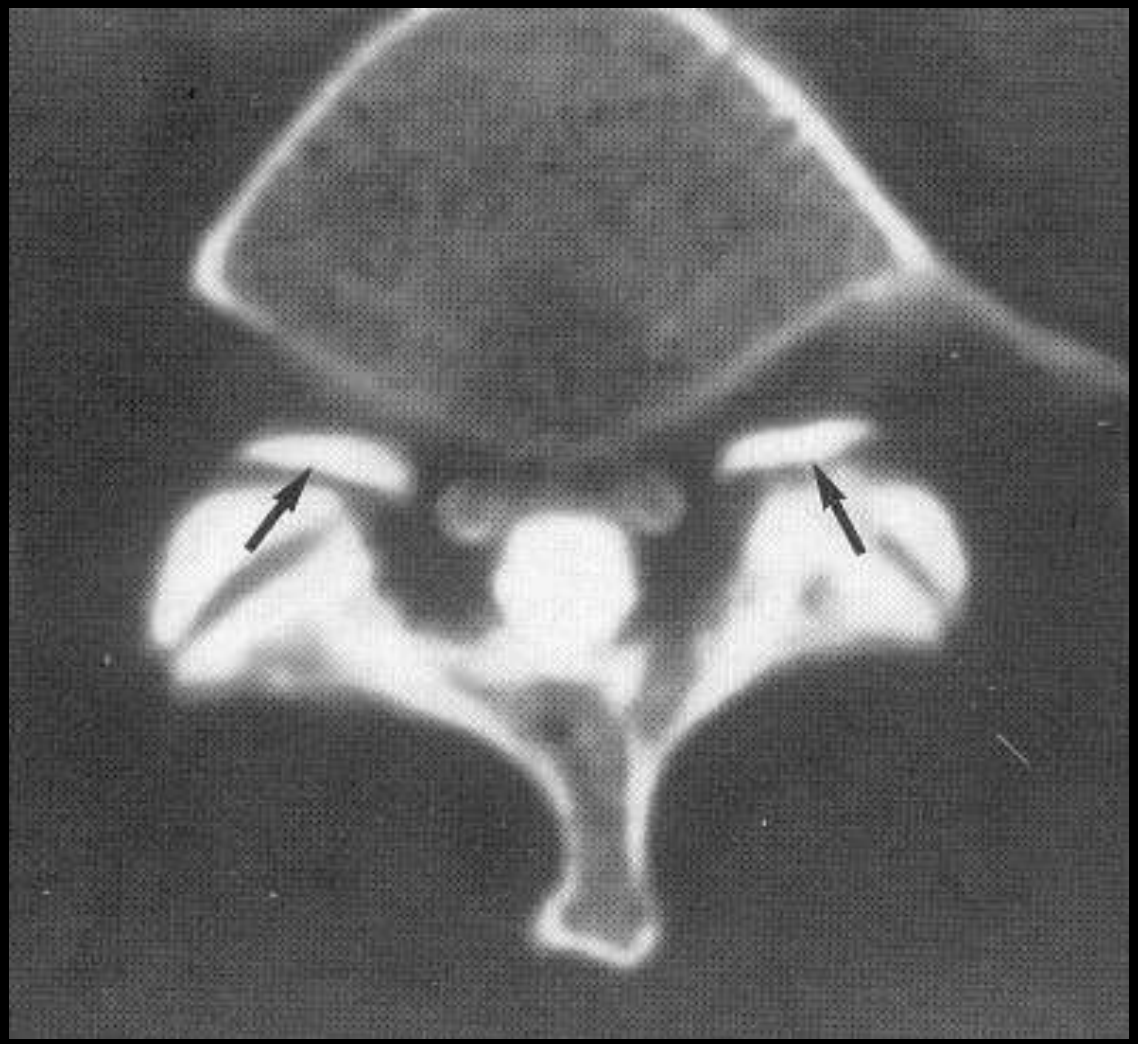

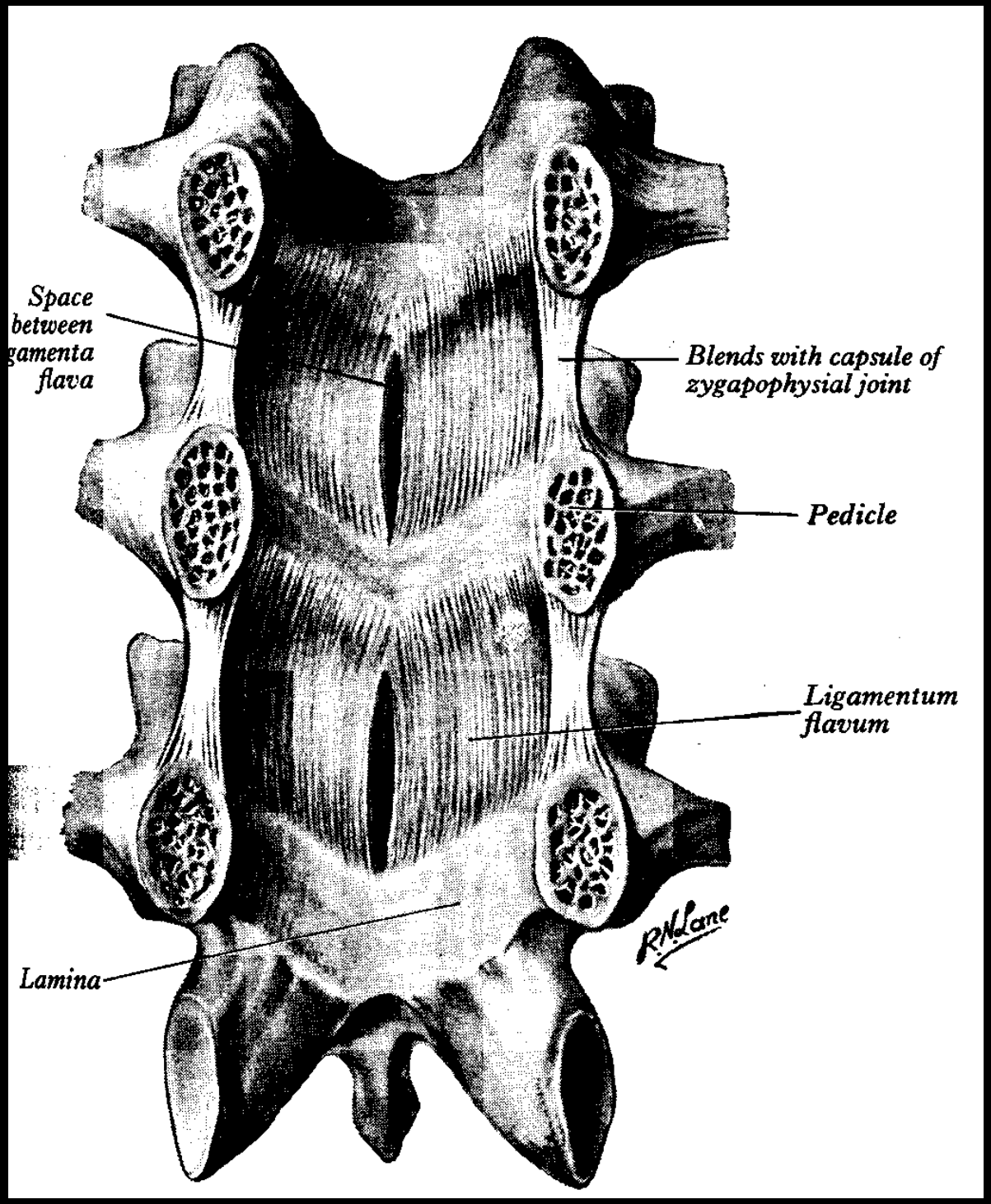

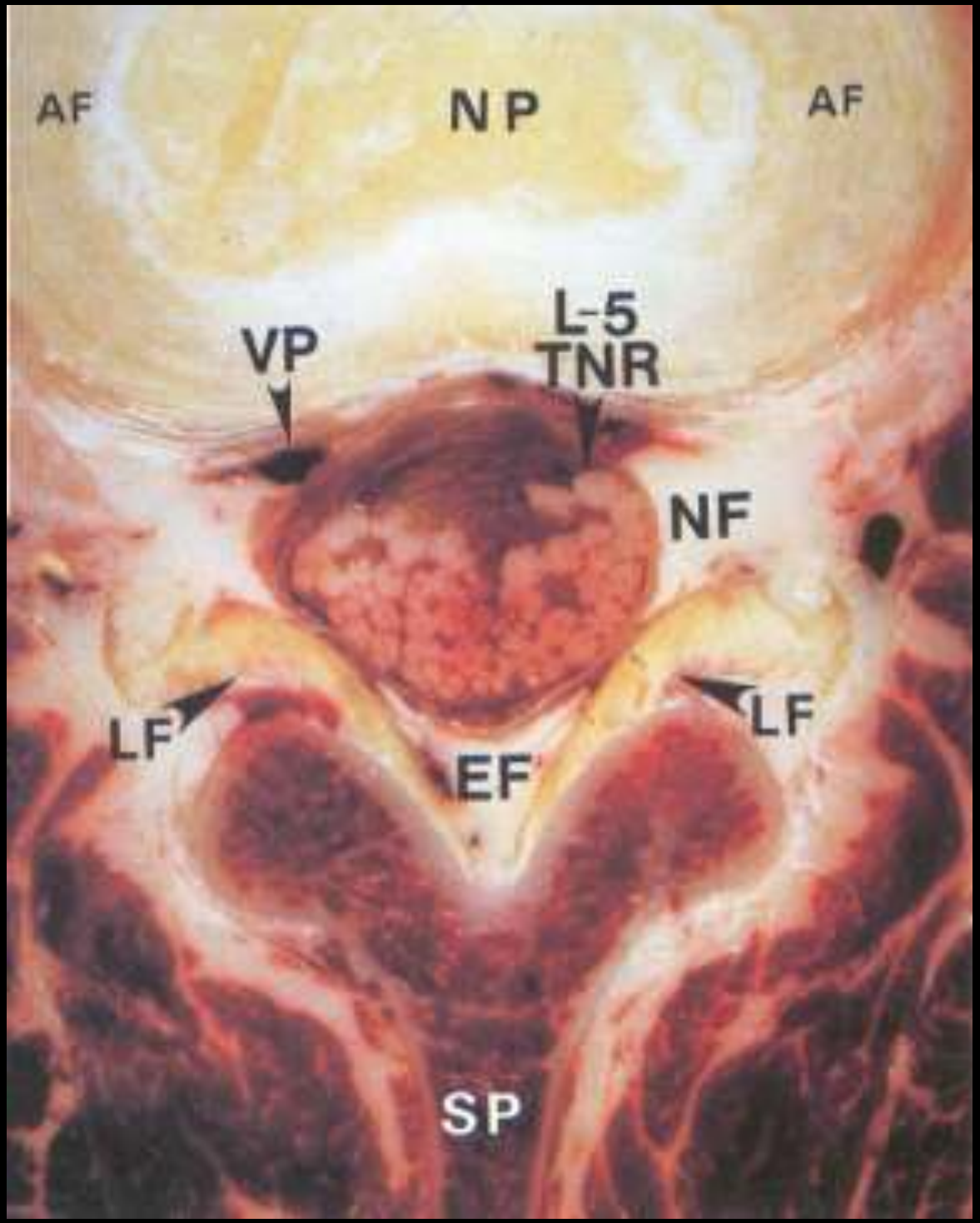

Contents

Bones

Joints

Ligaments

Muscles/tendons

Spinal Canal: Epidural/Intradural

Neural Canals/Neuroforamina

Neural Elements

Vascular Anatomy

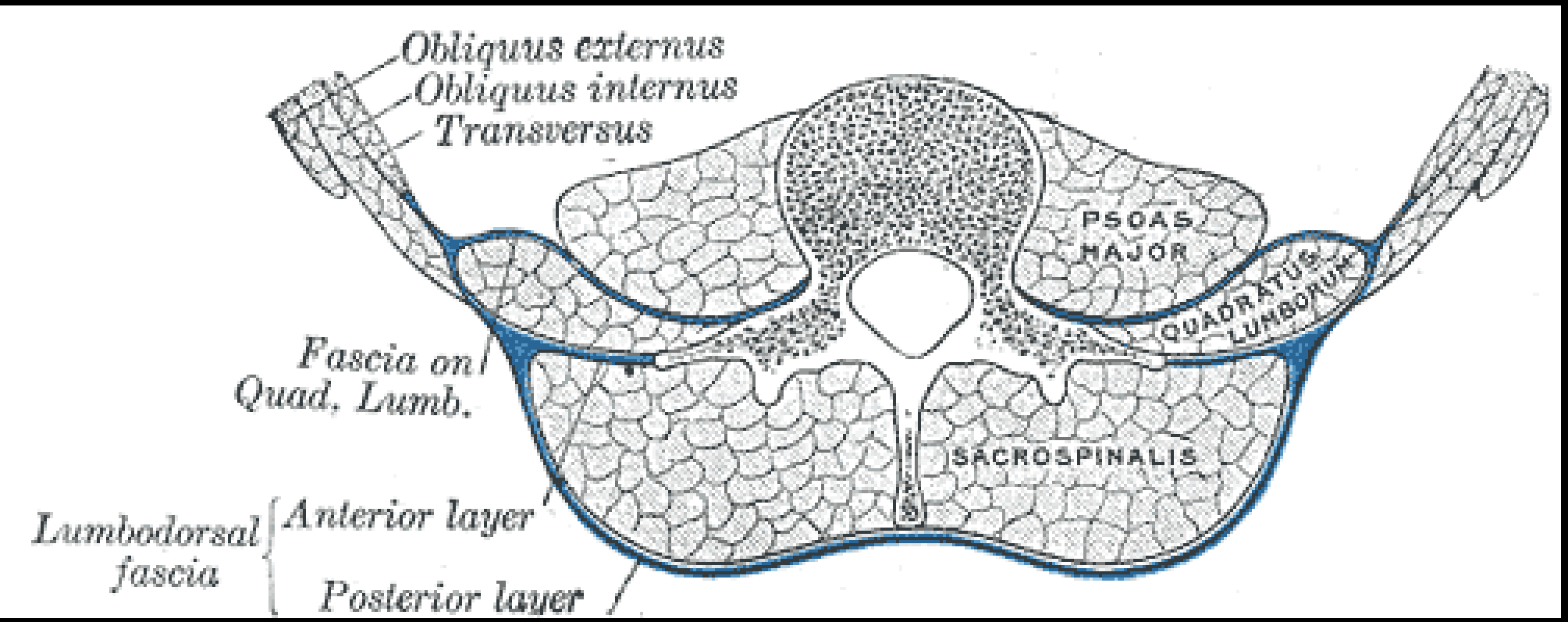

Obliquus externus
Obliquus internus
Transversus
PSOAS MAJOR
QUADRATUS LUMBORUM
Fascia on Quad. Lumb.
SACROSPINALIS
Lumbodorsal fascia
Anterior layer
Posterior layer

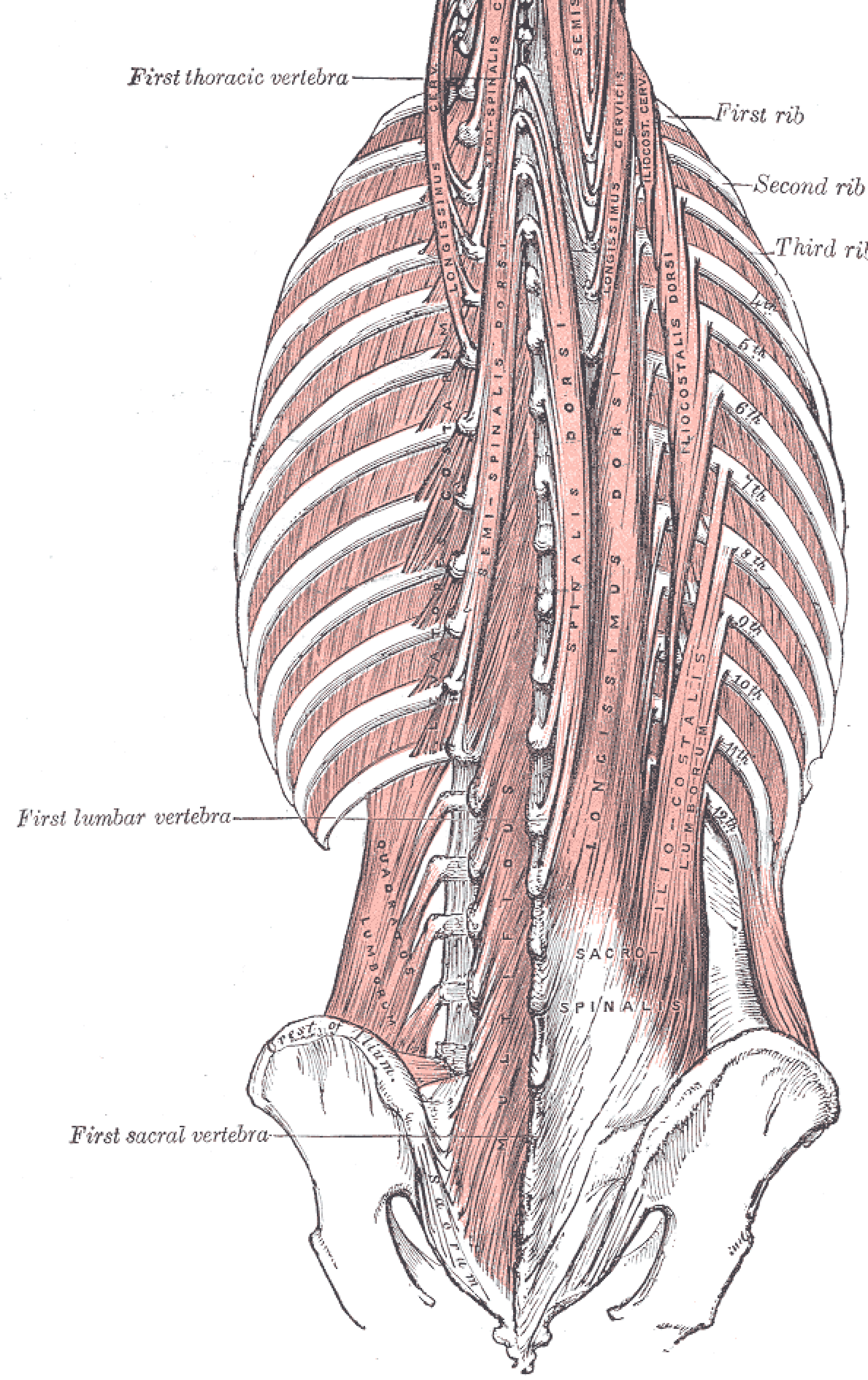

First thoracic vertebra
First rib
Second rib
Third rib
First lumbar vertebra
First sacral vertebra
LONGISSIMUS
SEMI-SPINALIS DORSI
SPINALIS DORSI
LONGISSIMUS DORSI
ILIOCOSTALIS DORSI
ILIO-COSTALIS LUMBORUM
QUADRATUS LUMBORUM
SACRO-SPINALIS
Crest of Ilium

Paraspinal Muscles

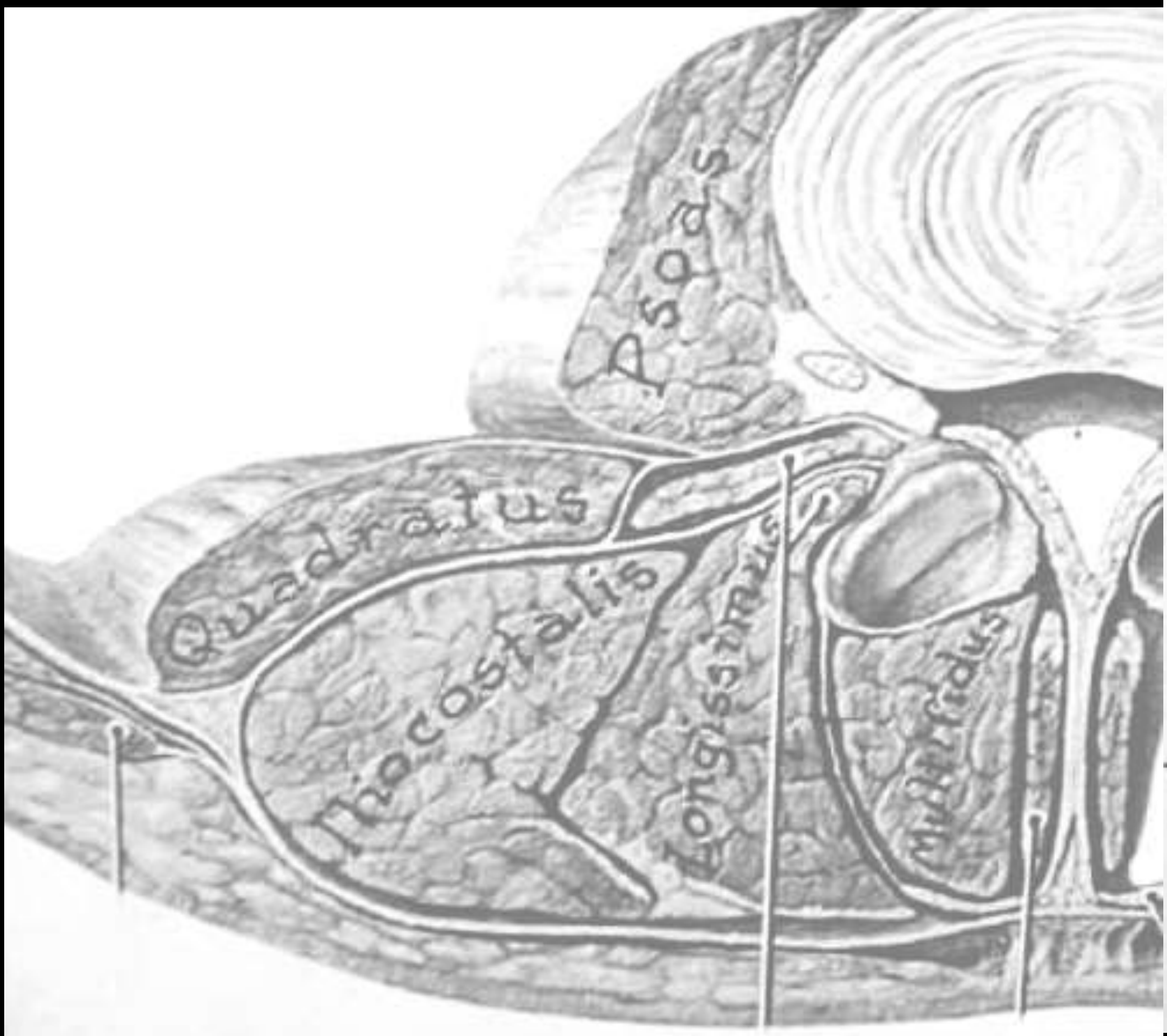

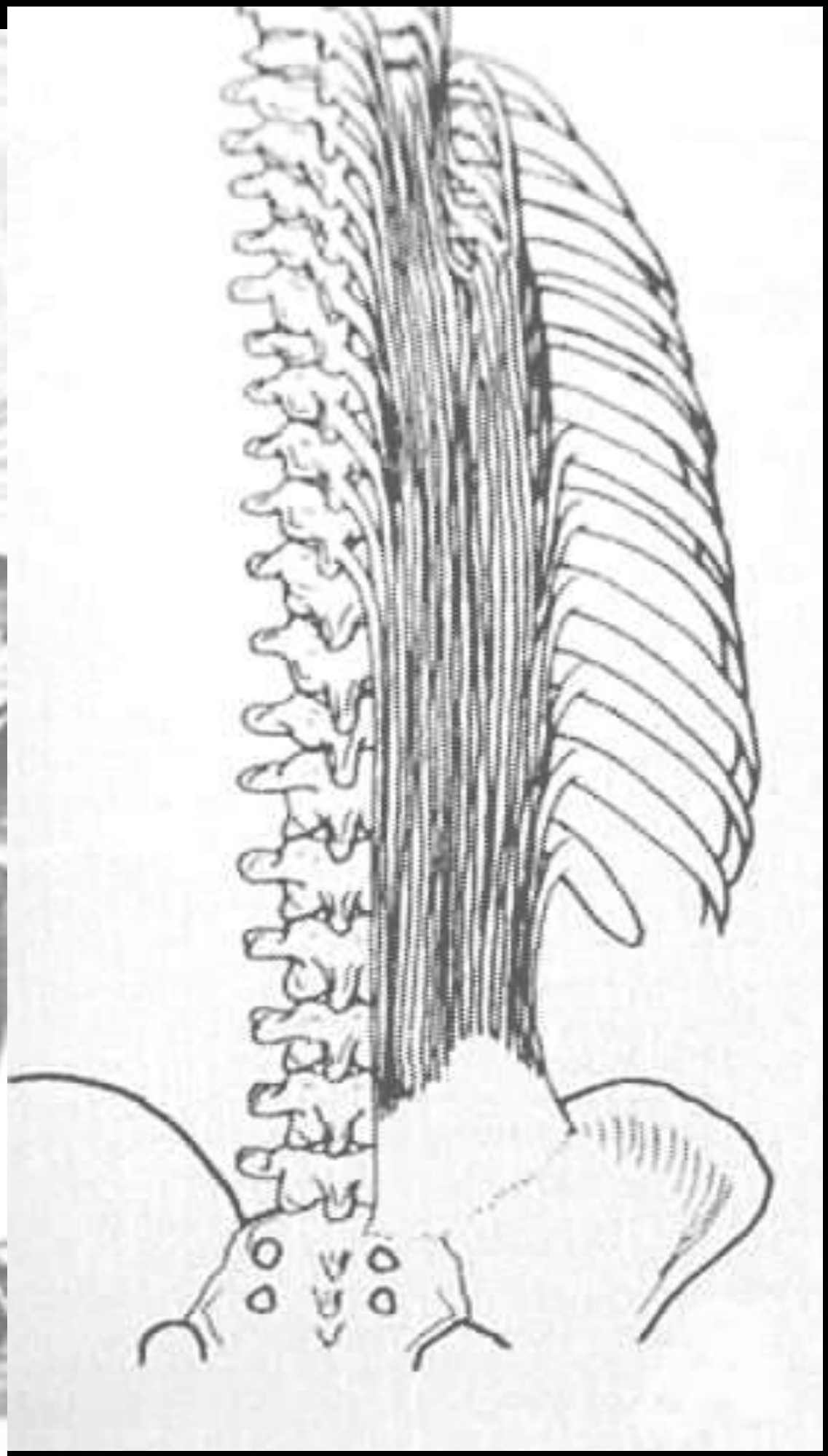

Multifidus

L3 transpedicular

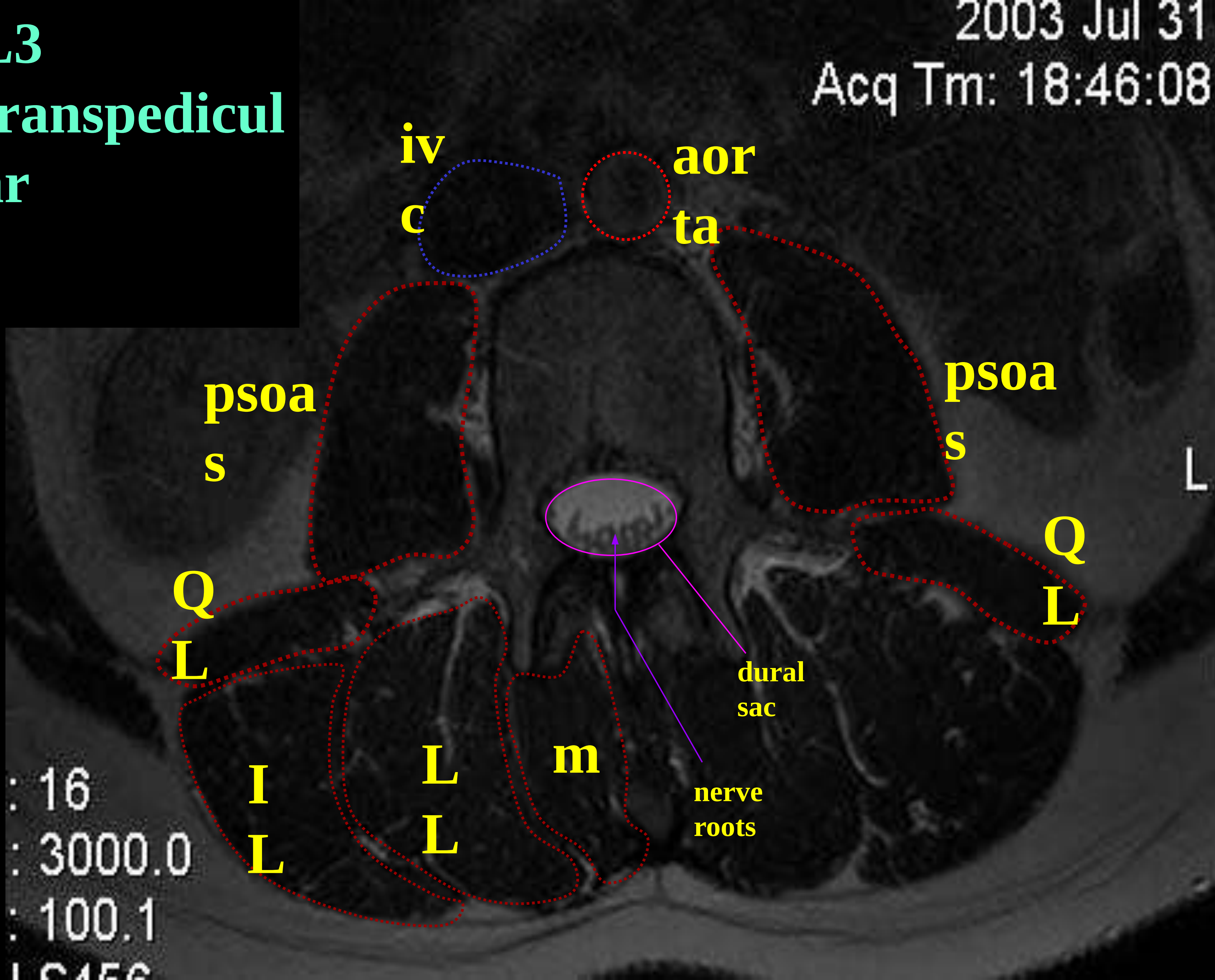

L3 subpedicular

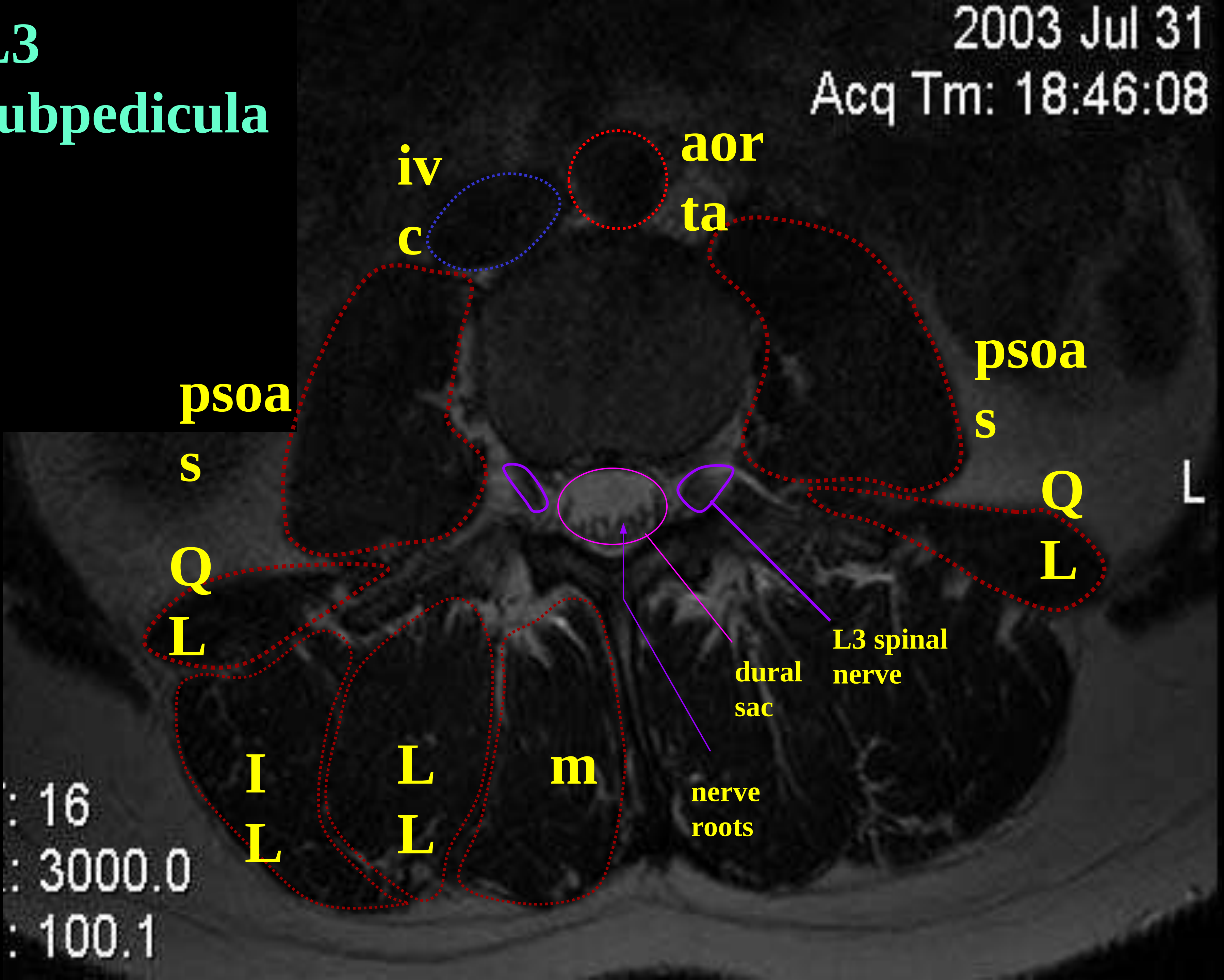

L3-4 disc and z joints

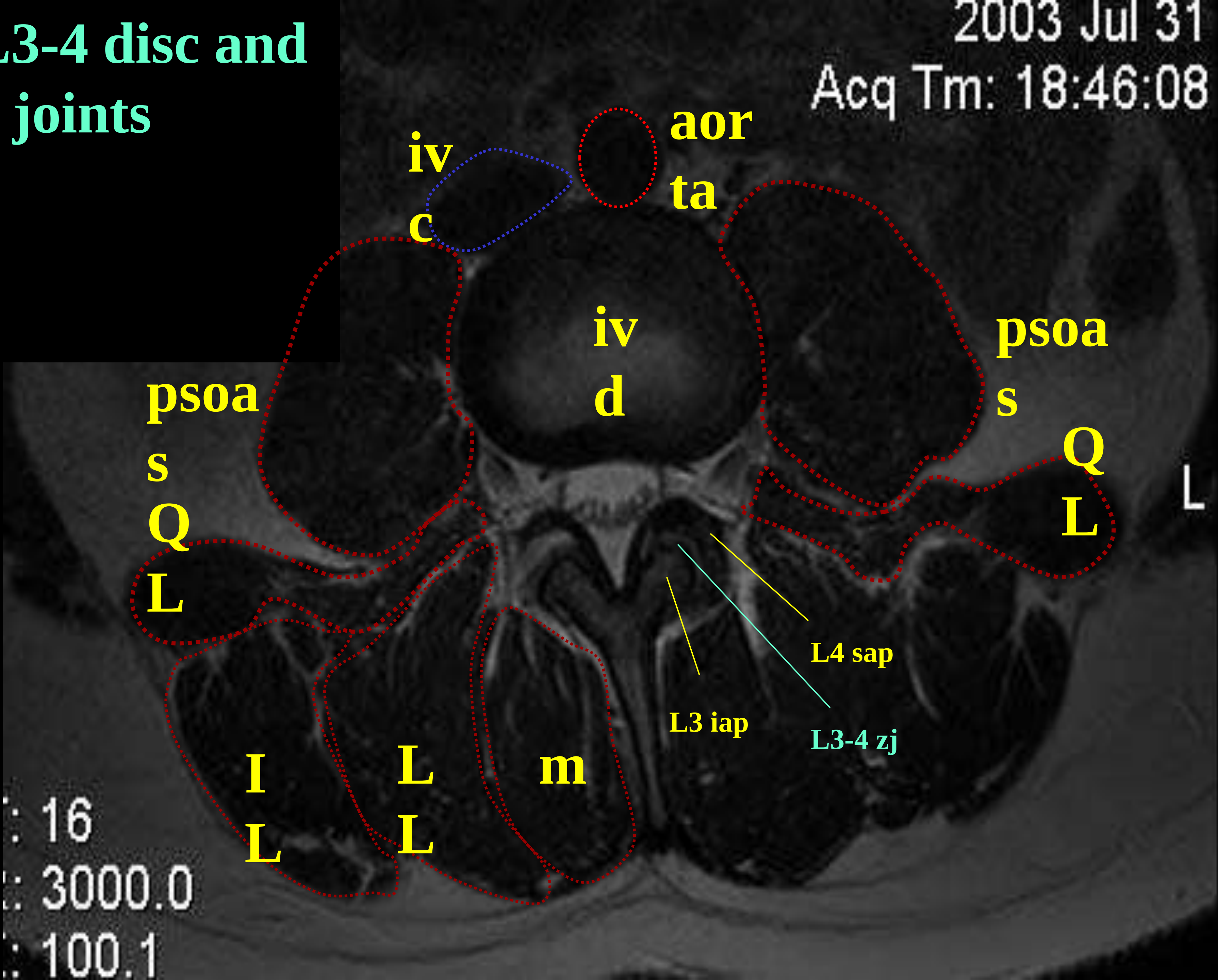

MRI Cervical Spine (T2*, GRE)

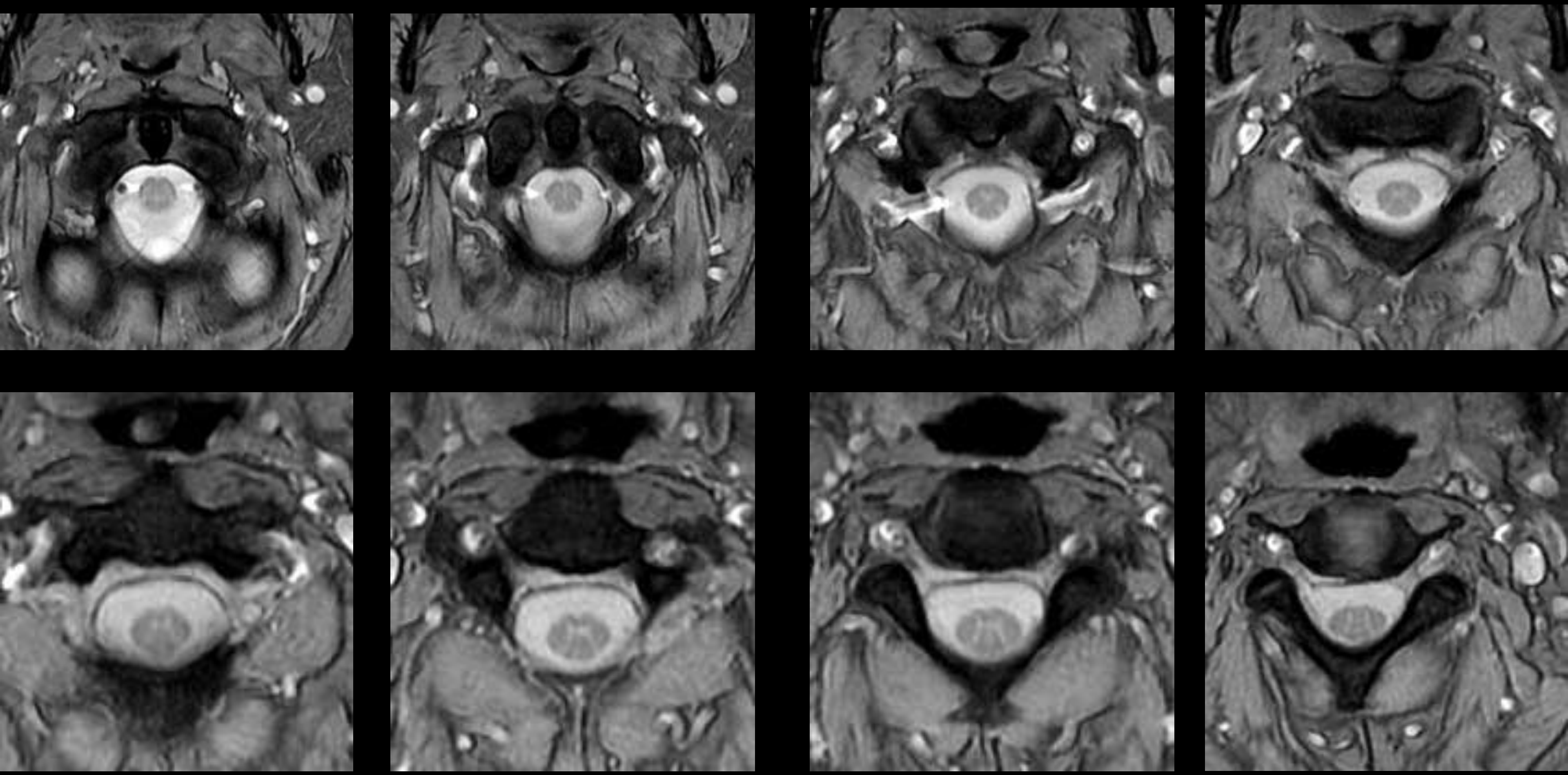

MRI Cervical Spine (FSE)

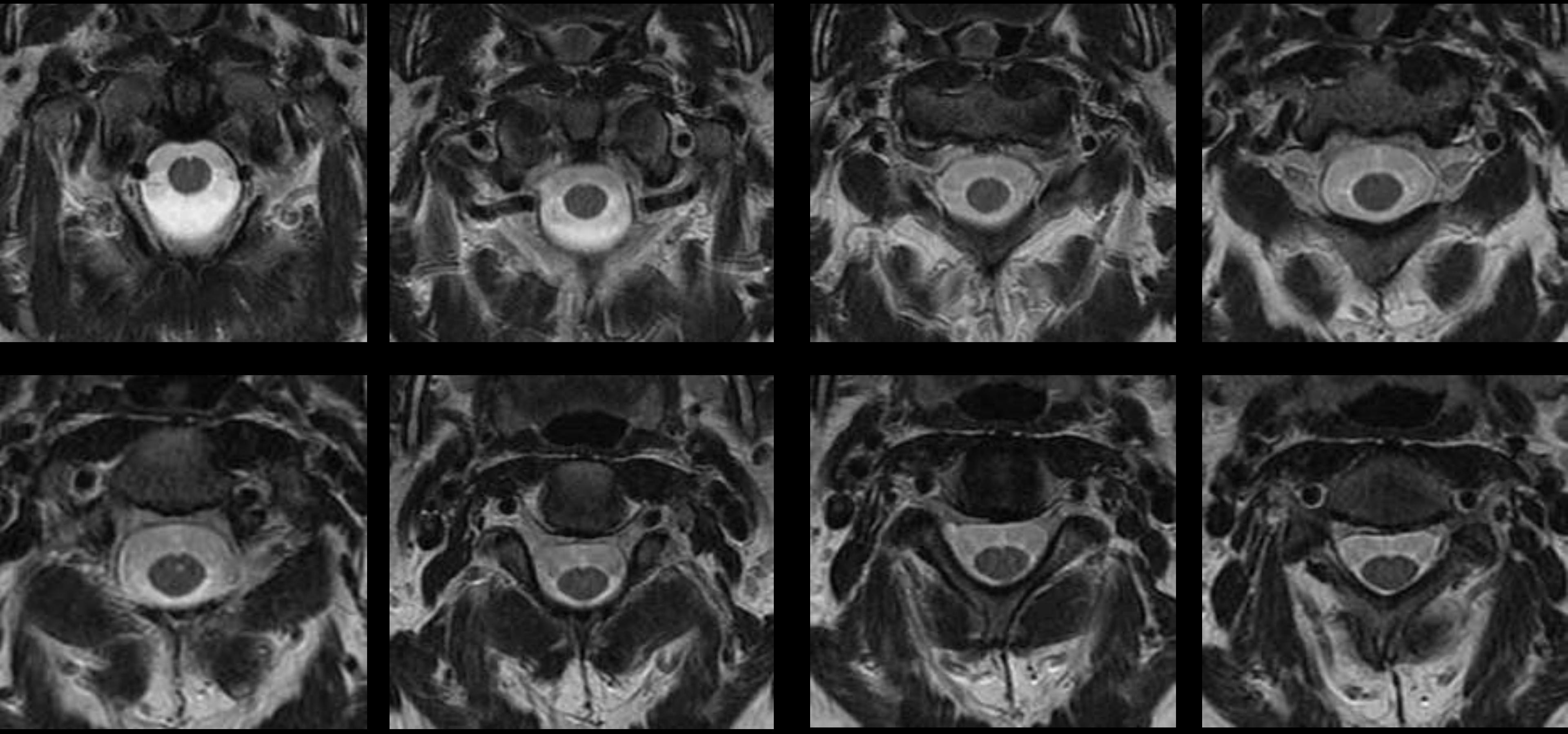

MRI Cervical Spine (FSE)

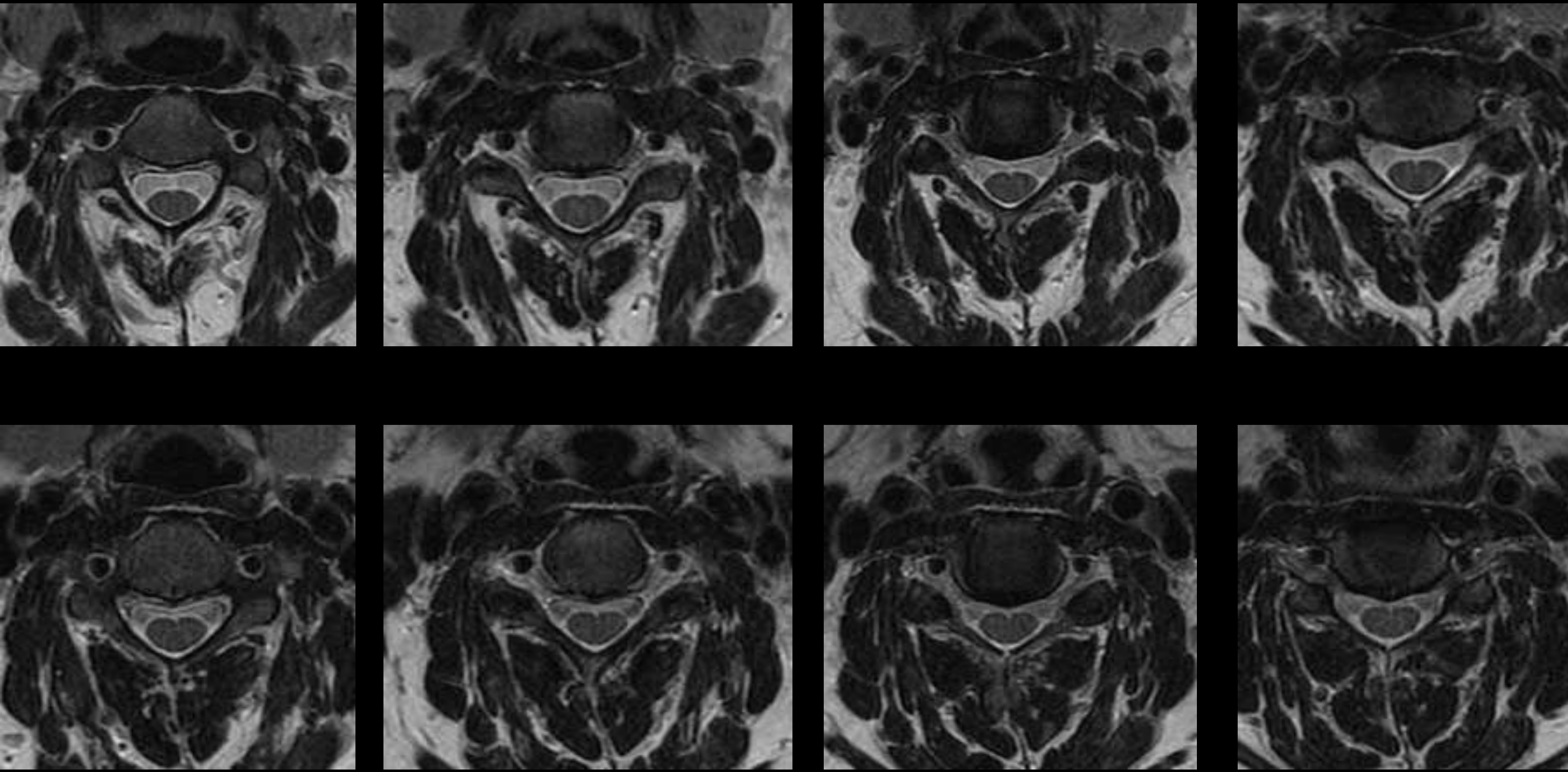

Contents

- Bones
- Joints
- Ligaments
- Muscles/tendons
- Spinal Canal: Epidural/Intradural
- Neural Canals/Neuroforamina
- Neural Elements
- Vascular Anatomy

Meninges/Spaces

- Meninges
  - Dura – one layer, tubular prolongations through foramen
  - Arachnoid – loosely attached to dura, although potential space (subdural) between them exists
  - Pia – adherent to surface of cord

- Spaces
  - Epidural: between dura and surrounding bony canal, contains fat, connective tissue, veins, lymphatics
  - Subdural: potential space between dura and arachnoid – iatrogenically demonstrated
  - Subarachnoid: between arachnoid and pia, contains CSF, vessels, nerves fium terminale

Epidural Space

Between dura and bone

Contents: epidural fat, nerves, blood vessels, ligg. flava, post. long. ligament.

At L5/S1 level the dural sac enlarges and usually no epidural fat is seen at MRI.

Dura extends caudally to S2 and has lat. out-pouchings to nerve roots.

Cervical Epidural Space

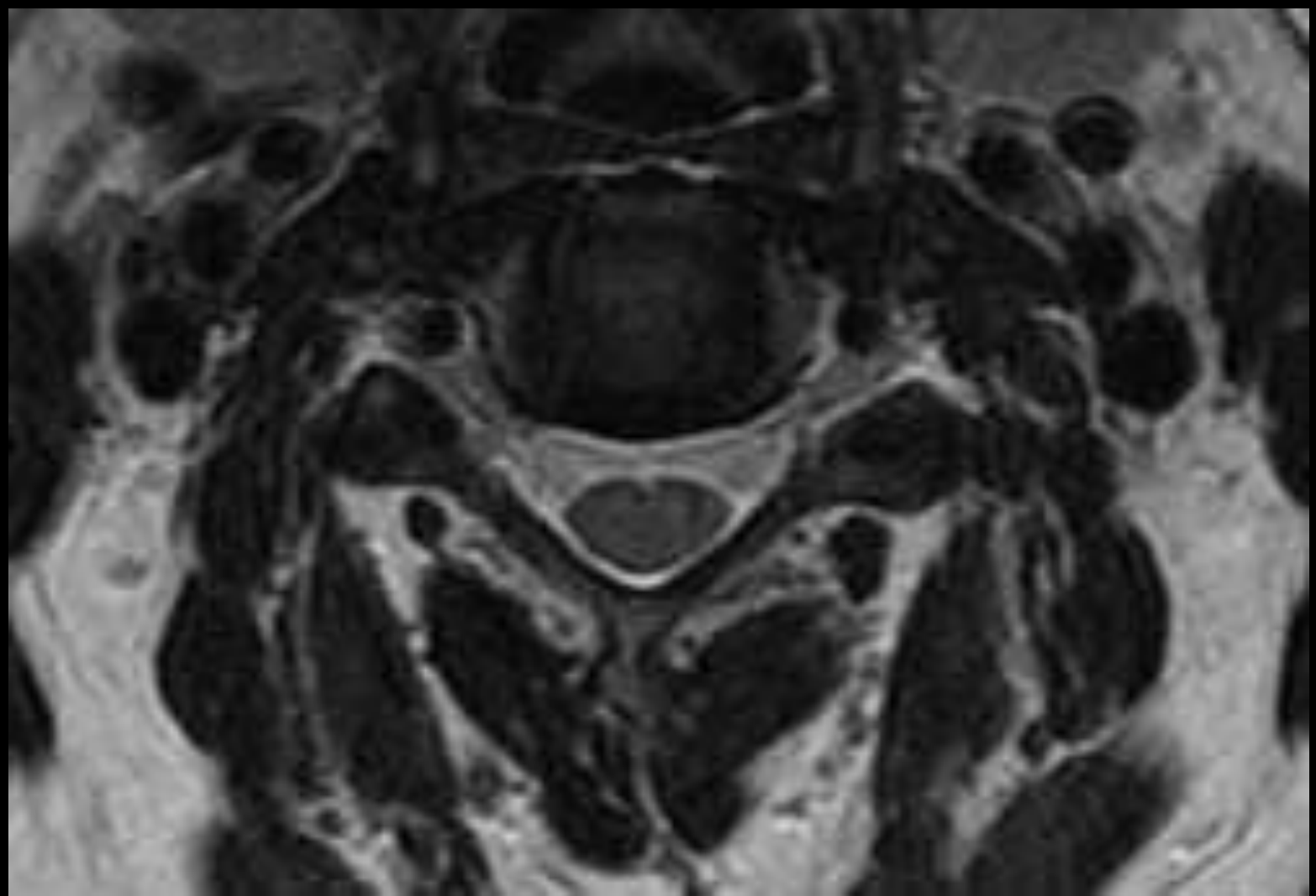

Cervical epidural fat.

- Not much of it.
- Most constant is a posterior fat pad.
- Usually most prominent at C7/T1.

That’s how I see it
Charles Aprill

Axial section through C5/6 disc / prepared by W

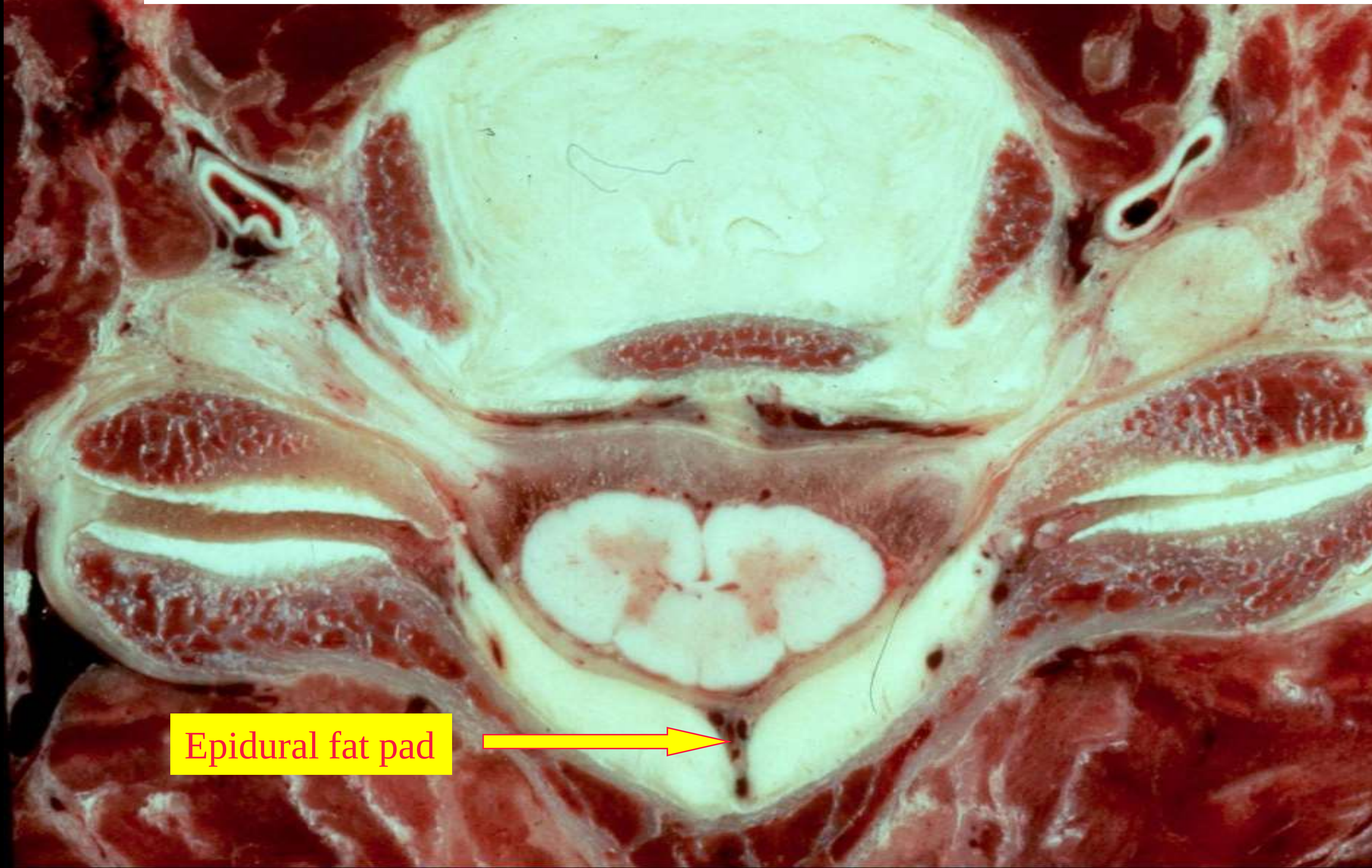

Axial CT section through C5/6 disc – post myel
Ie subarachnoid and vascular enhancement.

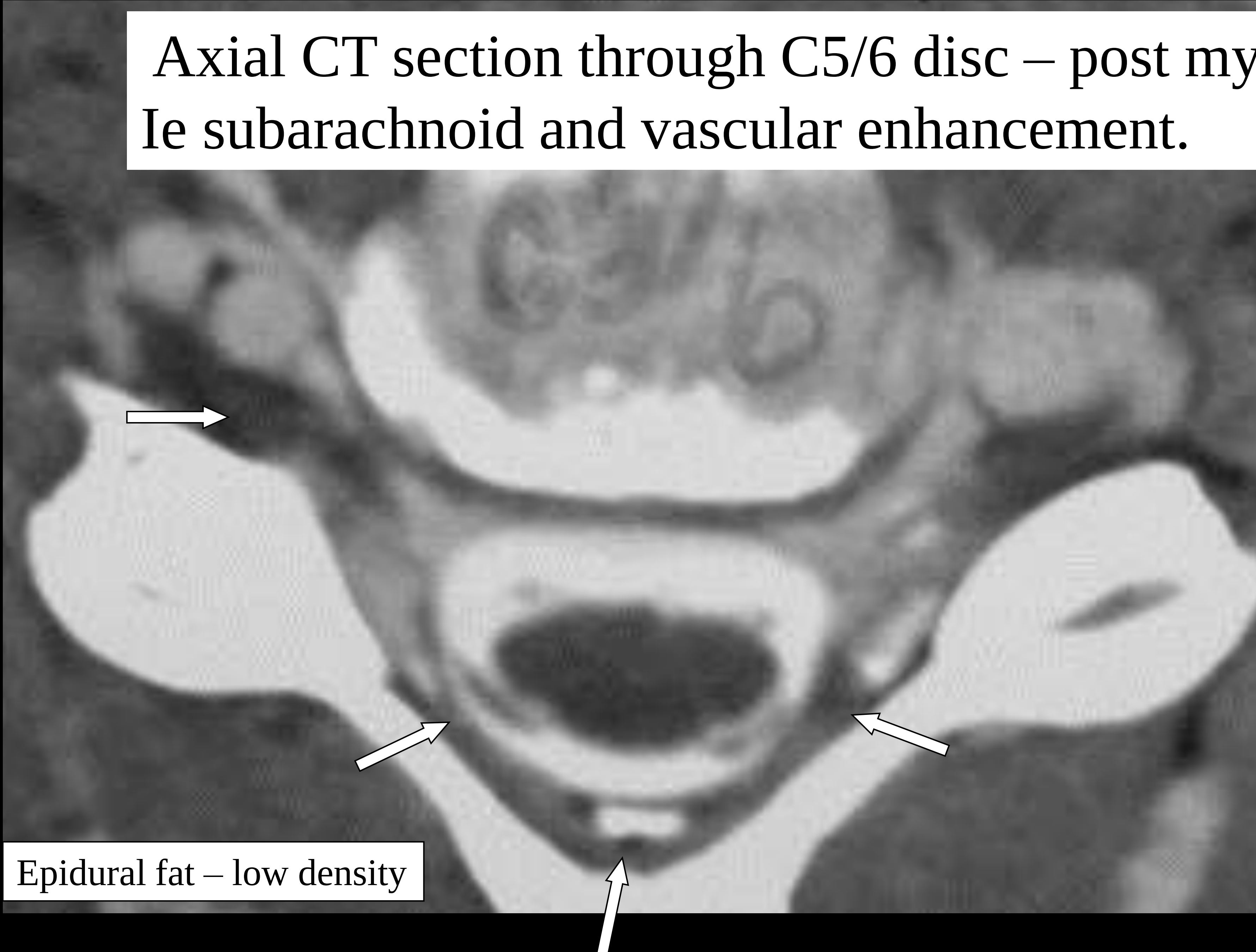

SE T2 MRI - Axial section through C5/6 d

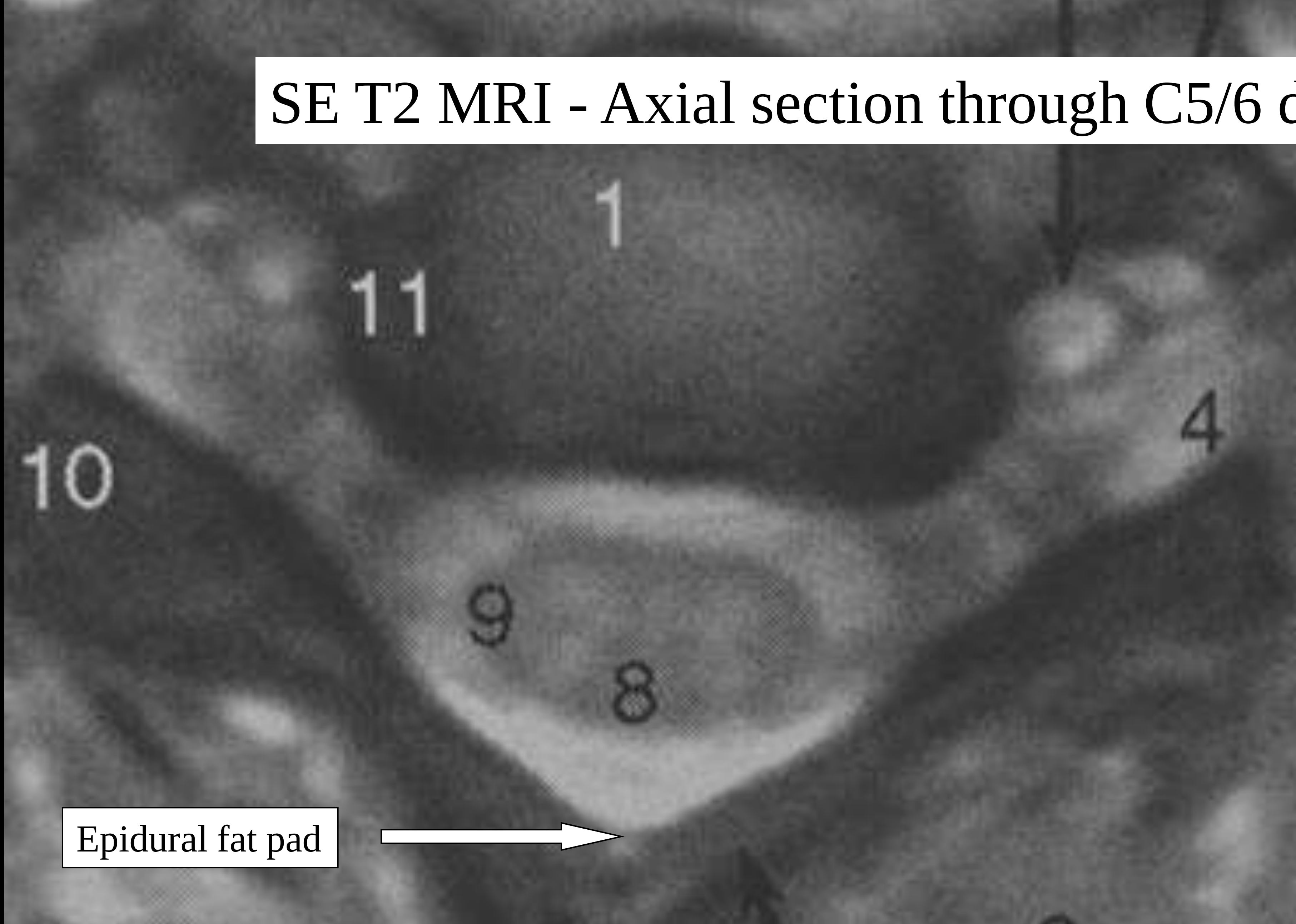

SE T1 MRI – Mid line sagittal section

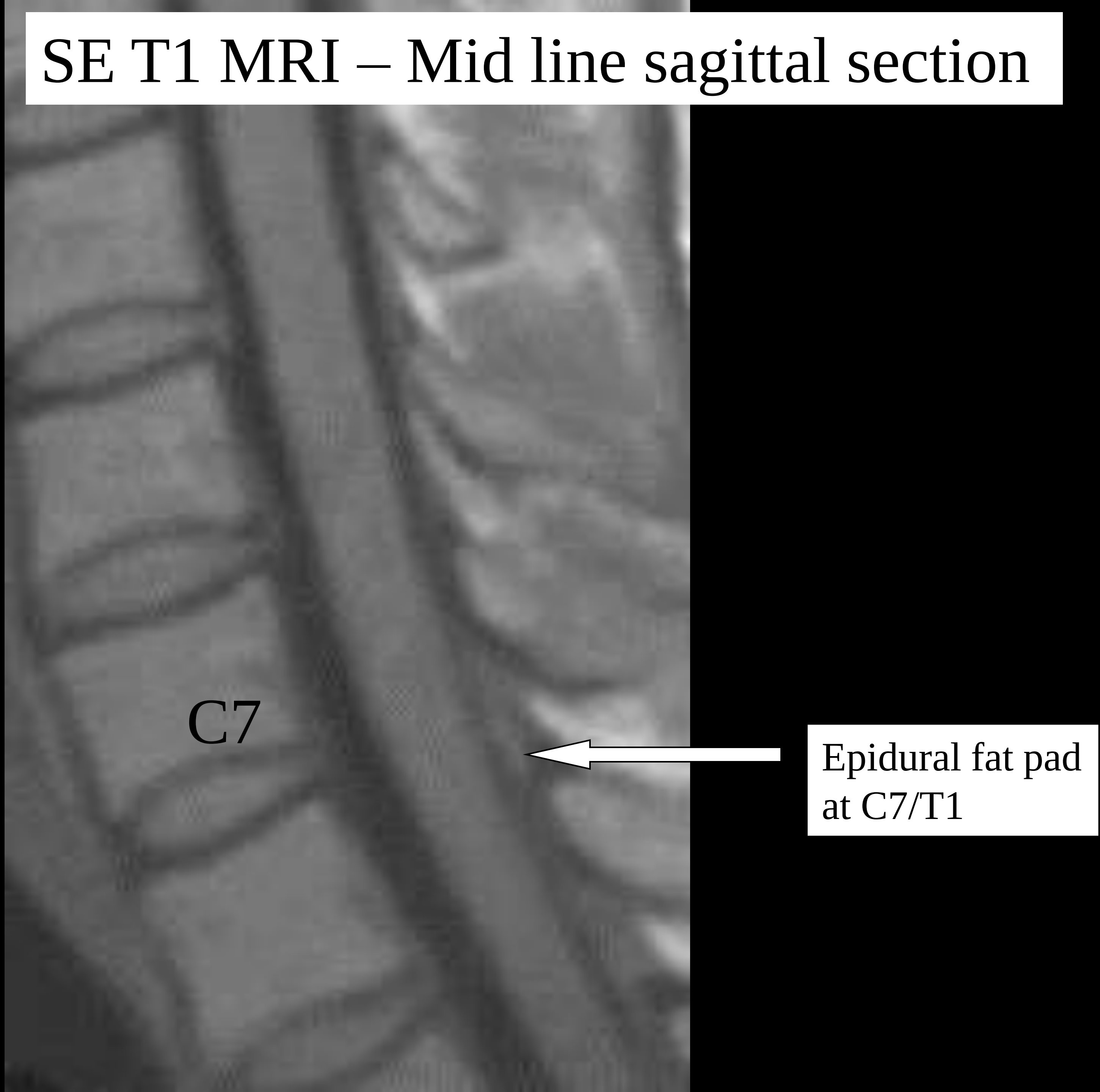

Epidural Space

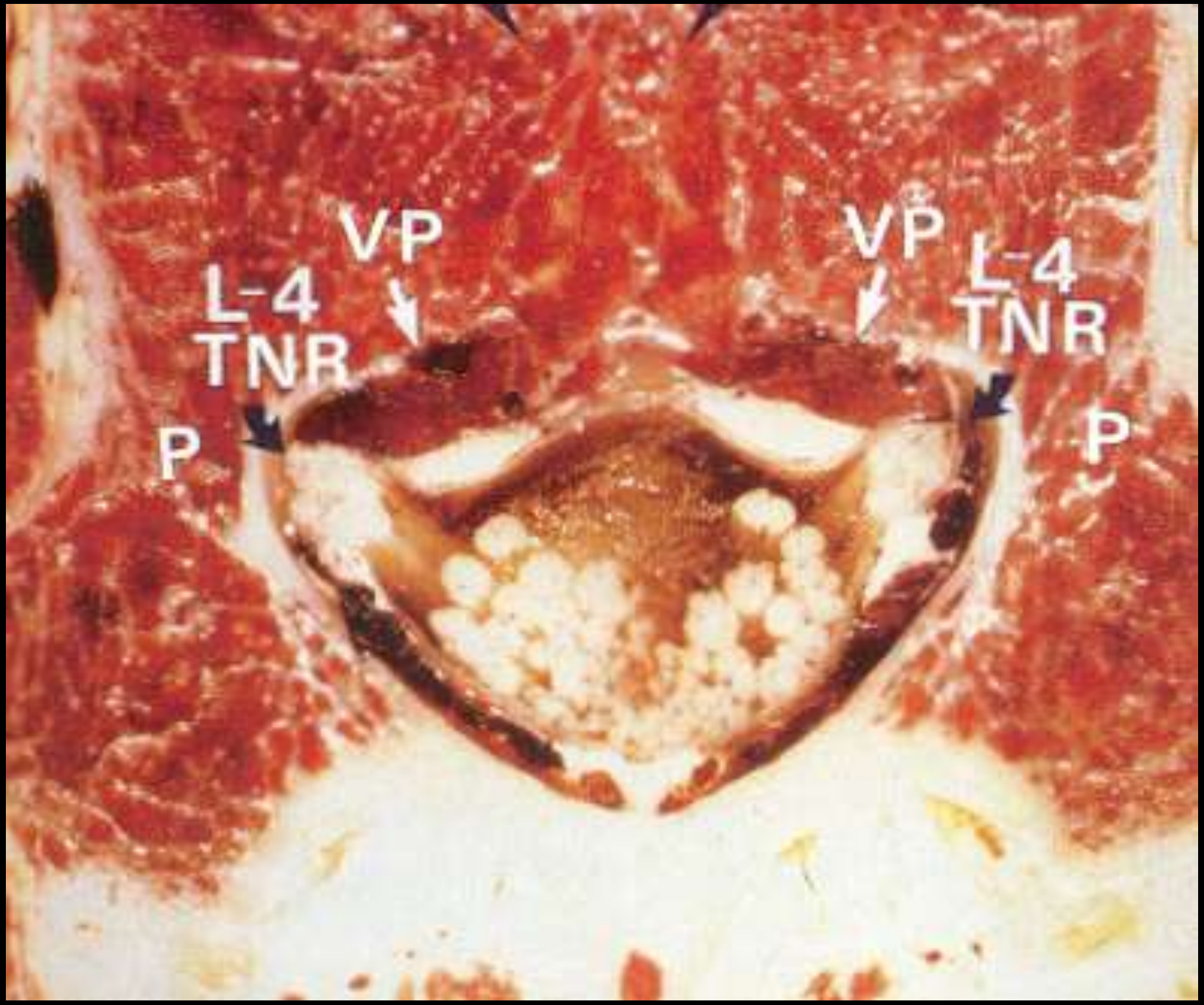

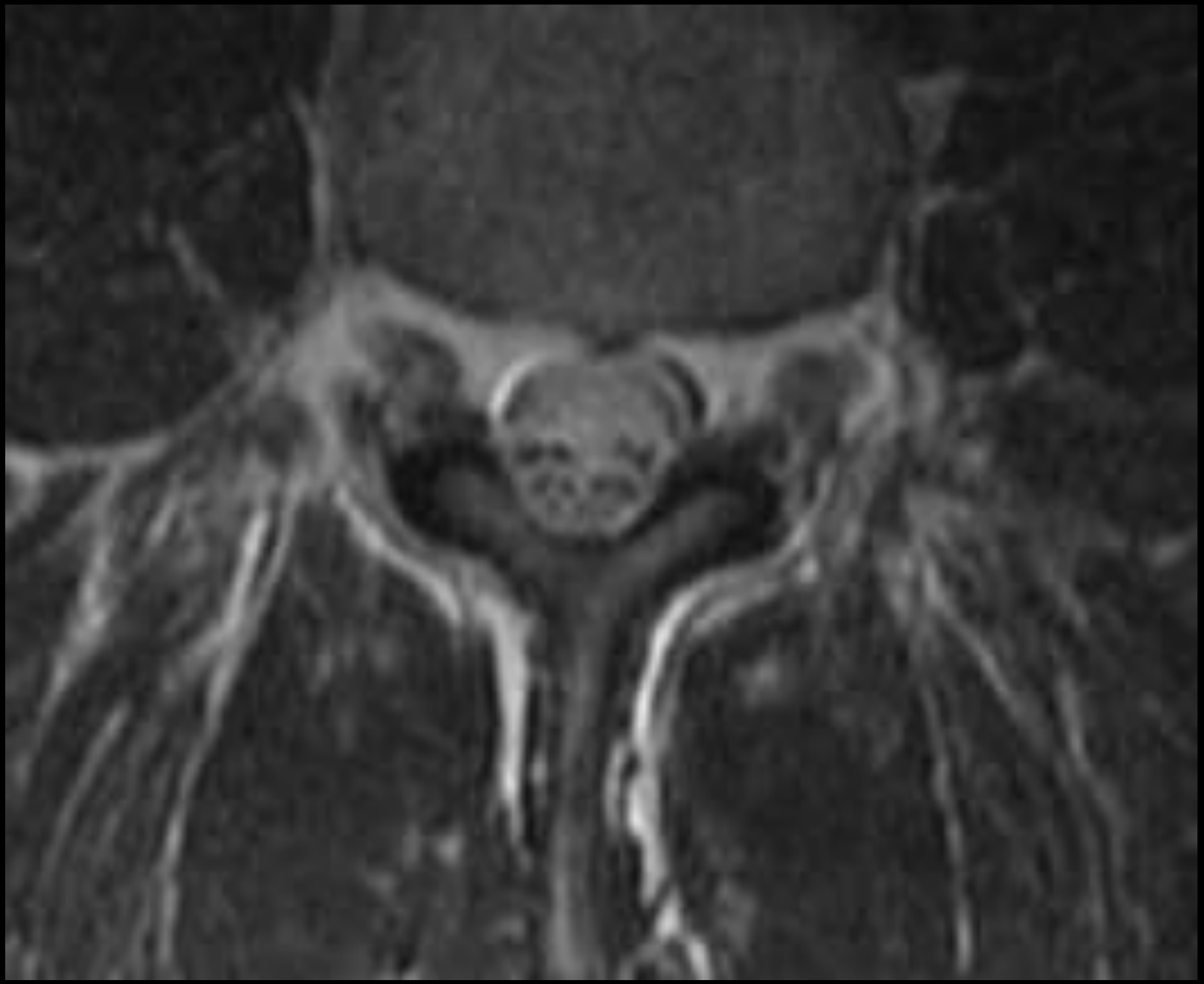

Central canal anatomy: MR
Thecal sac

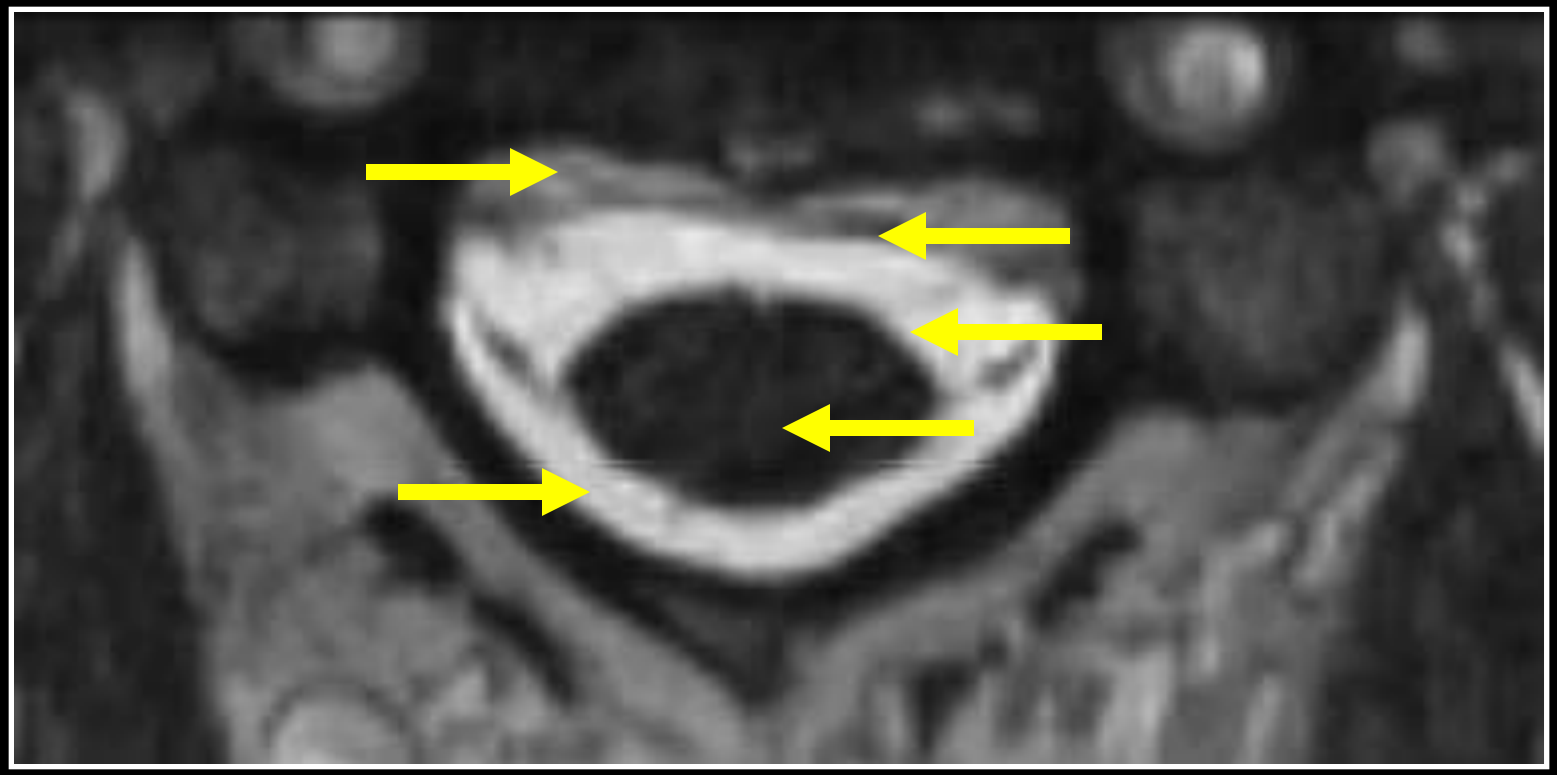

Courtesy of Anna Nidecker and Ari Blitz

- Meninges
- Epidural space
  - Fat, loose connective tissue, venous plexi
- (Subdural space)
- Subarachnoid space
  - CSF, spinal arteries and veins
  - Spinal cord
  - Nerves, filum terminale

Central canal anatomy: MR Thecal sac

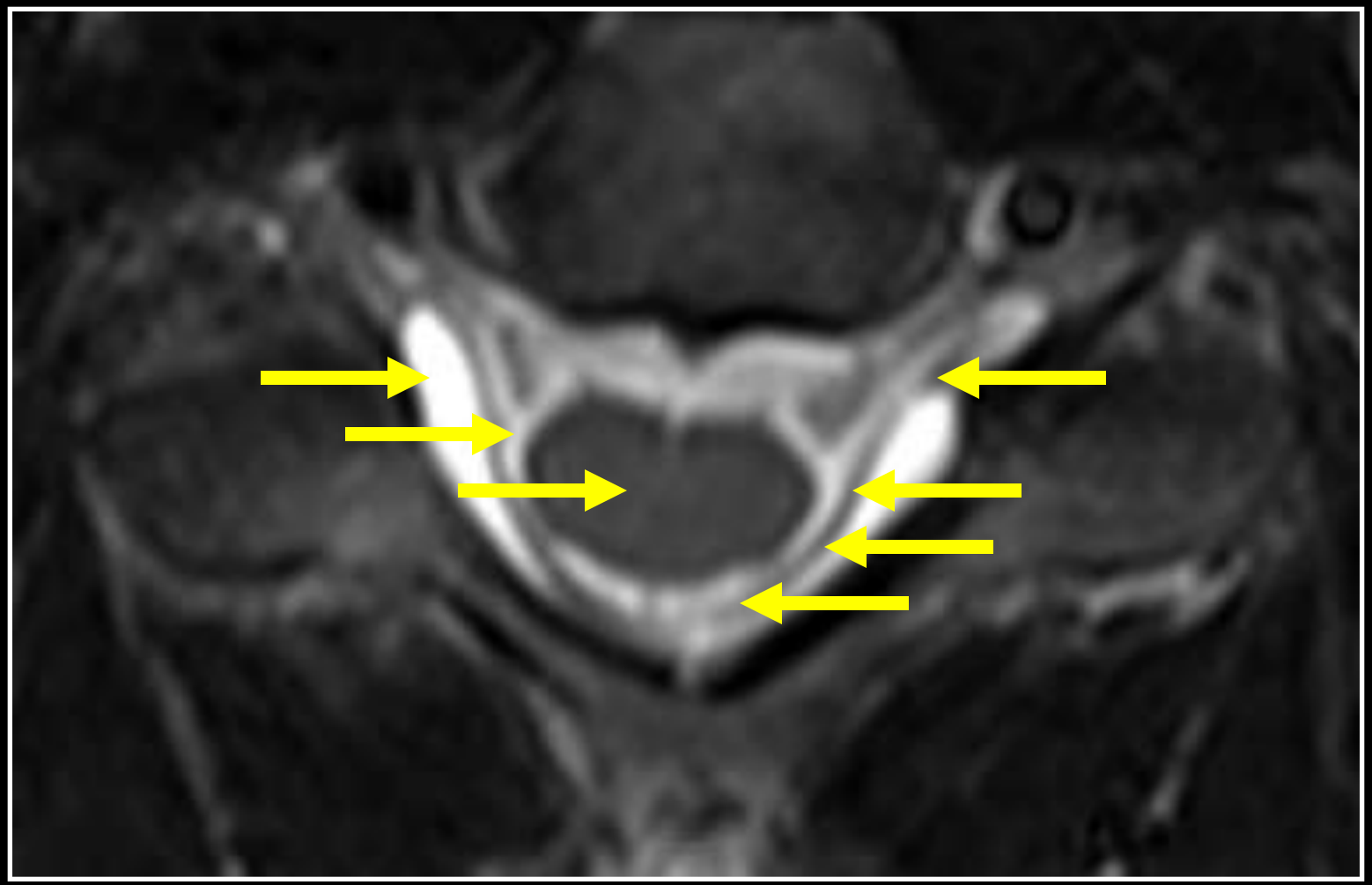

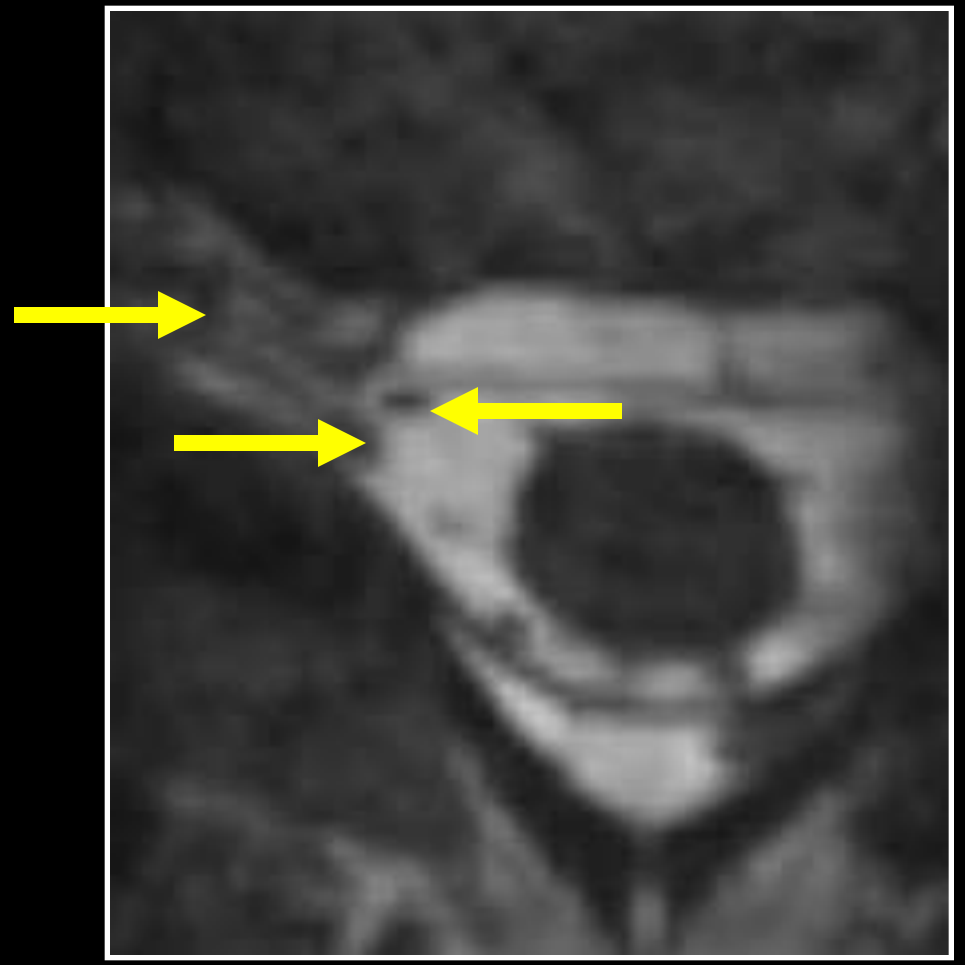

- Dura
- Dural nerve root sleeve
- Epidural space with fluid (abnormal)
- Subarachnoid space CSF (compressed)
- Spinal cord
- Nerve roots
  - Ventral
  - Dorsal
- Neural foramen

Courtesy of Anna Nidecker and Ari Blitz

Central canal anatomy:
CT Myelography - Thecal sac

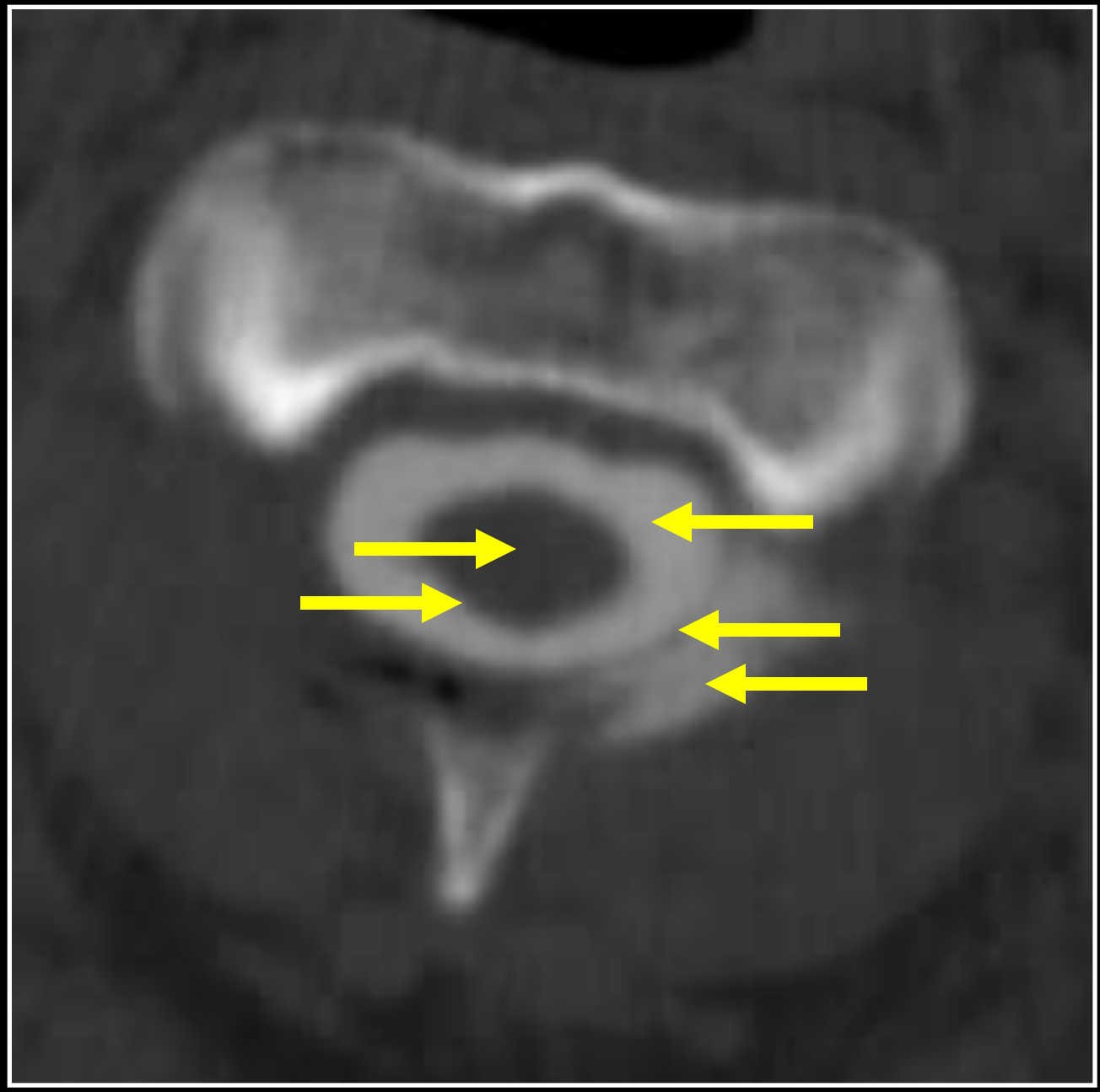

- Epidural space
- Meninges
  - Dura
  - Arachnoid
  - Pia
- (Subdural space)
- Subarachnoid space
  - CSF
- Spinal cord

Courtesy of Anna Nidecker and Ari Blitz

Intradural Space

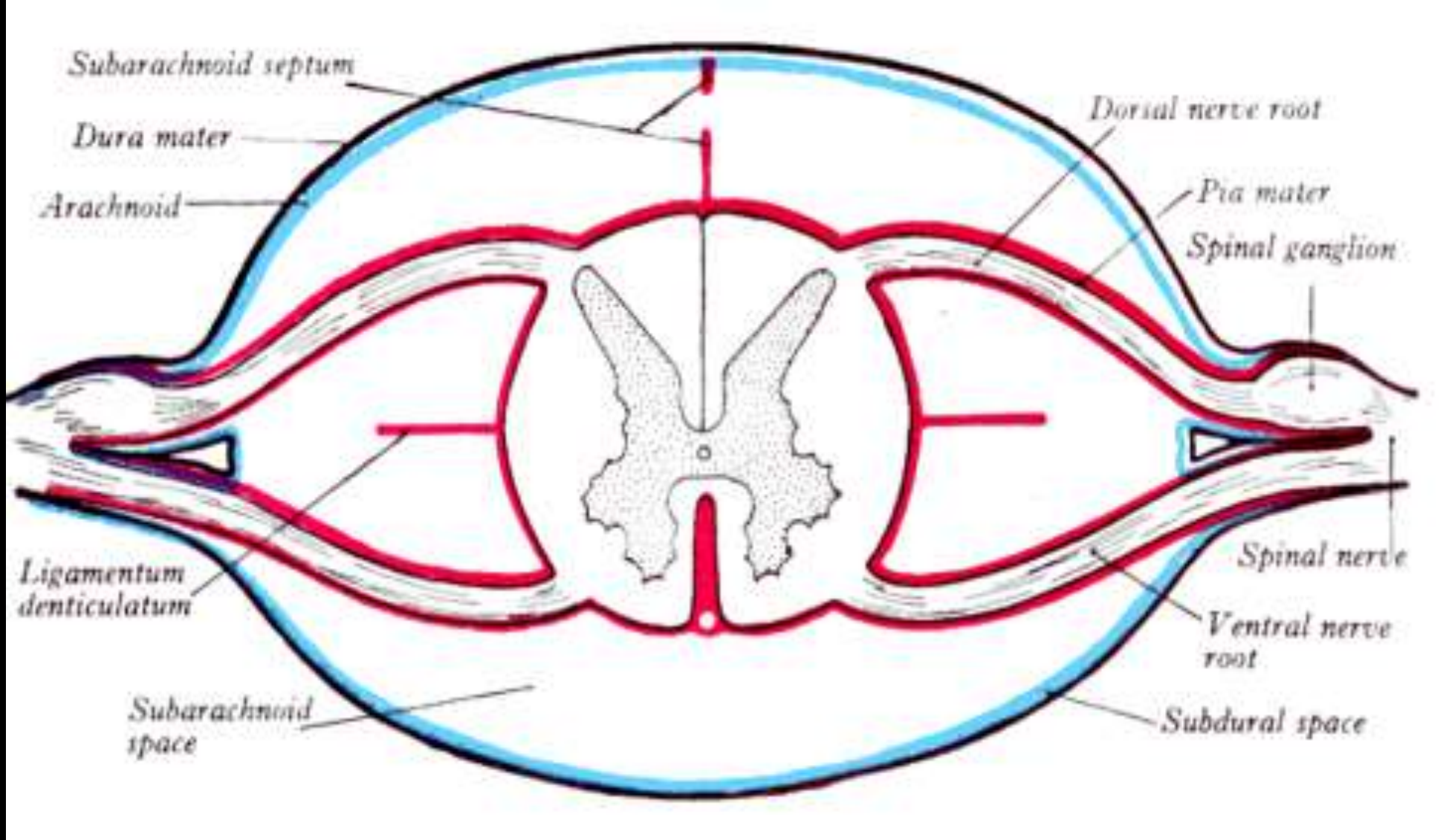

Neural Foramina and Nerve Roots: Myelography

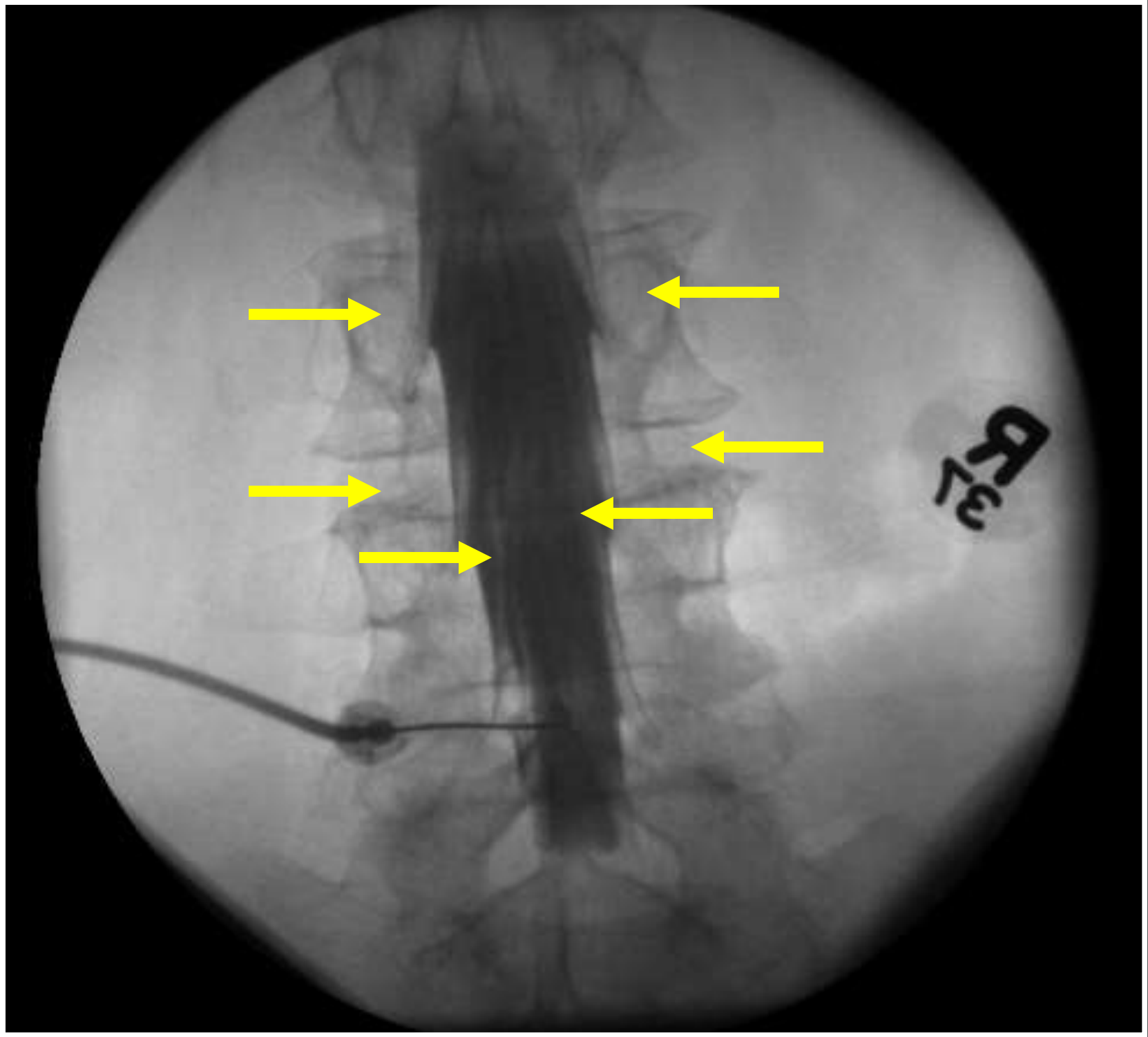

- AP
  - Nerve roots (cauda equina in lumbar spine)
  - Pedicles
  - Disc spaces

Courtesy of Anna Nidecker and Ari Blitz

Neural Foramina and Nerve Roots: Myelography

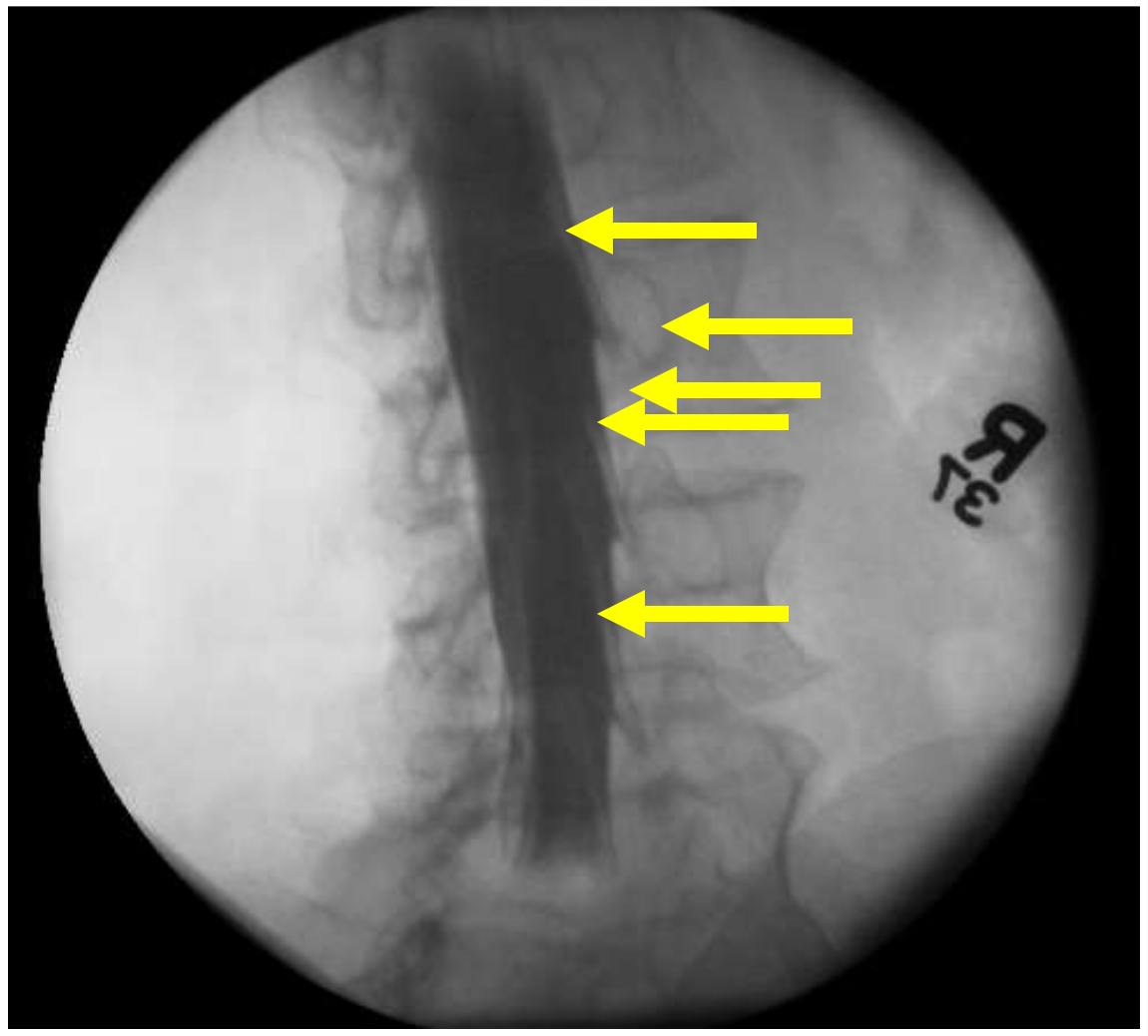

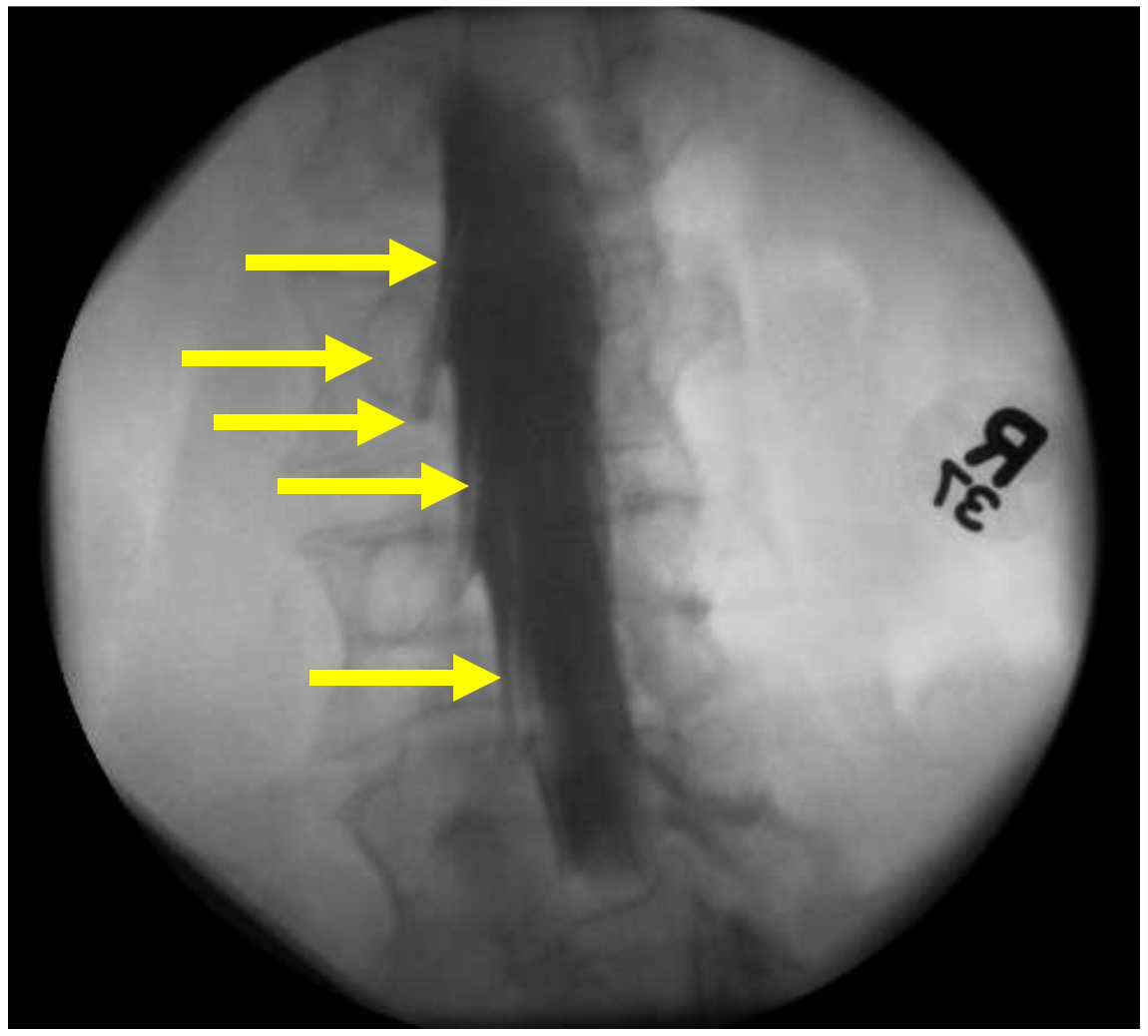

- Oblique
  - Nerve roots
  - Pedicles
  - Neural foramen

Courtesy of Anna Nidecker and Ari Blitz

MRI Myelography

Tarlov Cysts

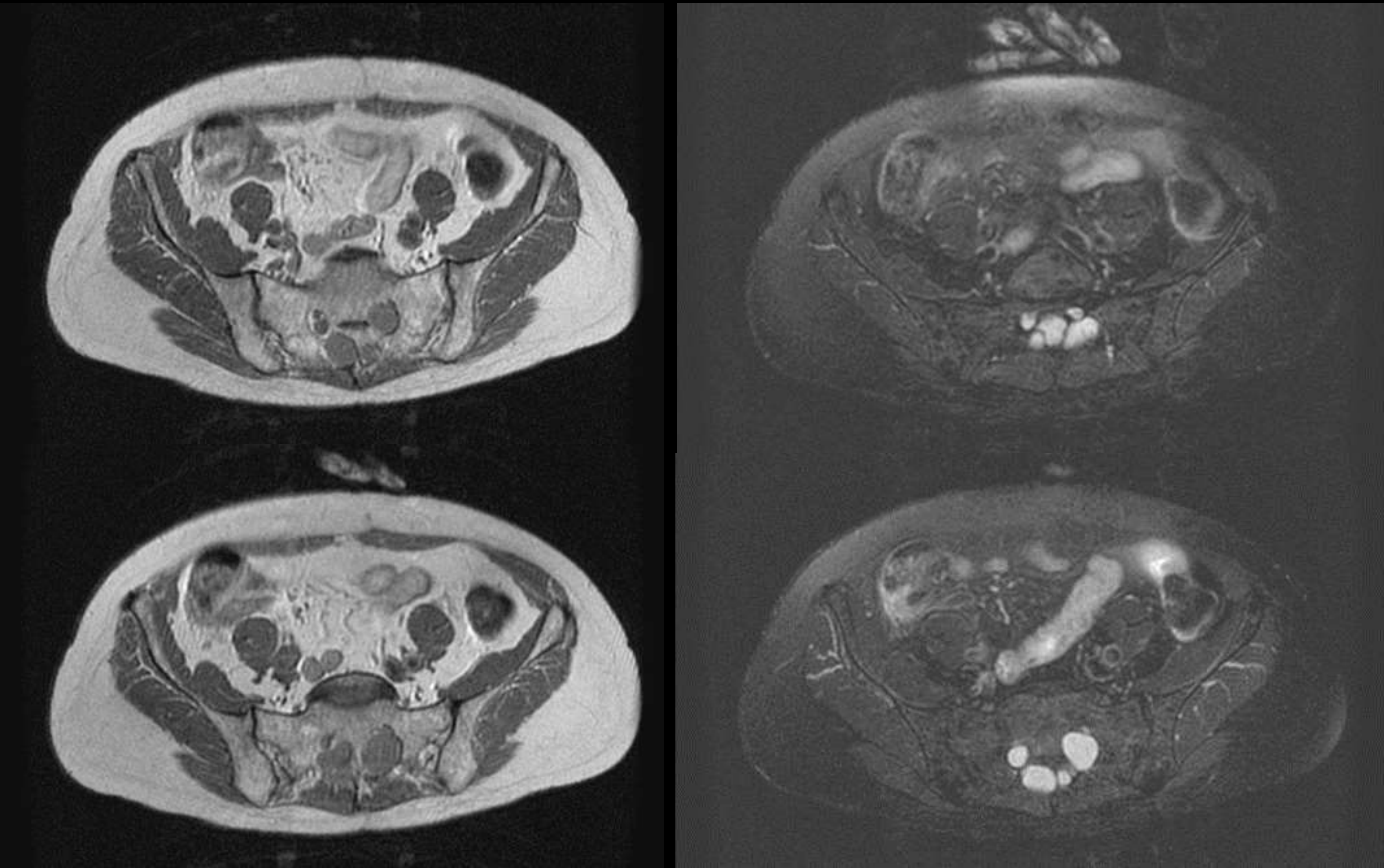

LEVELS

In the caudocranial direction visualized on sagittal and coronal images, we have chosen the term **levels**.

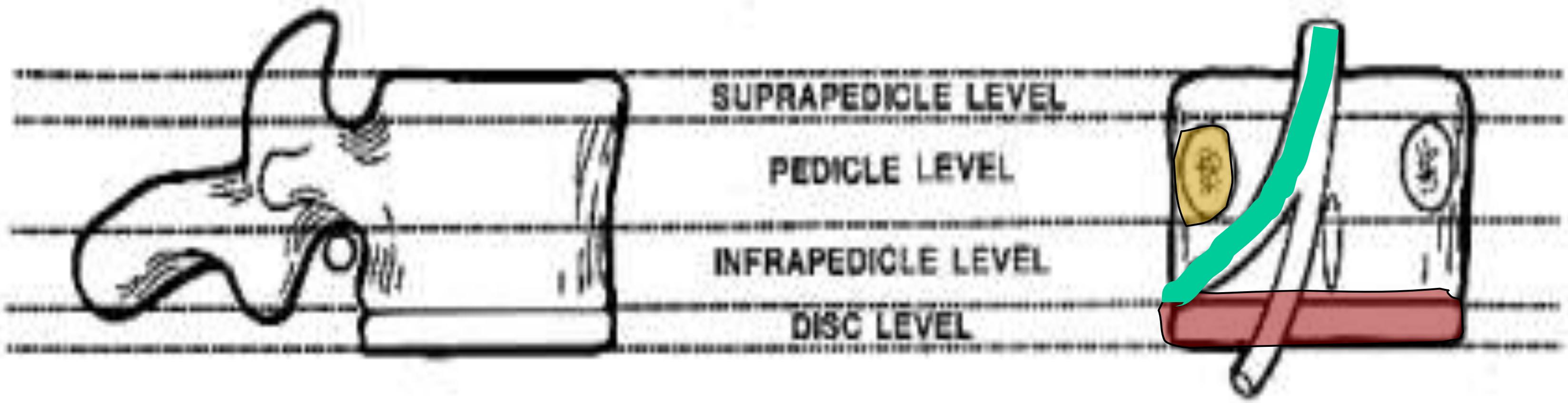

In the axial image, the sagittal and parasagittal planes are called **zones.**

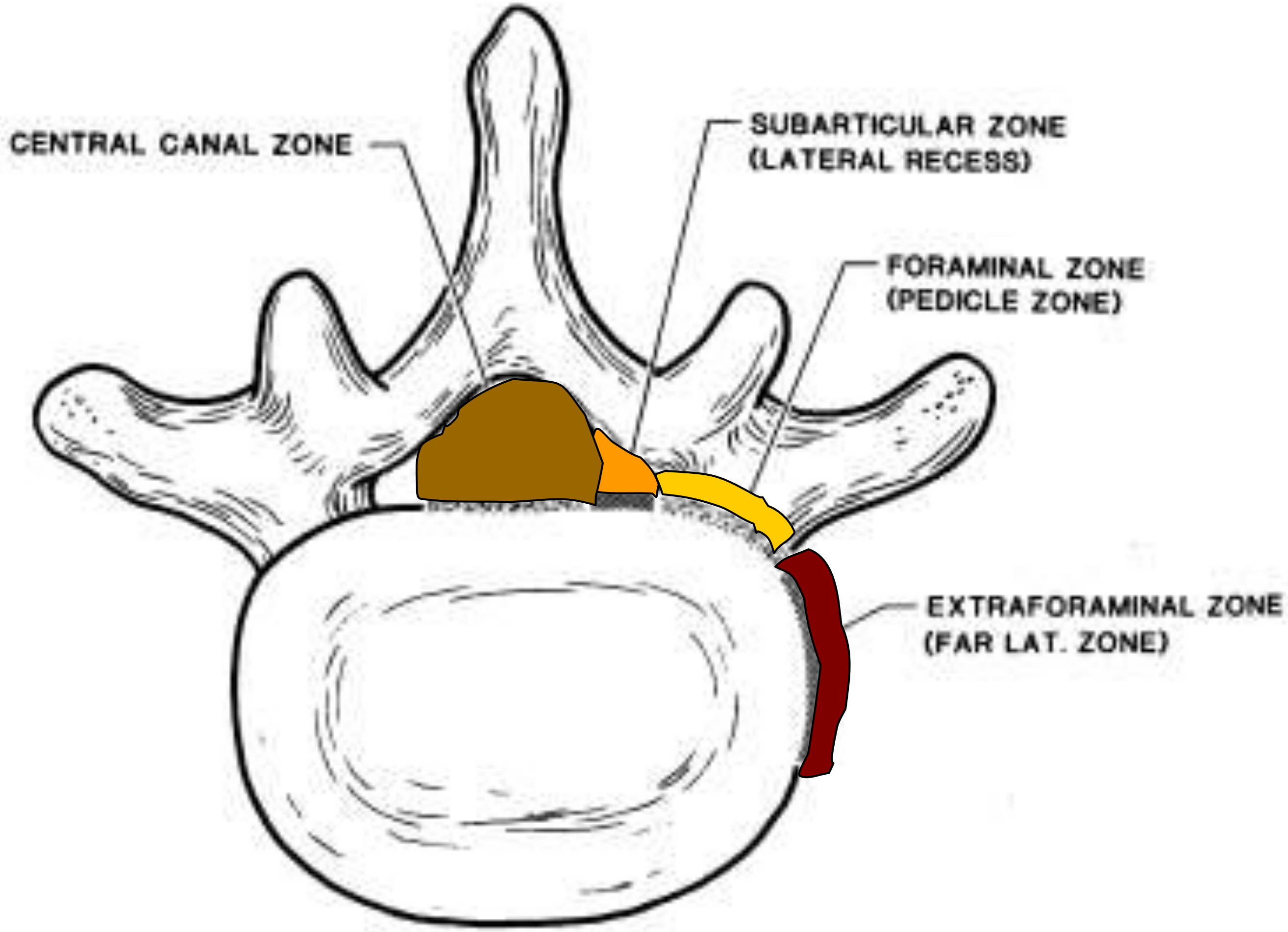

Contents

- Bones
- Joints
- Ligaments
- Muscles/tendons
- Spinal Canal: Epidural/Intradural
- Neural Canals/Neuroforamina
- Neural Elements
- Vascular Anatomy

Ebraheim: Neuroforamen

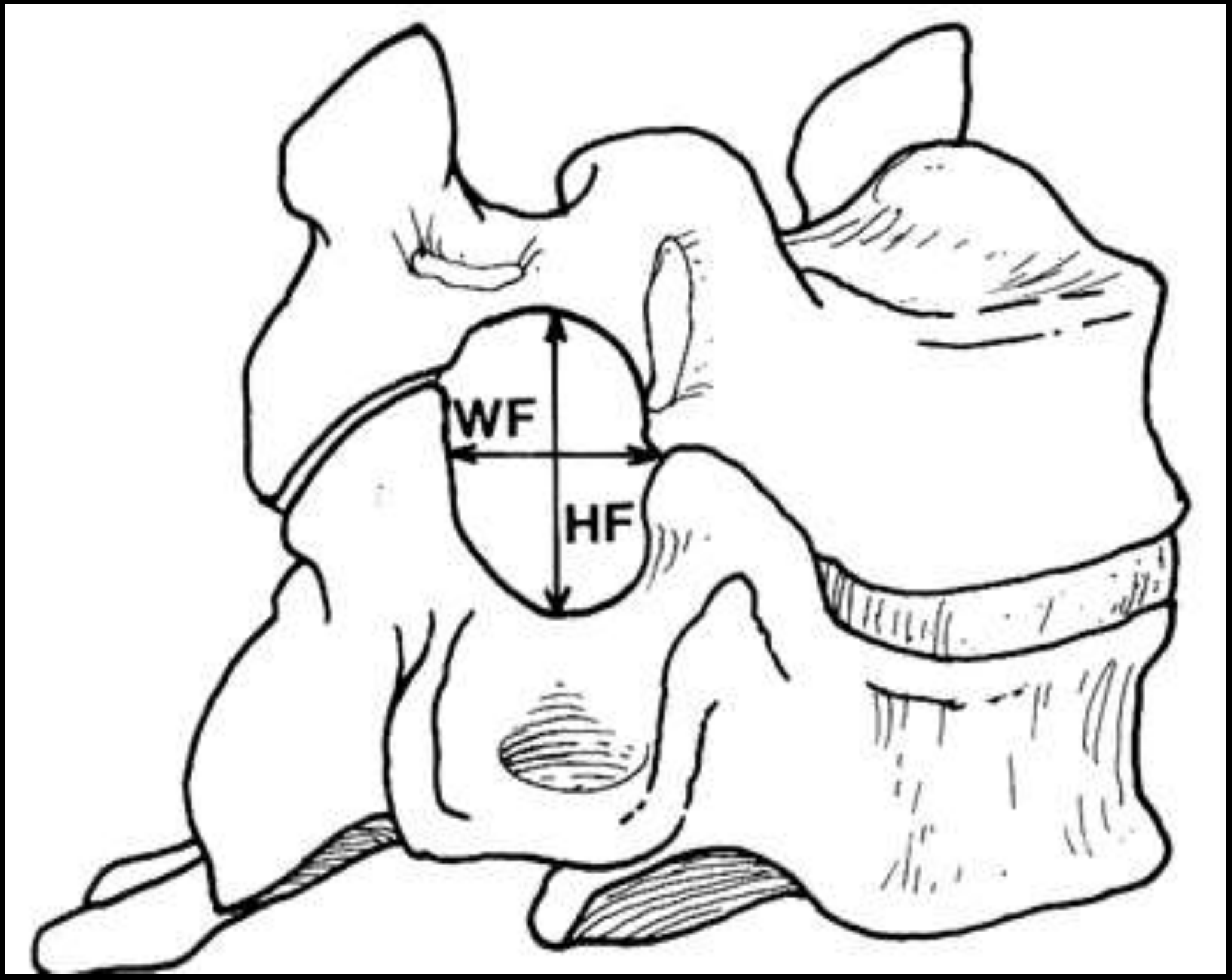

Anatomy of cervical Neuroforamen

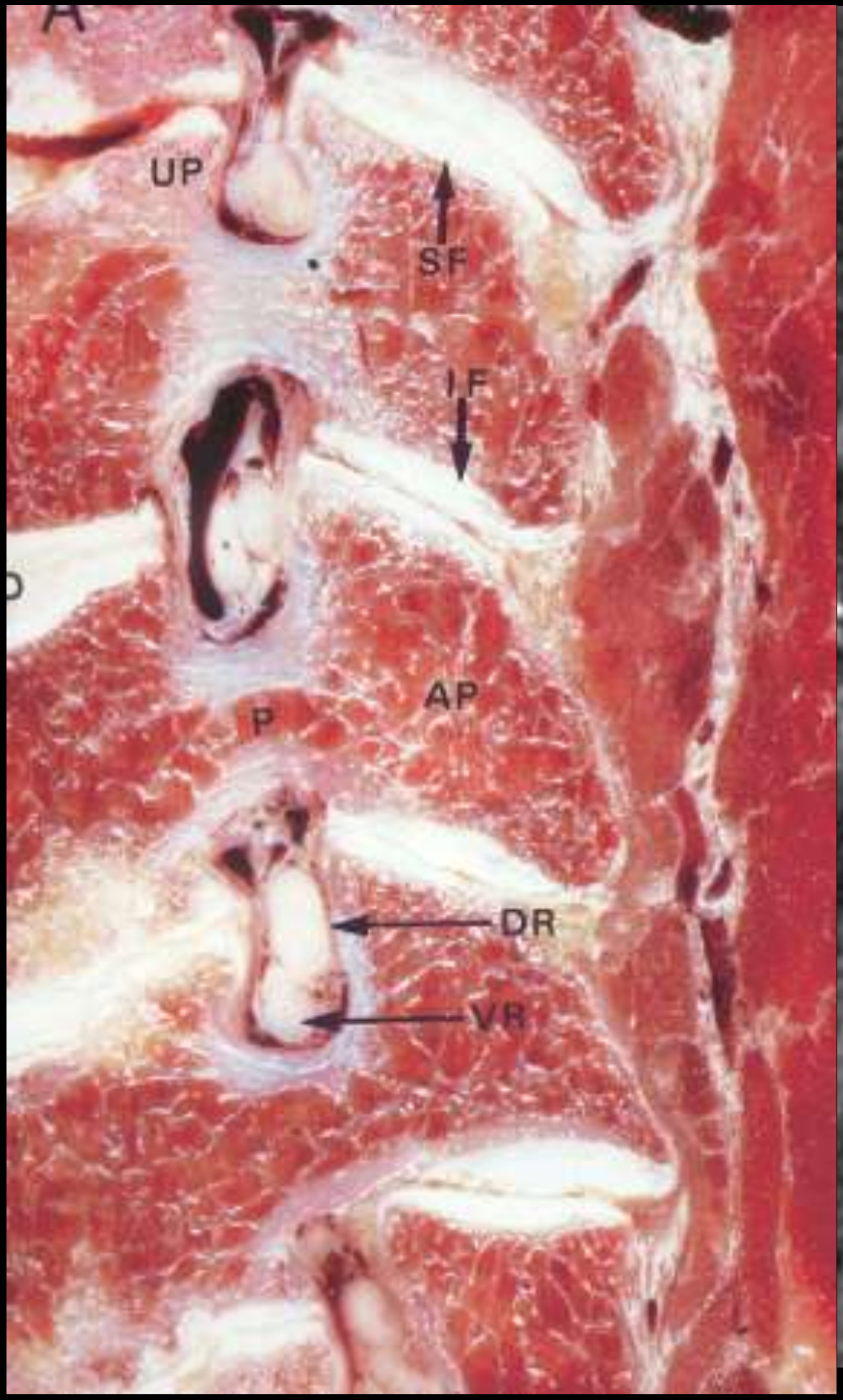

Sagittal Oblique

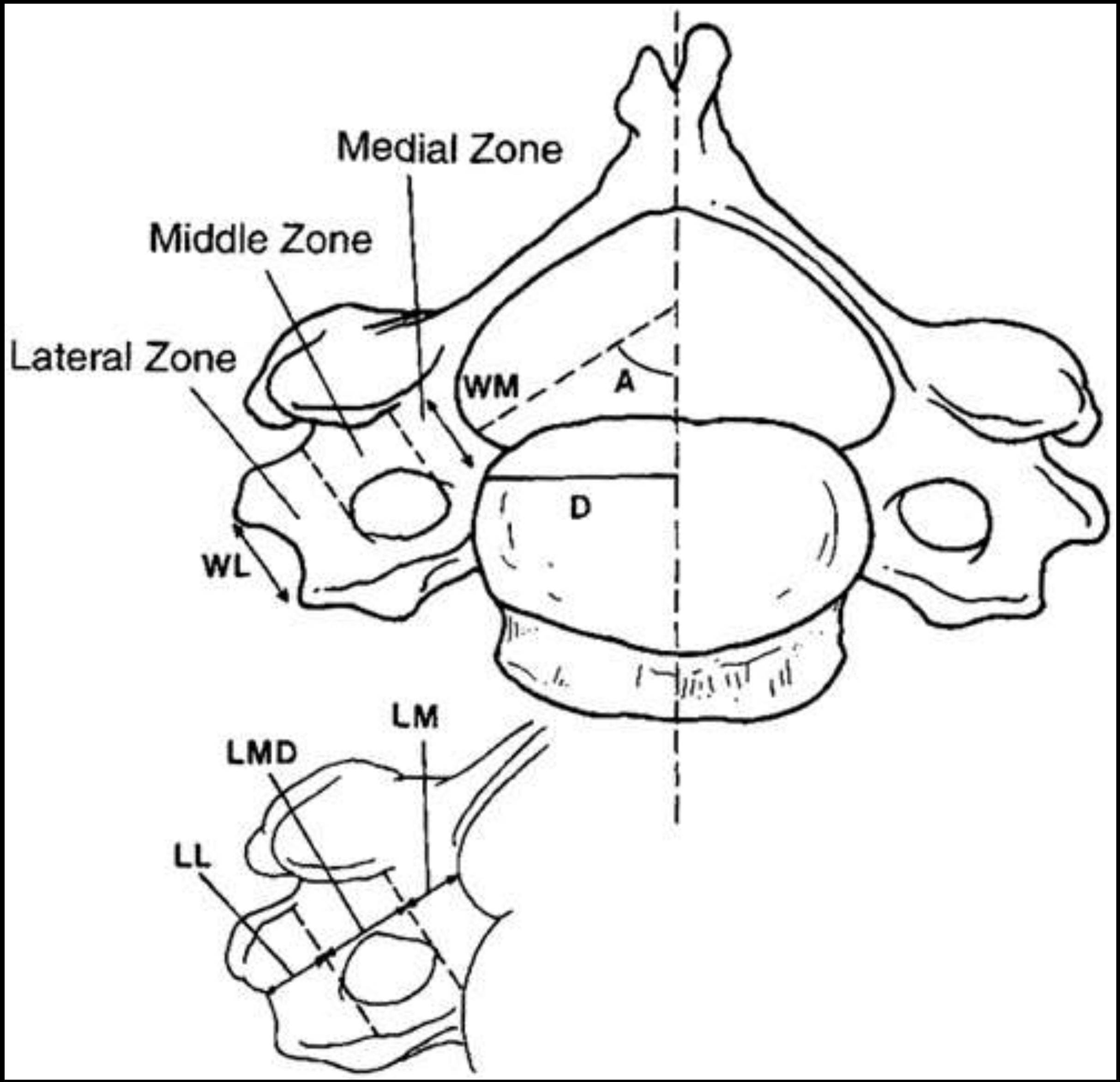

Zones of the cervical neural canal

The shape of the intervertebral foramina approximated a funnel, the entrance zone being the most narrow part and the root sleeves conical, with their takeoff points from the central dural sac being the largest part.

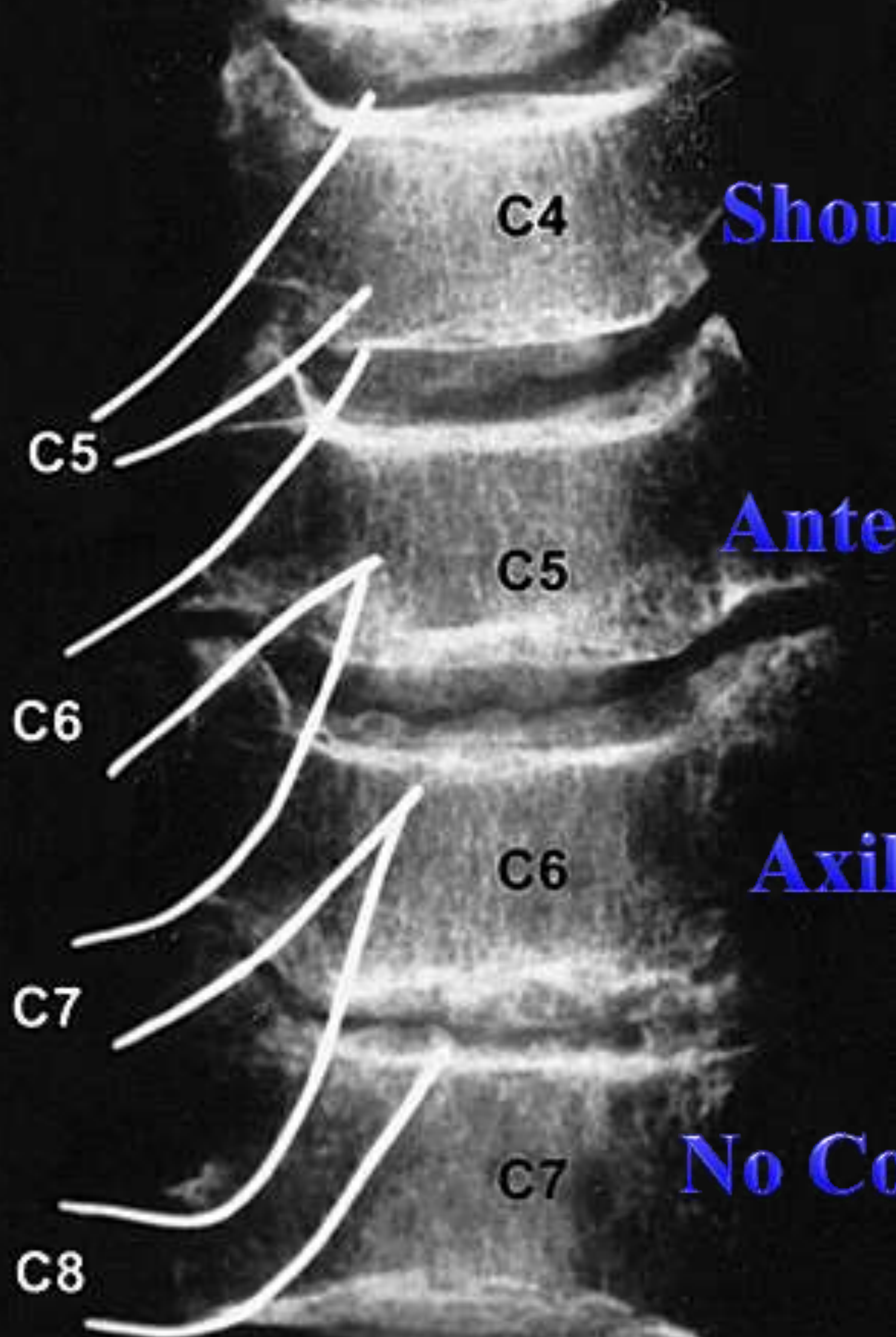

Shoulder

Anterior

Axillary

No Contact

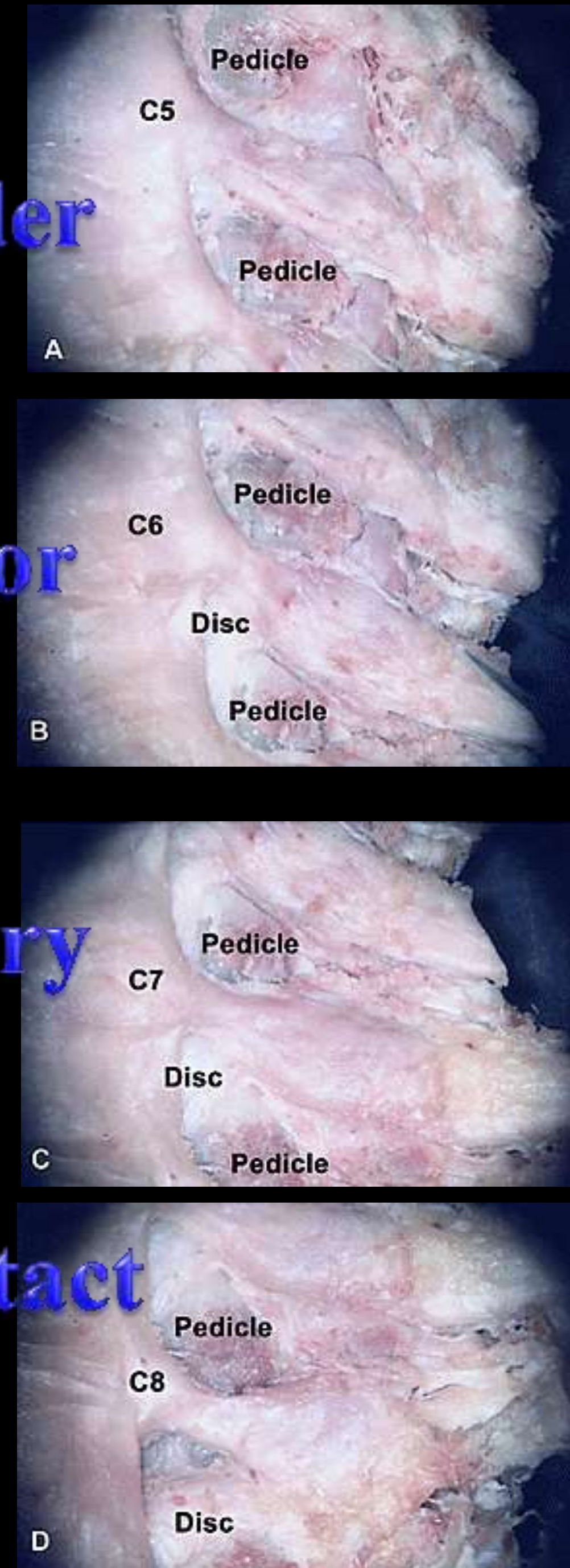

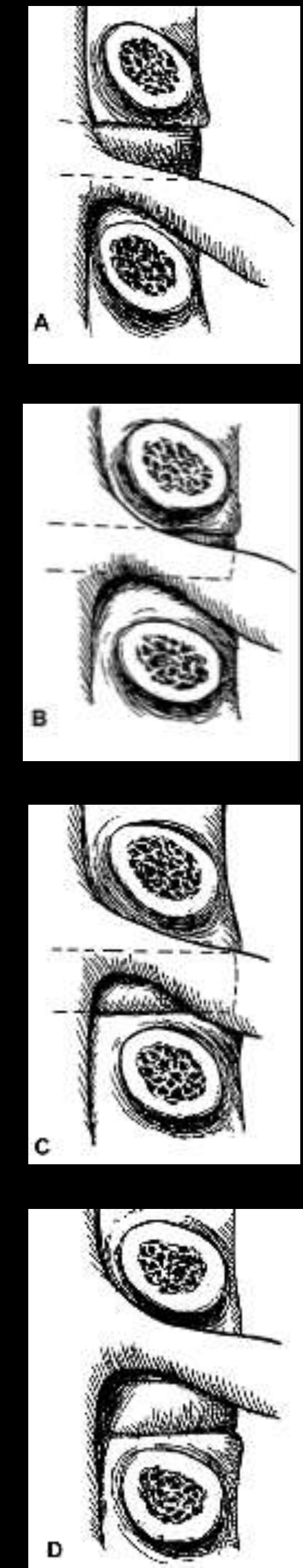

Tanaka N. The Anatomic Relation Among the Nerve Roots, Intervertebral Discs of the Cervical Spine. Spine 2000;25:286-291.

Neural Foramina and Nerve Roots: CT Myelography

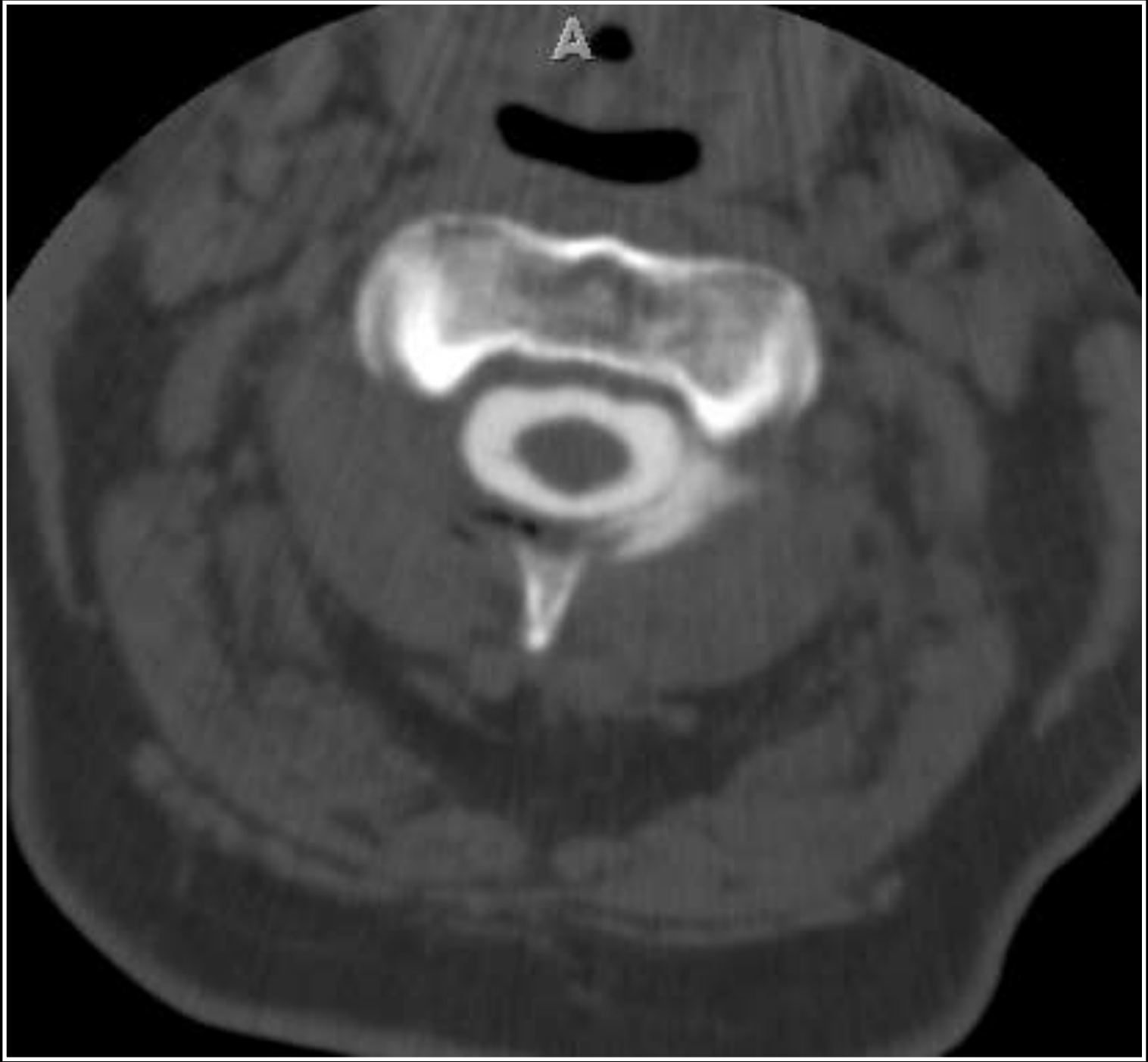

Courtesy of Anna Nidecker and Ari Blitz

Nerve root anatomy: CT Myelography

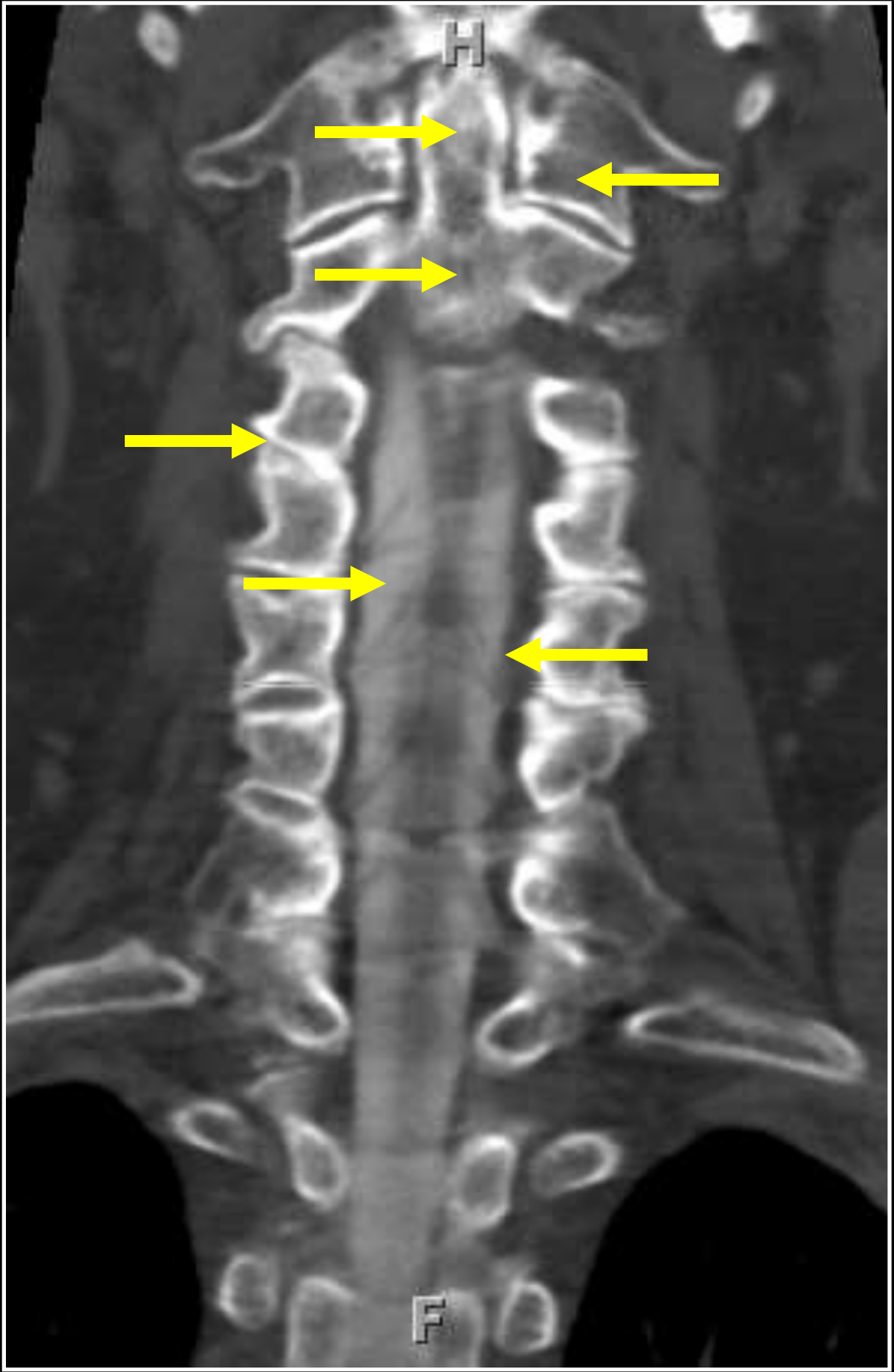

- Coronal (anterior)
  - Ventral rootlets
  - CSF
  - Facet joints
  - Atlas
  - Axis w/dens

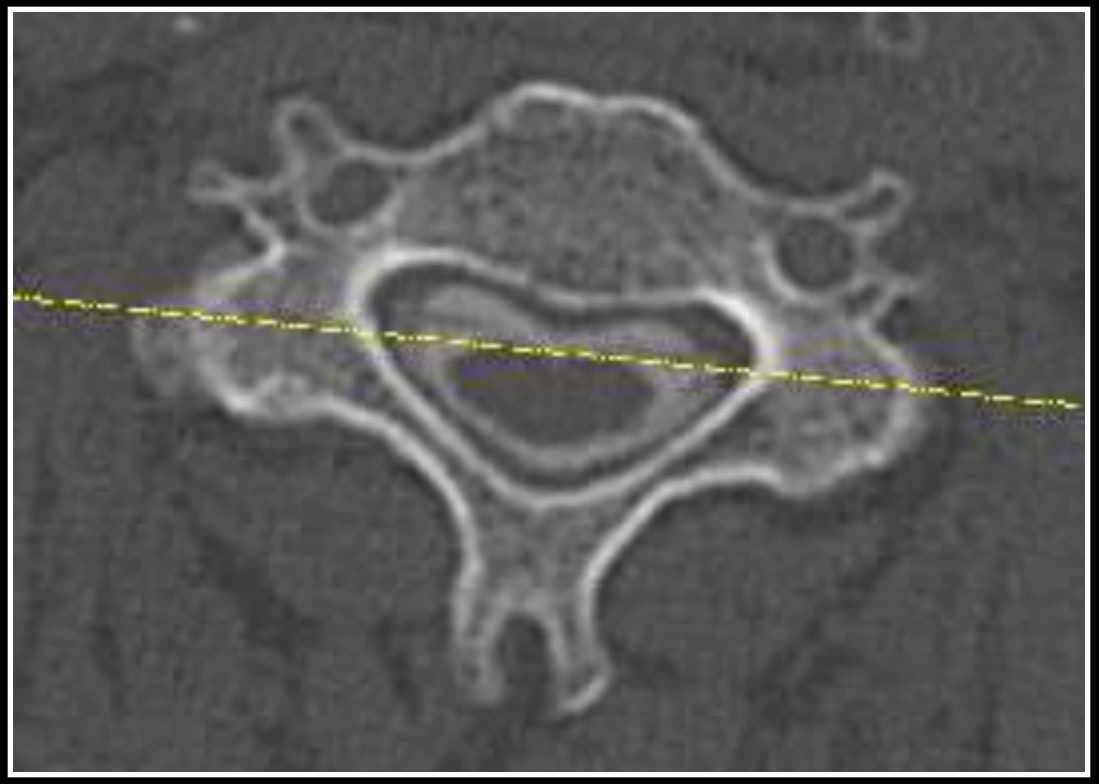

Courtesy of Anna Nidecker and Ari Blitz

Nerve root anatomy: CT Myelography

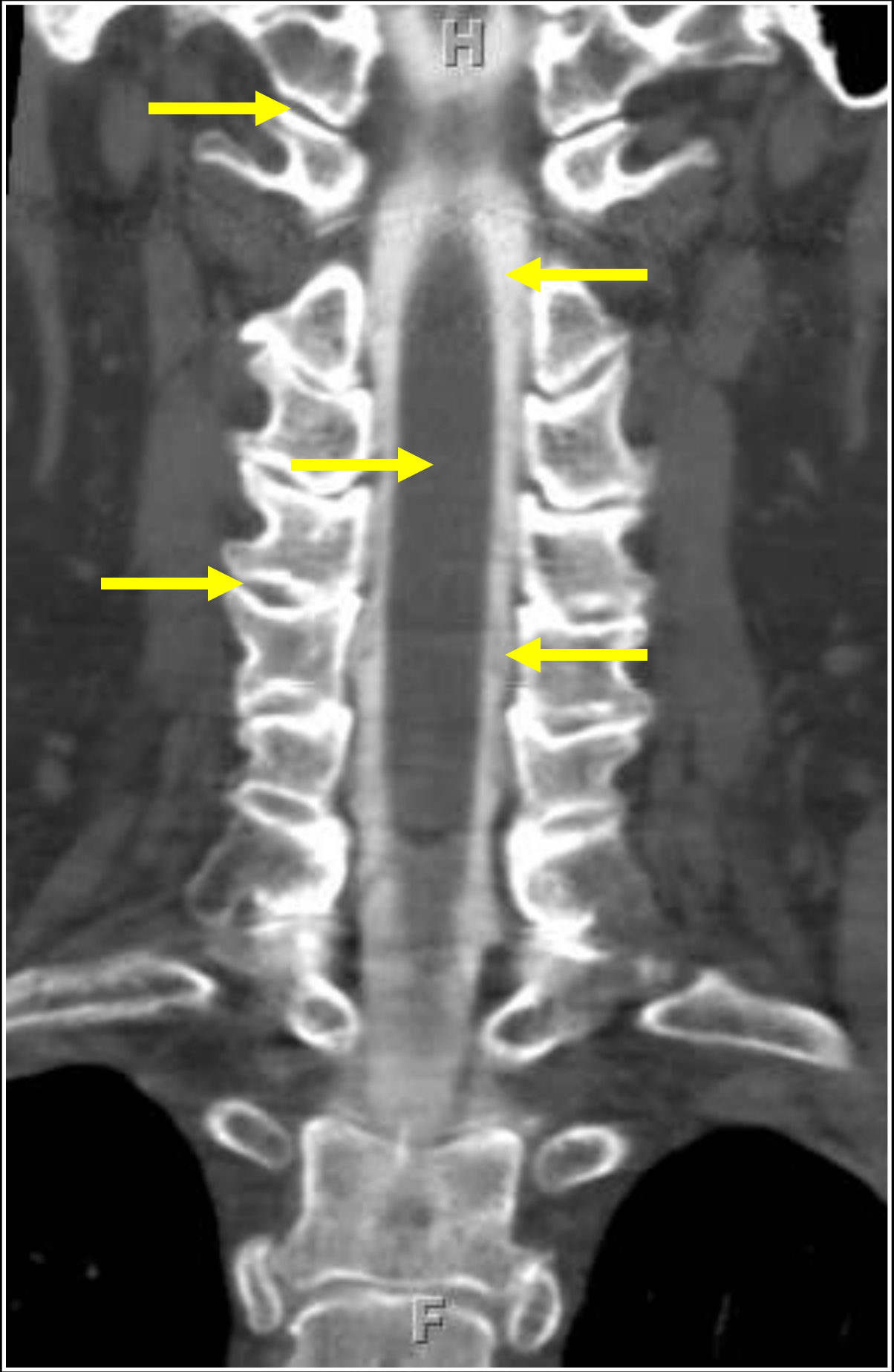

- Coronal (mid/post)
  - Spinal cord
  - Dorsal rootlets
  - CSF
  - Facet joints
  - Atlanto-occipital joint

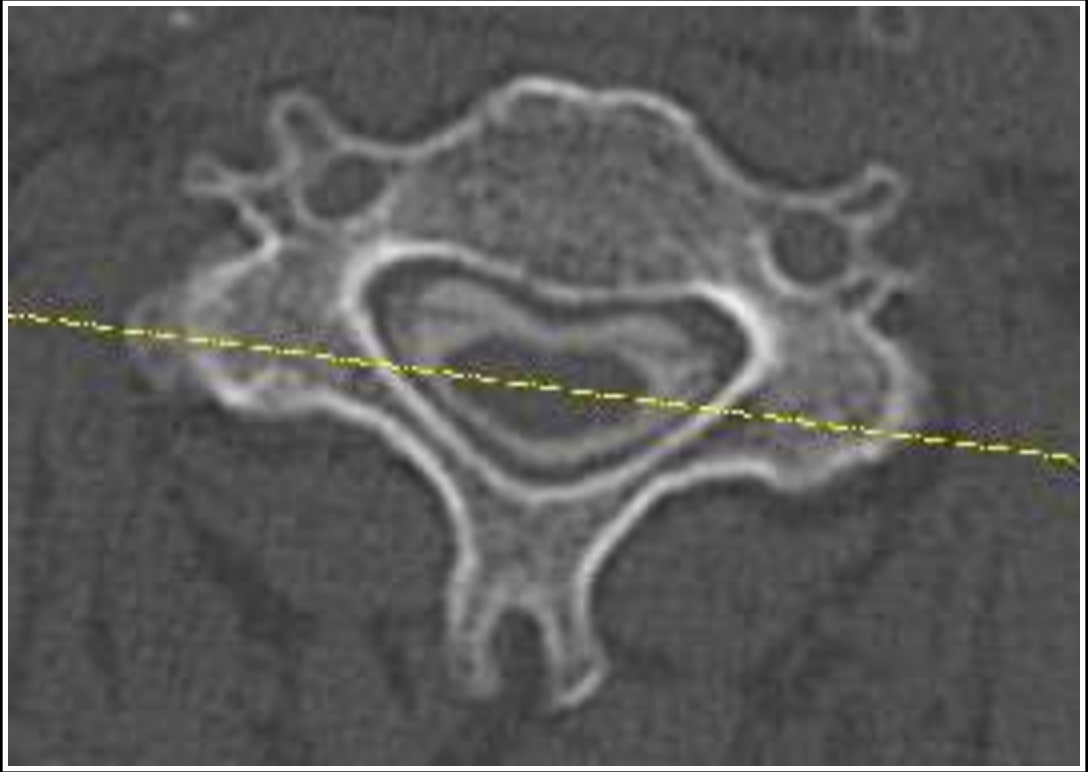

Courtesy of Anna Nidecker and Ari Blitz

Nerve root anatomy: CT Myelography

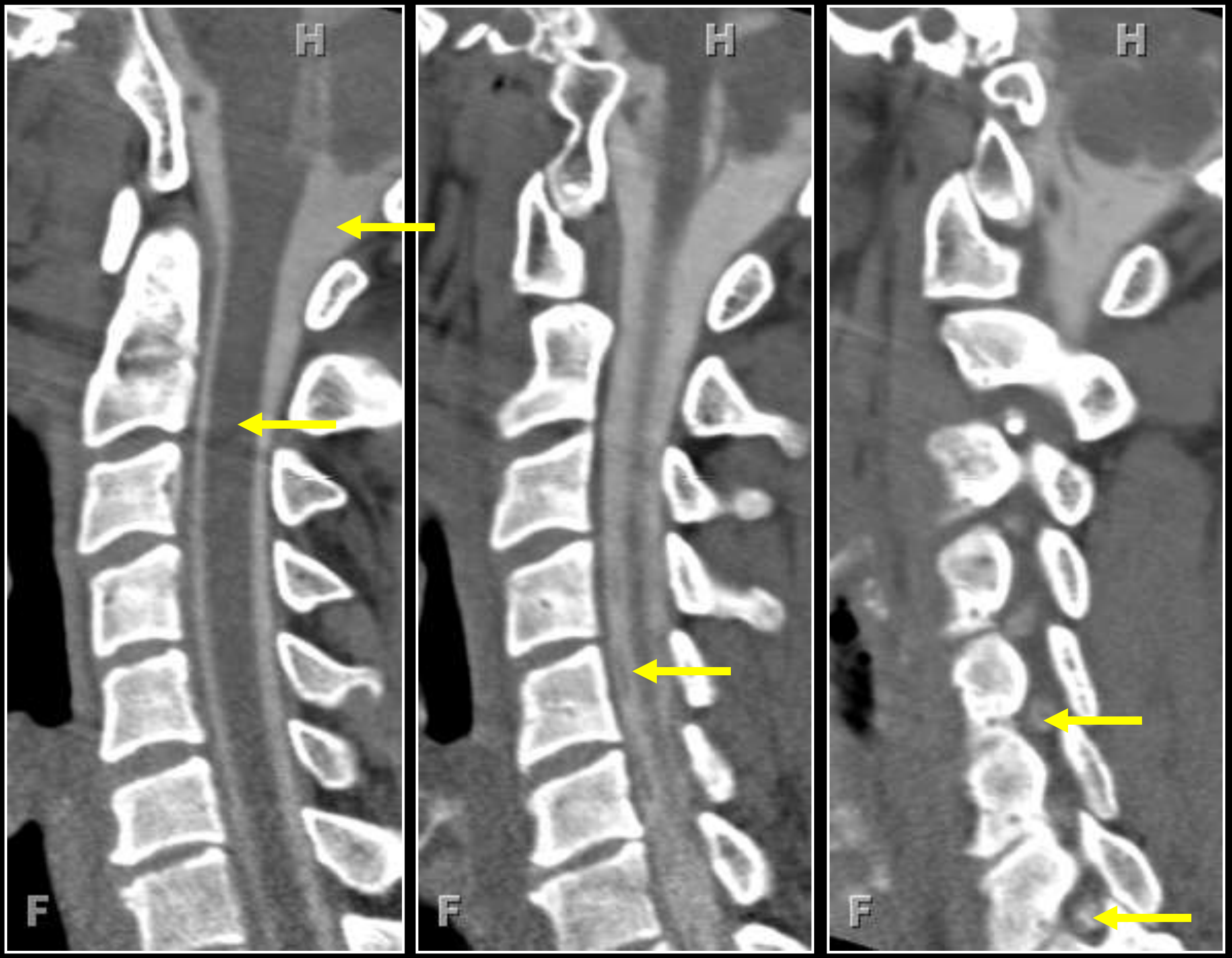

- Sagittal
  - Spinal cord
  - CSF
  - Rootlets
  - Neural foramen
  - Nerve roots

Courtesy of Anna Nidecker and Ari Blitz

Nerve root anatomy: MR

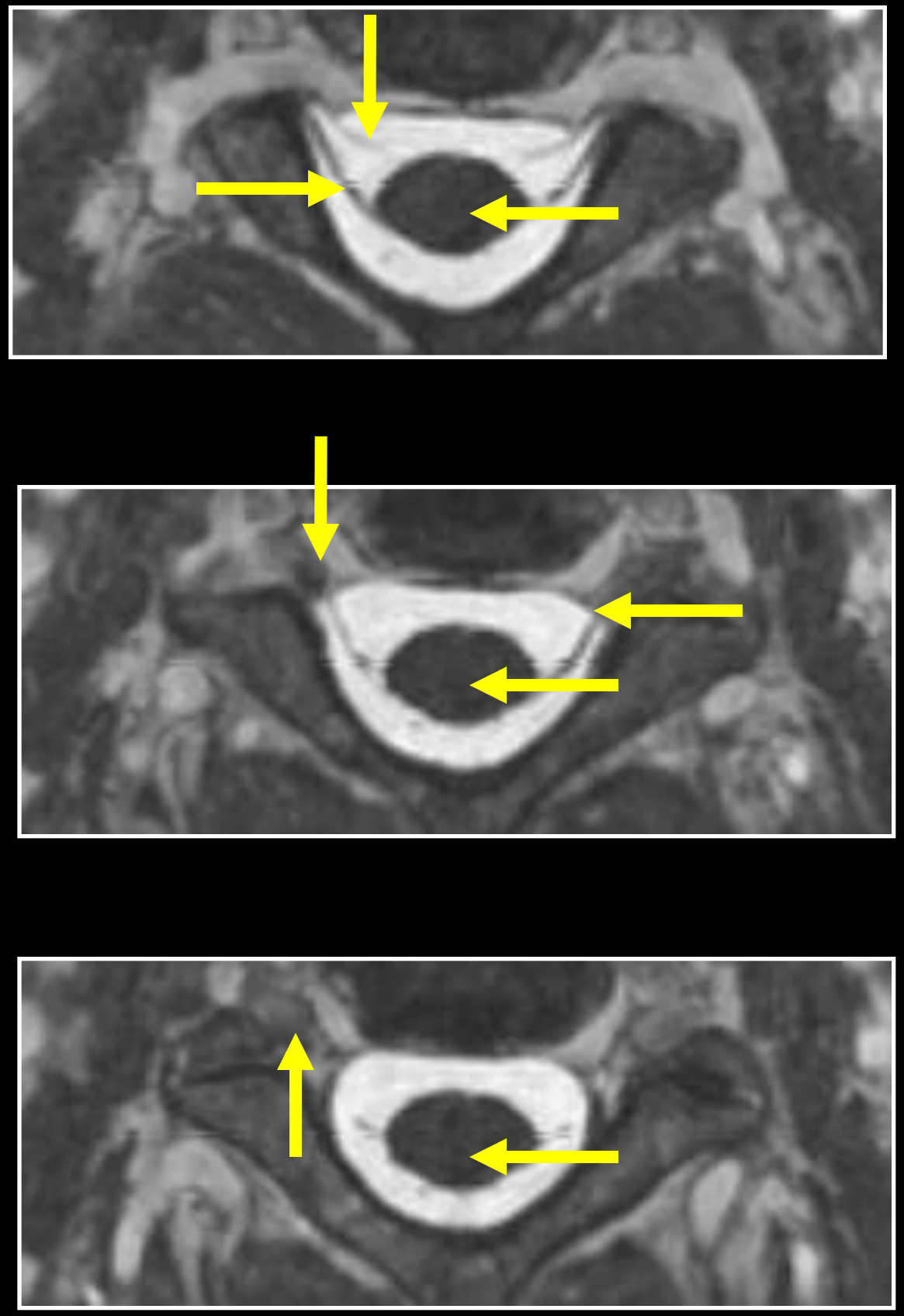

- Axial
  - Spinal cord
  - Dorsal roots
  - Ventral roots
  - Nerve root sleeve
  - Neural foramen
  - Dorsal root ganglion

Courtesy of Anna Nidecker and Ari Blitz

Nerve root anatomy: MR

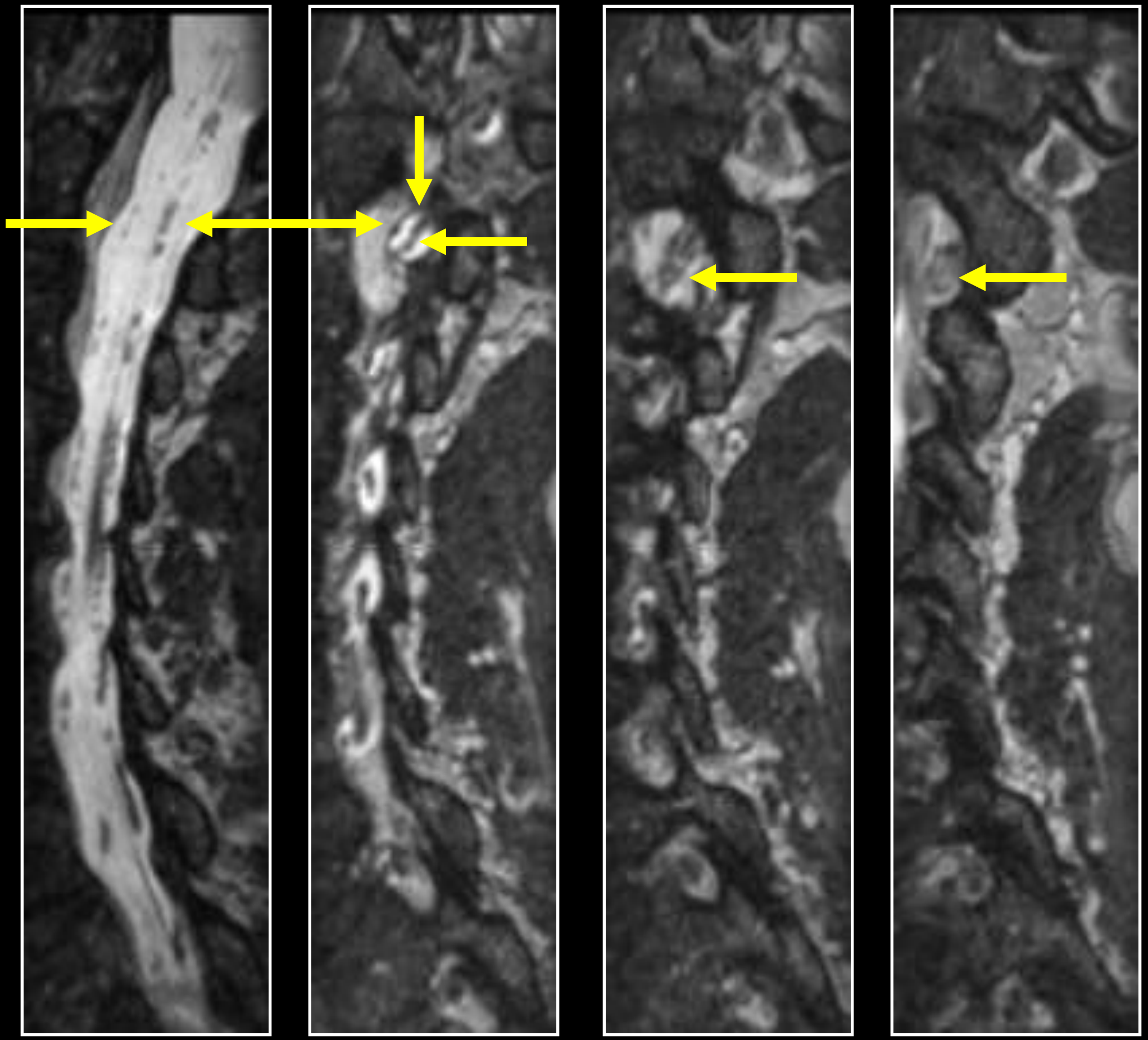

- Sagittal
  - Rootlets
    - Ventral, dorsal
  - Roots
    - Ventral, dorsal
  - Dural sleeve
  - Neural foramen
  - DRG

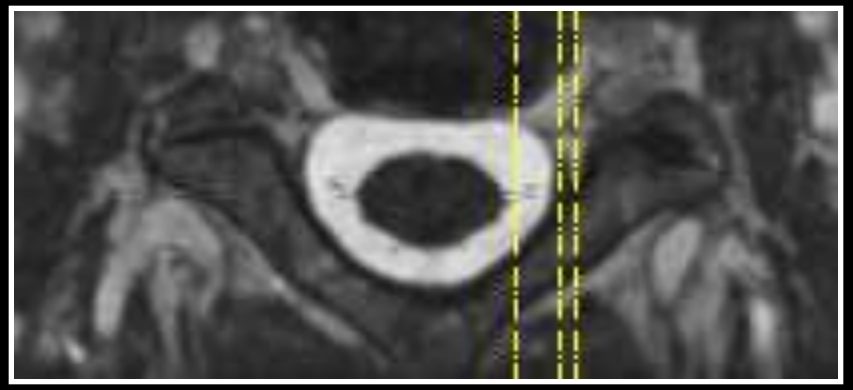

Courtesy of Anna Nidecker and Ari Blitz

Normal Anatomy: Rootlets, Roots

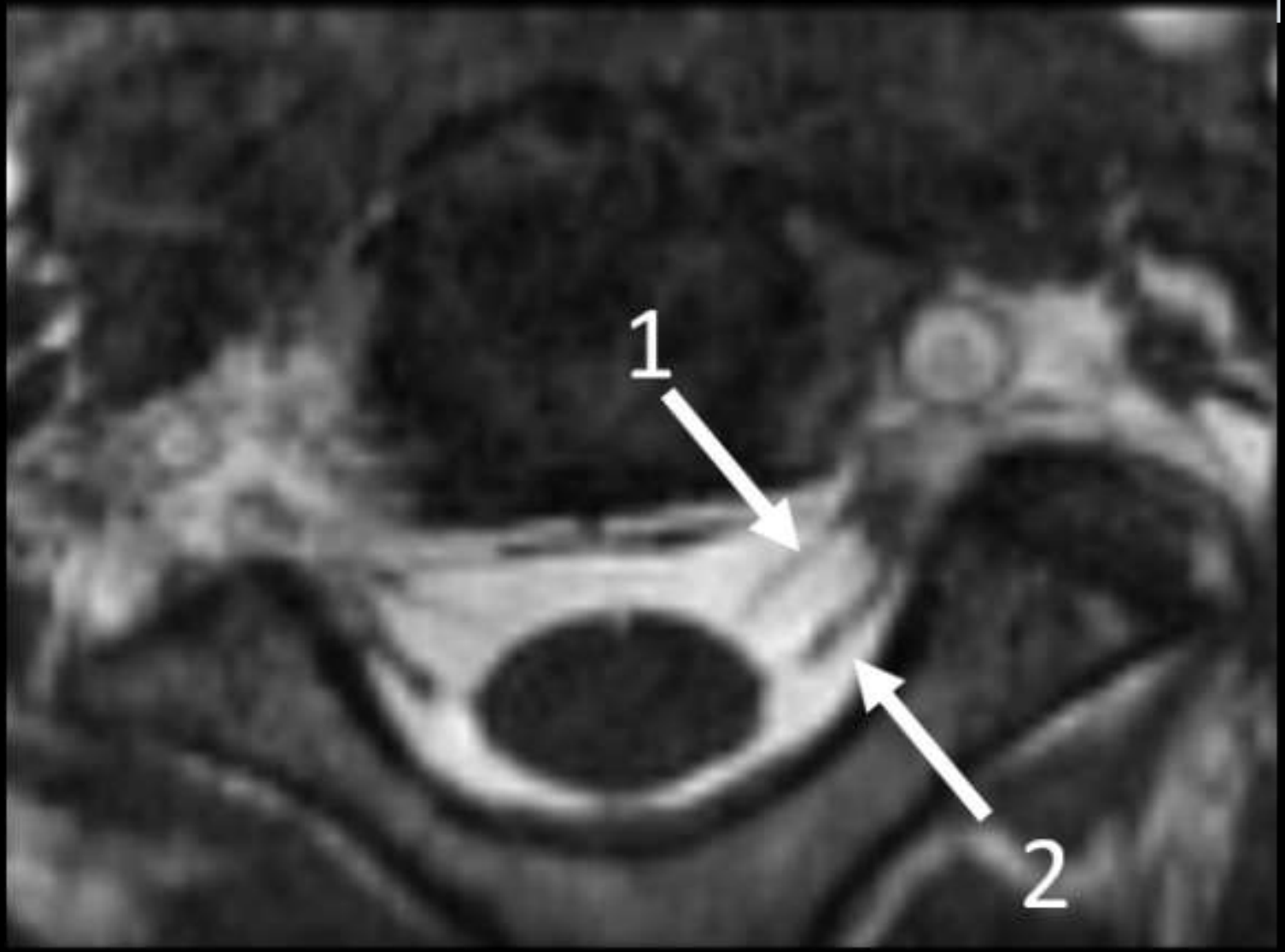

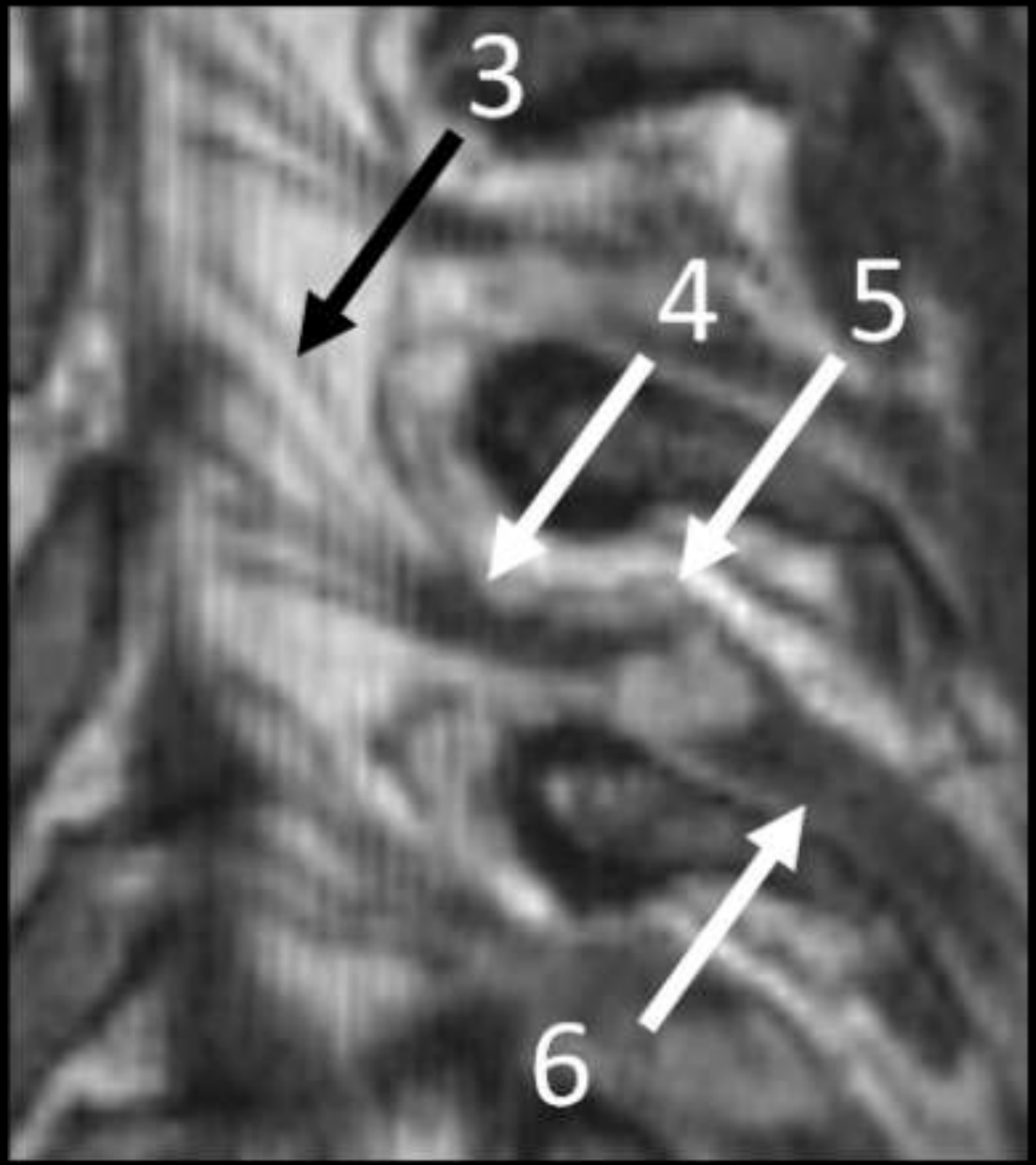

- 1- Ventral rootlet
- 2- Dorsal rootlet
- 3- Rootlets (dorsal)
  - (Aka filum pl. fila)
- 4- Root
- 5- Dorsal root ganglion
- 6- Spinal nerve

Courtesy of Anna Nidecker and Ari Blitz

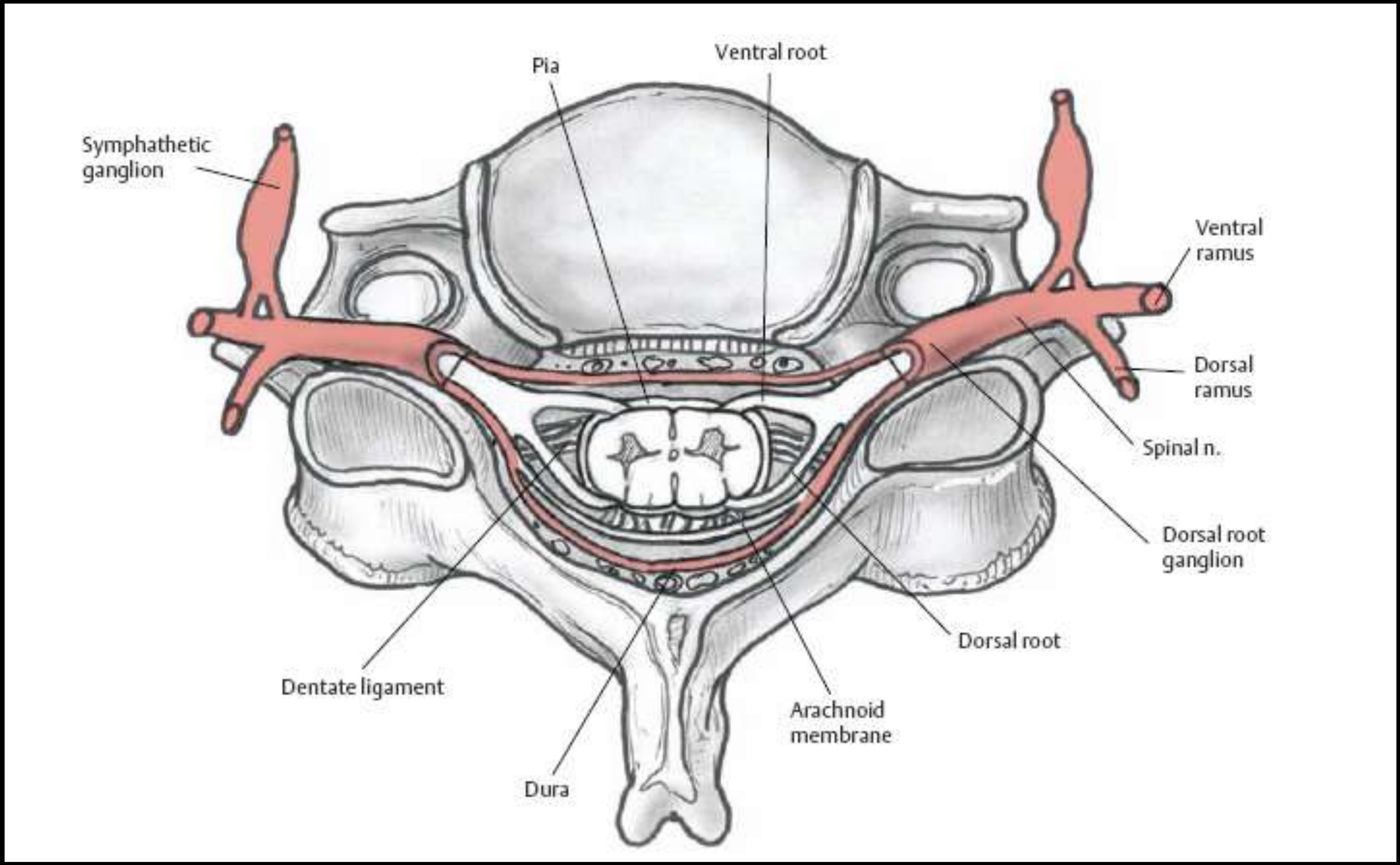

Khanna AJ, ed. MRI for Orthopaedic Surgeons. 2010

DRG, Nerve, Rami

- V- Vertebral artery
- 1- Dorsal root ganglion
- 2- Spinal nerve
- 3- Dorsal Ramus, proximal
- 4- Lateral Ramus, adjacent to facet
- 5- Ventral Ramus

Courtesy of Anna Nidecker and Ari Blitz

Dermatomes
(Nolte fig. 10-4)

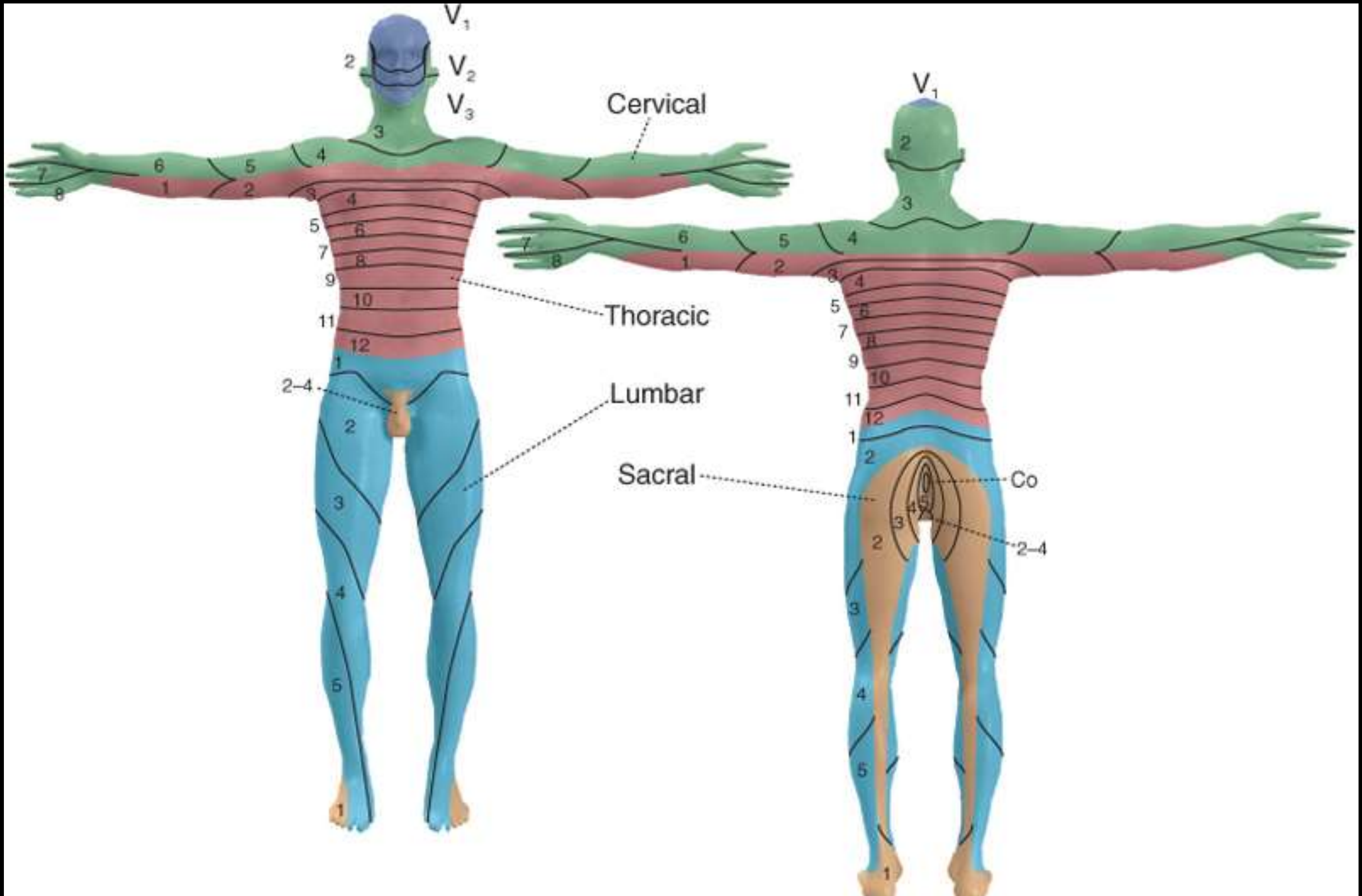

Nolte: The Human Brain.

CERVICAL TRANSFORAMINAL ACCESS

- Consecutive images through C4-5 foramen
- Consider Carotid, Vertebral arteries, Brachial plexus, exiting root
- Arterial contributors to Anterior Spinal Artery entering foramen from ascending or deep cervical cannot be imaged


C5
C6
C7
C8
R
T1

Anatomy Neuroforamen

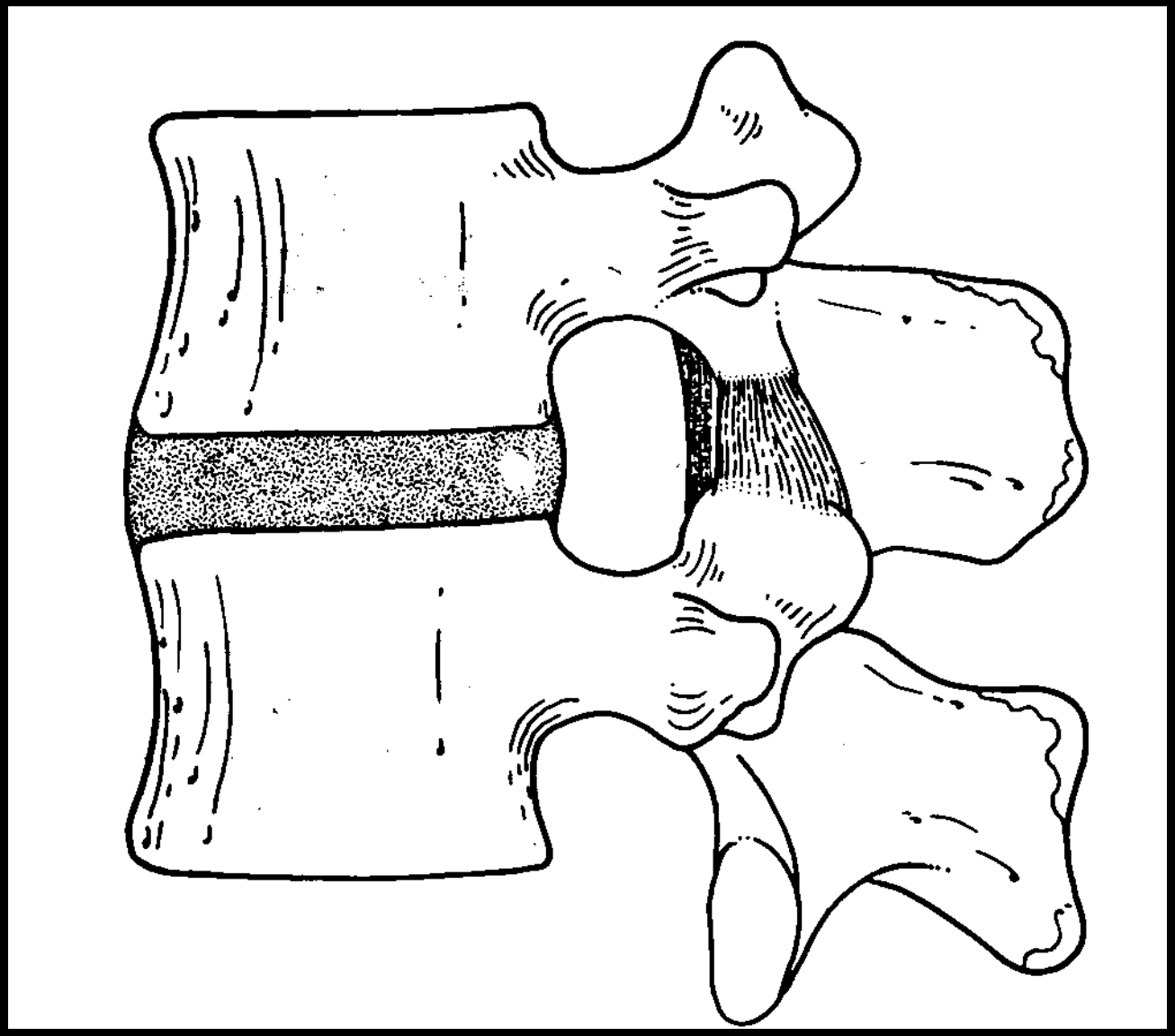

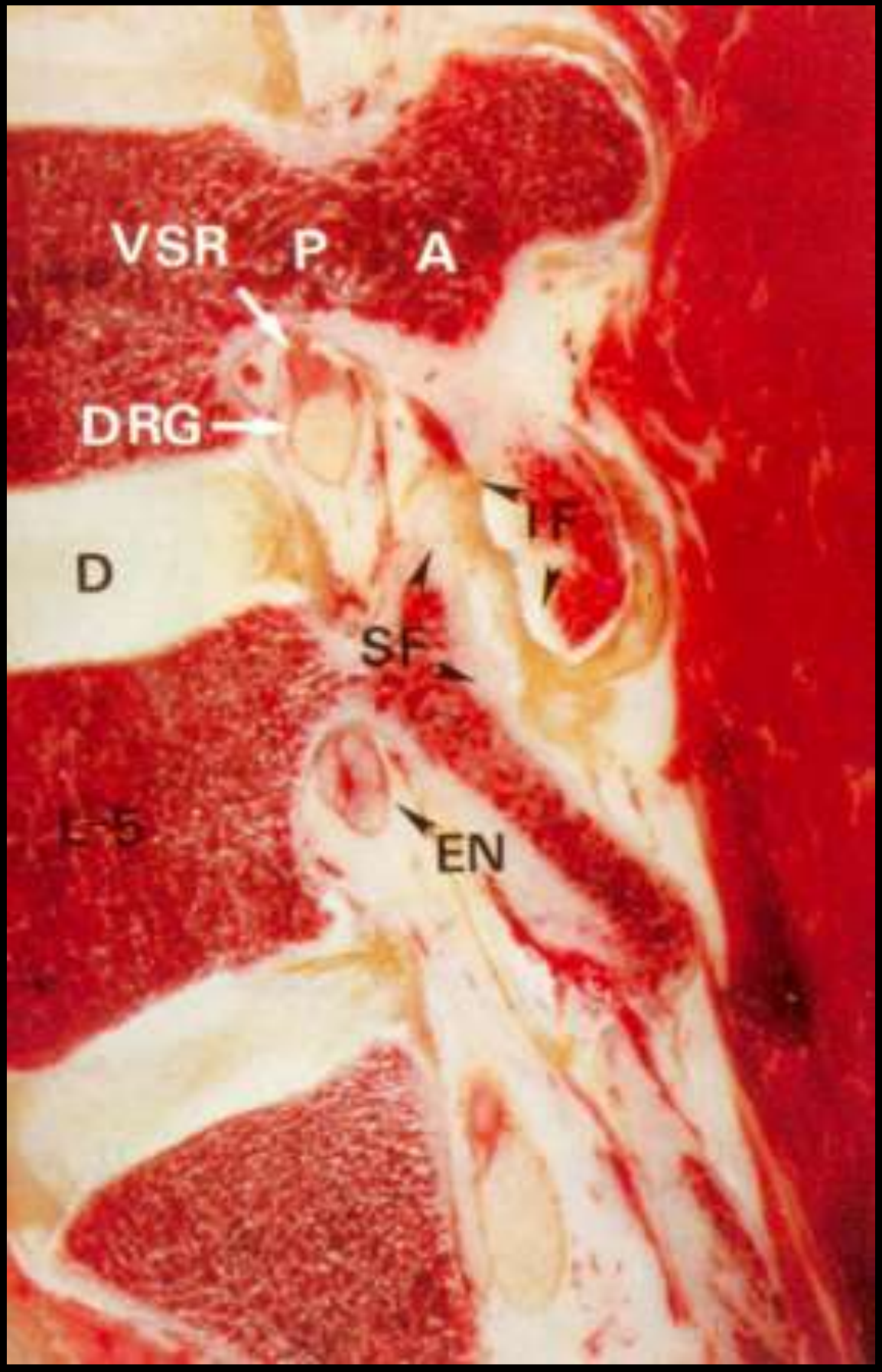

Neuroforamen (Neural Canal)

Borders

- Anterior: vertebral bodies and disc
- Posterior: facet joint and articular processes
- Superior and Inferior: pedicles

T1 sequence

- See low SI nerve passing below pedicle surrounded by high SI fat

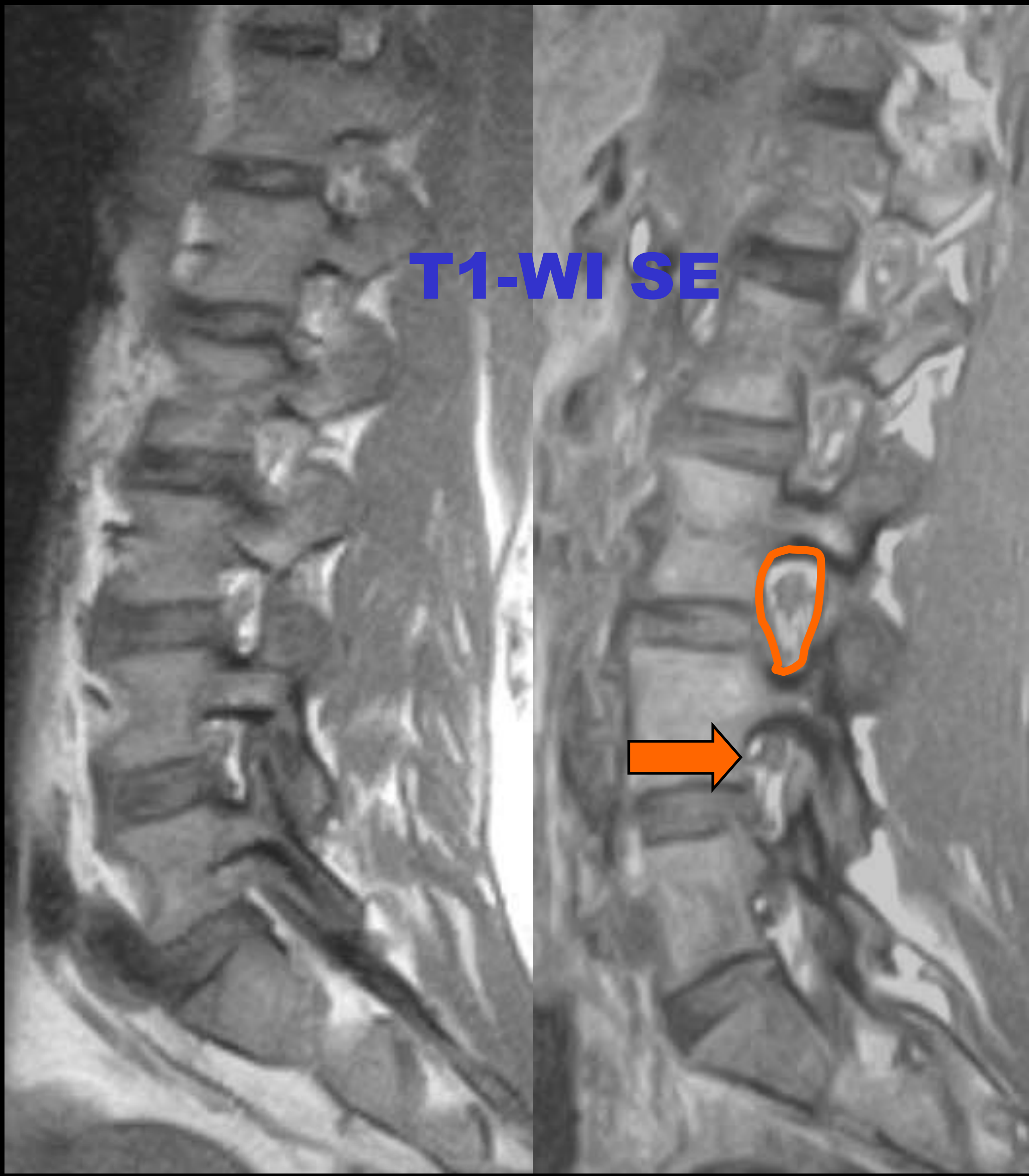

Nerve Roots, Neural Foramen

- CT Myelogram, MRI
- Ventral and dorsal rootlets
- Ventral and dorsal roots as they enter the neural foramen

Contents

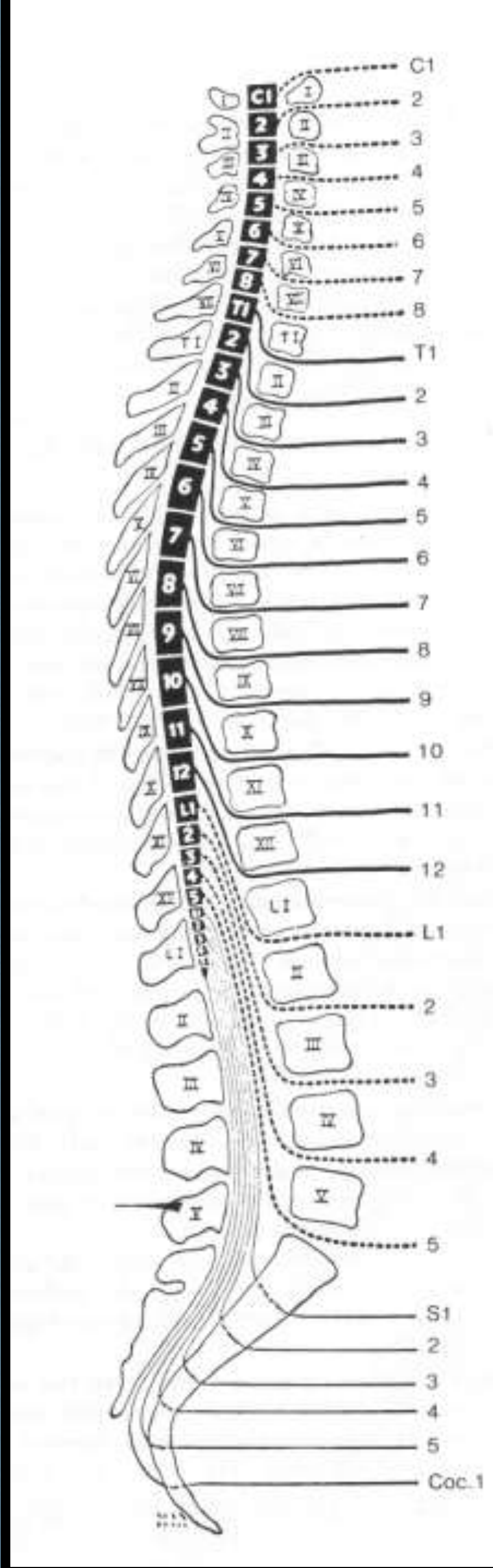

Neural Structures

- 8 cervical nerve roots exit above the similarly numbered vertebral body
- 12 thoracic and 5 lumbar nerve roots exit below the similarly numbered vertebrae
- Nerve roots pass laterally out through NF
- Dorsal root ganglion located within NF
- Normal conus medullaris ends around the level of inferior endplate of L1 in adults

Central Canal Anatomy: MR Spinal Cord

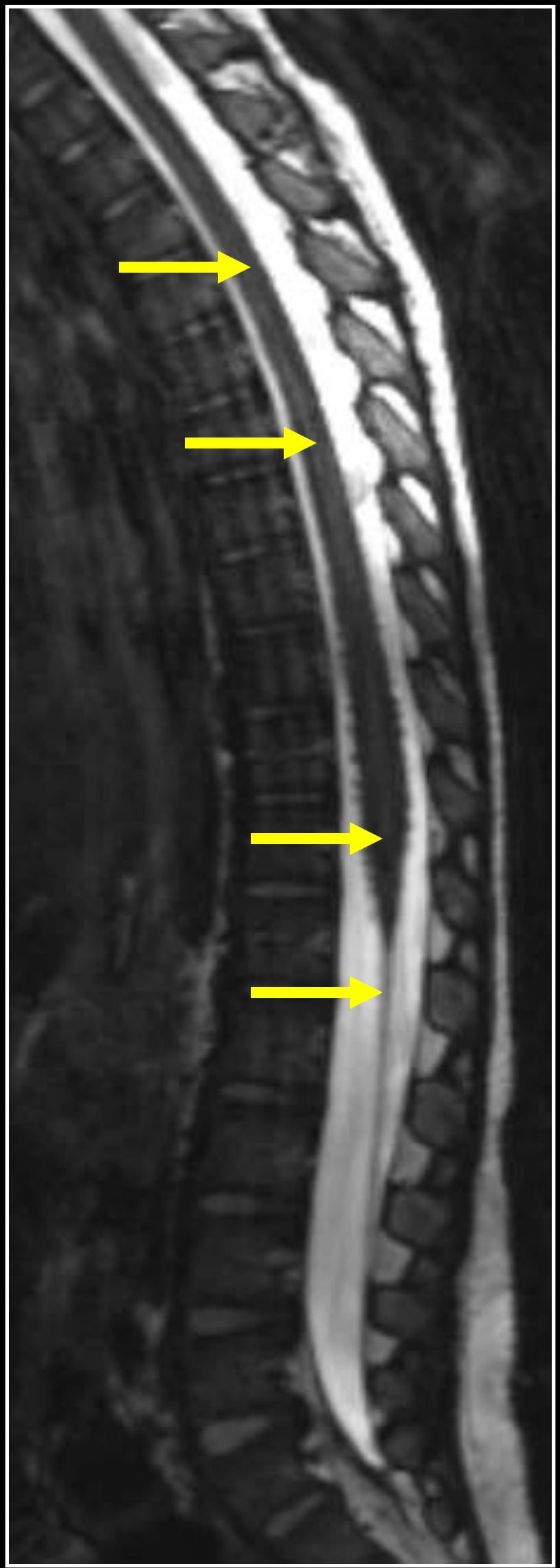

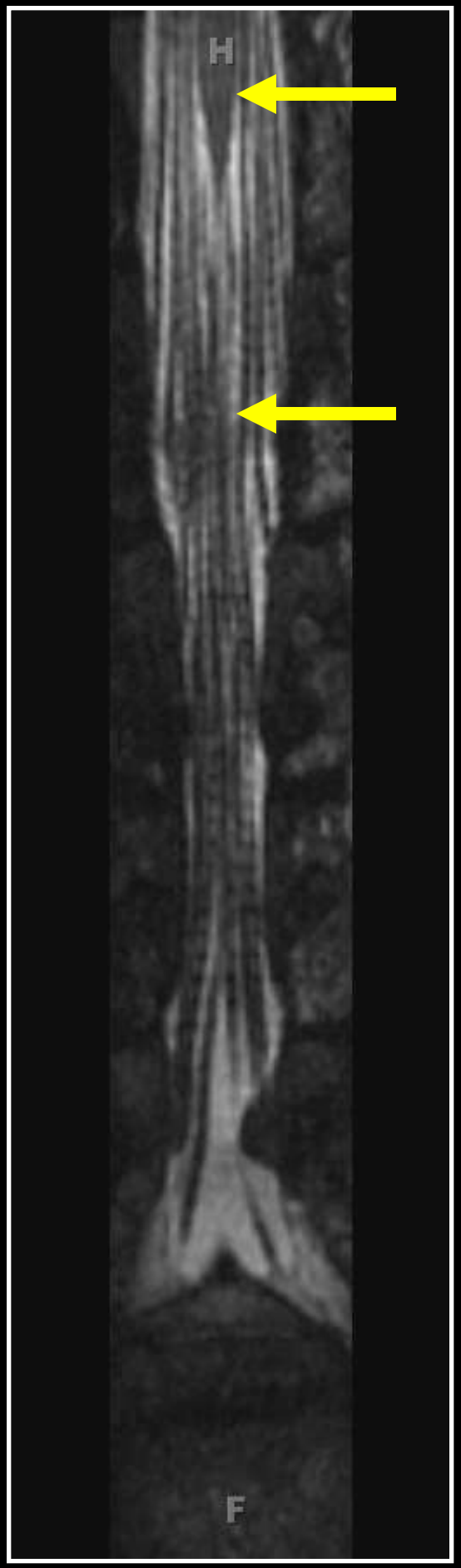

- In cervical and thoracic spine
- Cord tapers to a diamond shaped point (conus medullaris)
- Conus typically ends between T12-L2
- Below this are the cauda equina (“horses tail” of lumbar, sacral, coccygeal nerve roots)
- Filum terminale – a strand of connective tissue extending inferiorly from the conus

Cross sectional spine anatomy

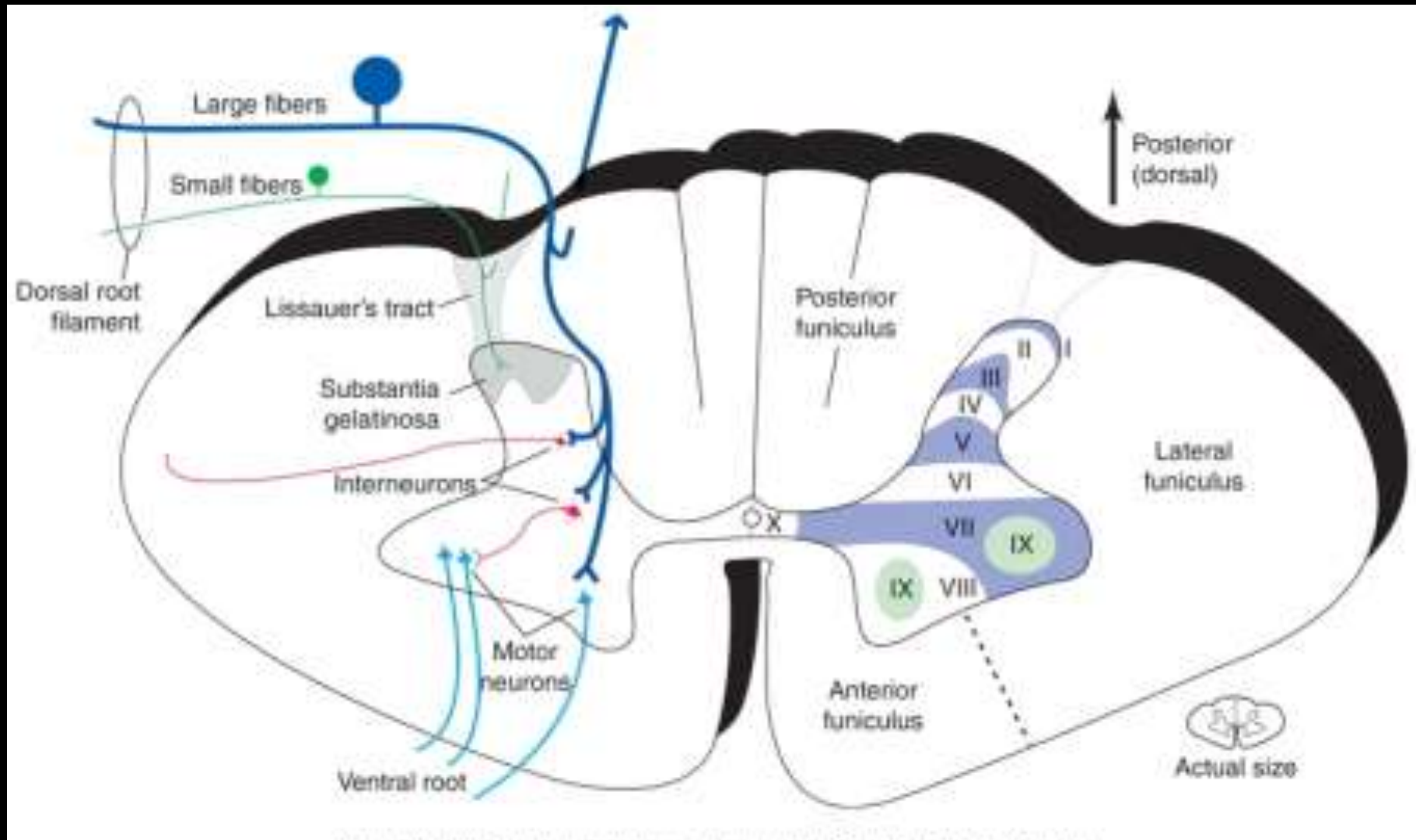

(Modified from Nolte J: The human brain, ed 5, St. Louis, 2002, Mosby.)



(Nolte Atlas Fig 02-01)

Central canal anatomy: MR Spinal Cord

- *In contrast to brain, gray matter is inside while white matter is outside*
- Gray matter is formed by columns (“horns”) of cell bodies:
  - Ventral horn – short, thick, multipolar motor neurons
  - Dorsal horn – narrow, receives sensory axons from DRG

Courtesy of Anna Nidecker and Ari Blitz

Central canal anatomy: MR Spinal Cord

- Three white matter columns (funiculi):
  - Dorsal, ventral, lateral
- Descending motor, ascending sensory tracts mostly lateral, ventral funiculi
- Position, discriminative touch in dorsal funiculi

Courtesy of Anna Nidecker and Ari Blitz

Spinal Cord

- CT myelogram, MRI
- Ends between T12 and L2, most commonly L1-L2
- Conus is distal-most aspect, diamond shaped, which is attached to lower dura via thin fibrous band (filum terminale)
- Cauda equina nerve roots below conus
- Gray matter, white matter
- CT Myelogram, MRI
- Ventral and dorsal rootlets
- Ventral and dorsal roots as they enter the neural foramen
- Artery of Adamkiewicz

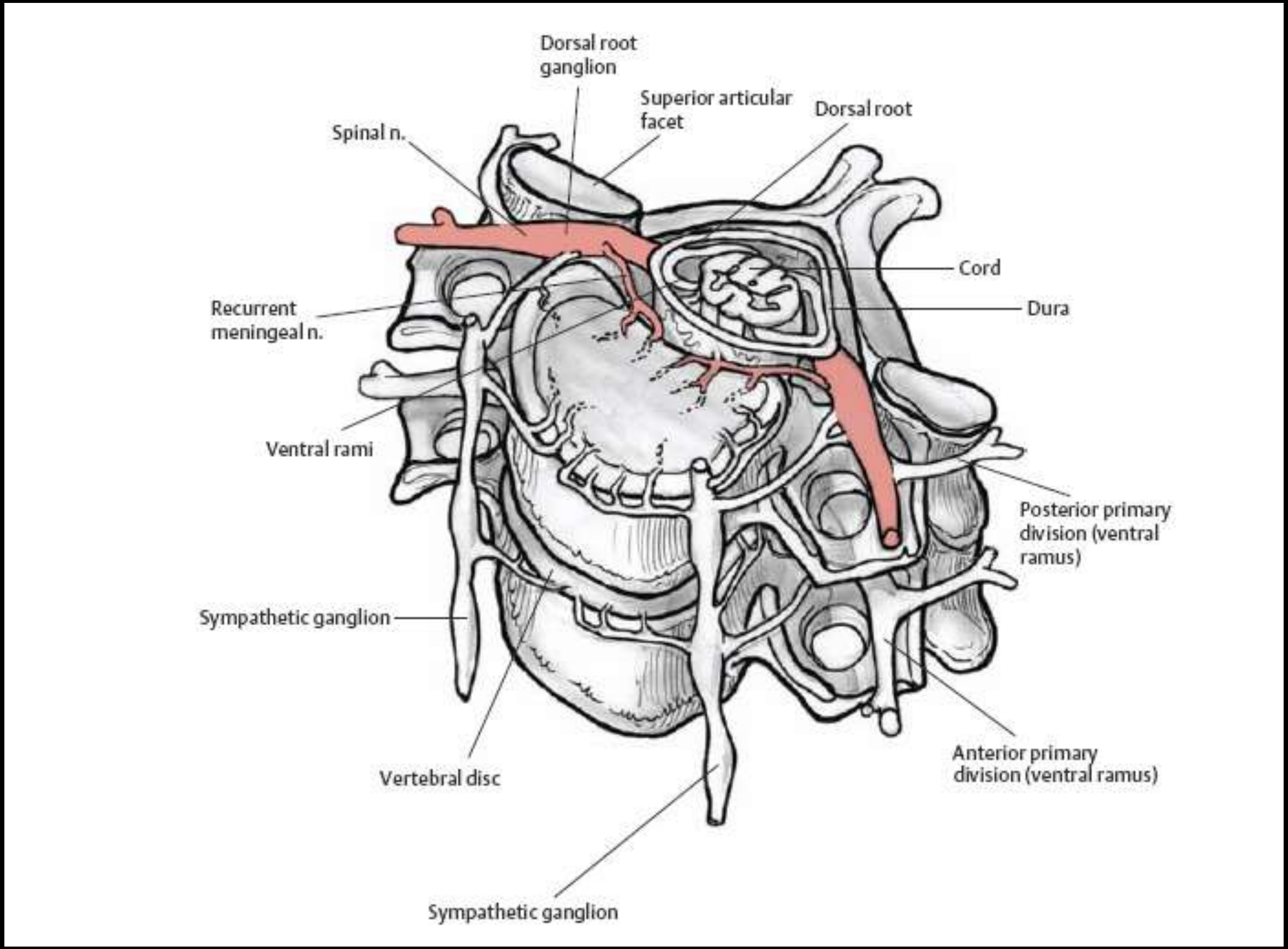

Khanna AJ, ed. MRI for Orthopaedic Surgeons. 2010


ACHIAL
HAL
3-19:20:47-STD-1.3.12.2.1107.5.2.36.40123
965, M, 44Y
10
2.34
N
Johns Hopkins Hospital
syngo MR B17
Cor>Tra -4
>Sag 2

Evaluation of the brachial plexus

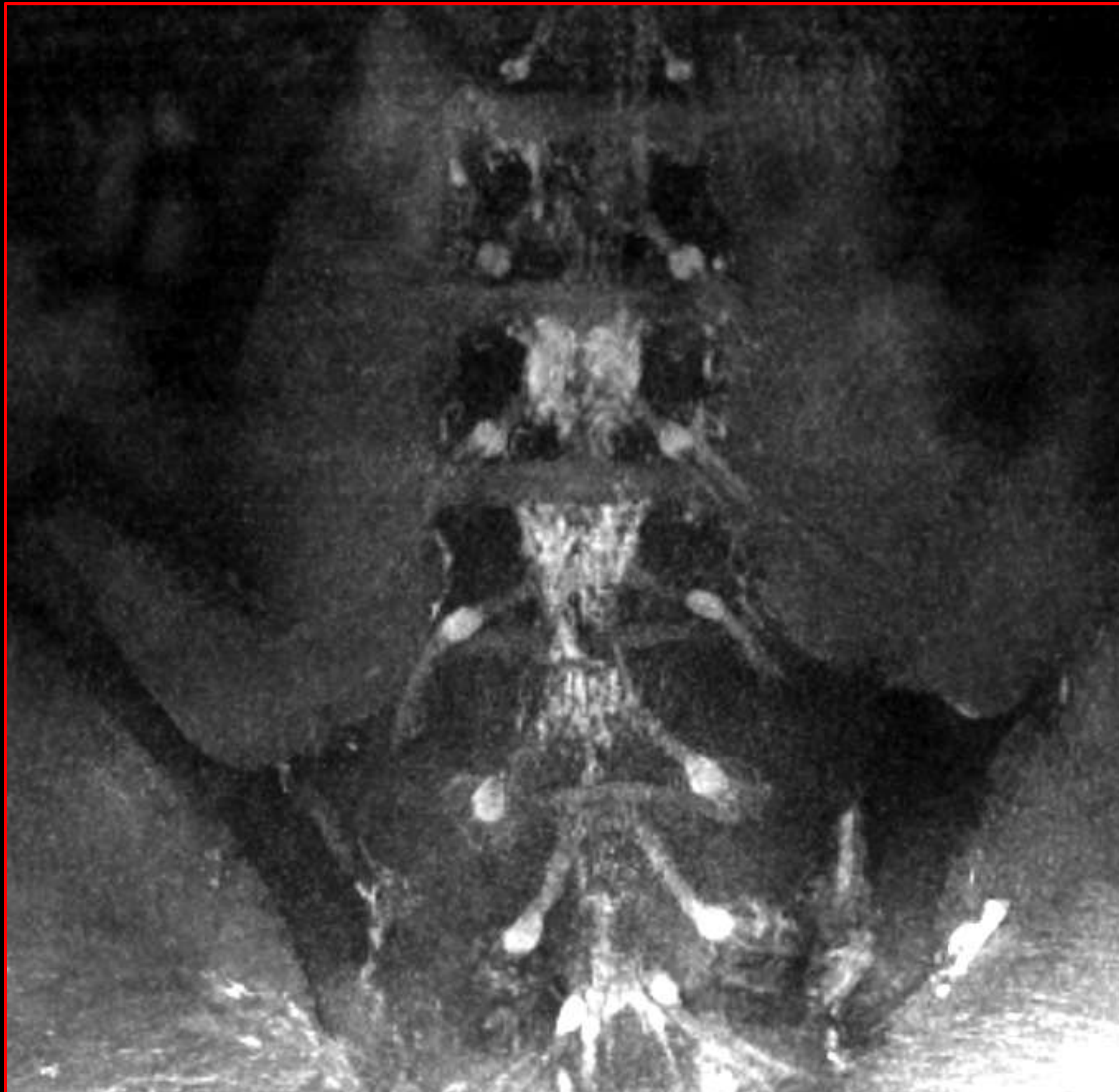

3D DW PSIF

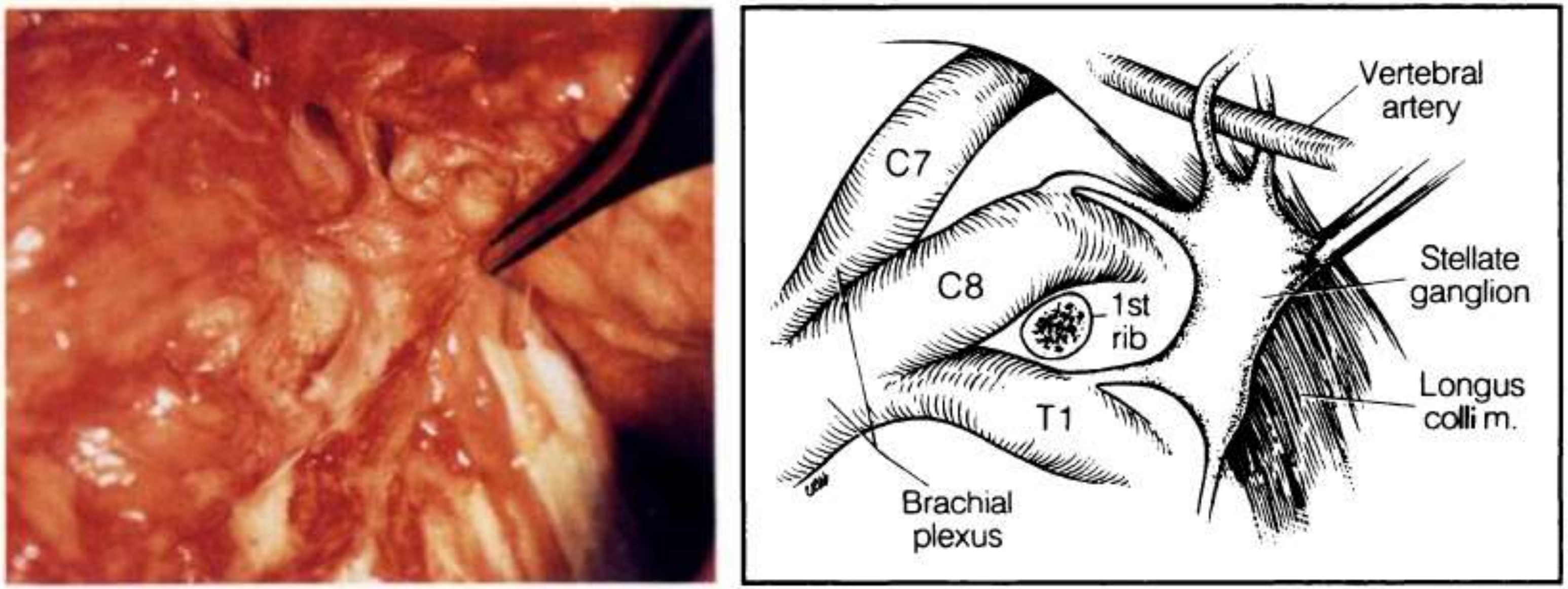

A **B**

Fig. 2.—*A*, Photograph of dissected specimen shows right stellate ganglion in situ retracted anteriorly by a forceps. First rib has been transected and lateral portion removed.

***B*, Drawing shows structures seen in *A*.**

Stellate Ganglion

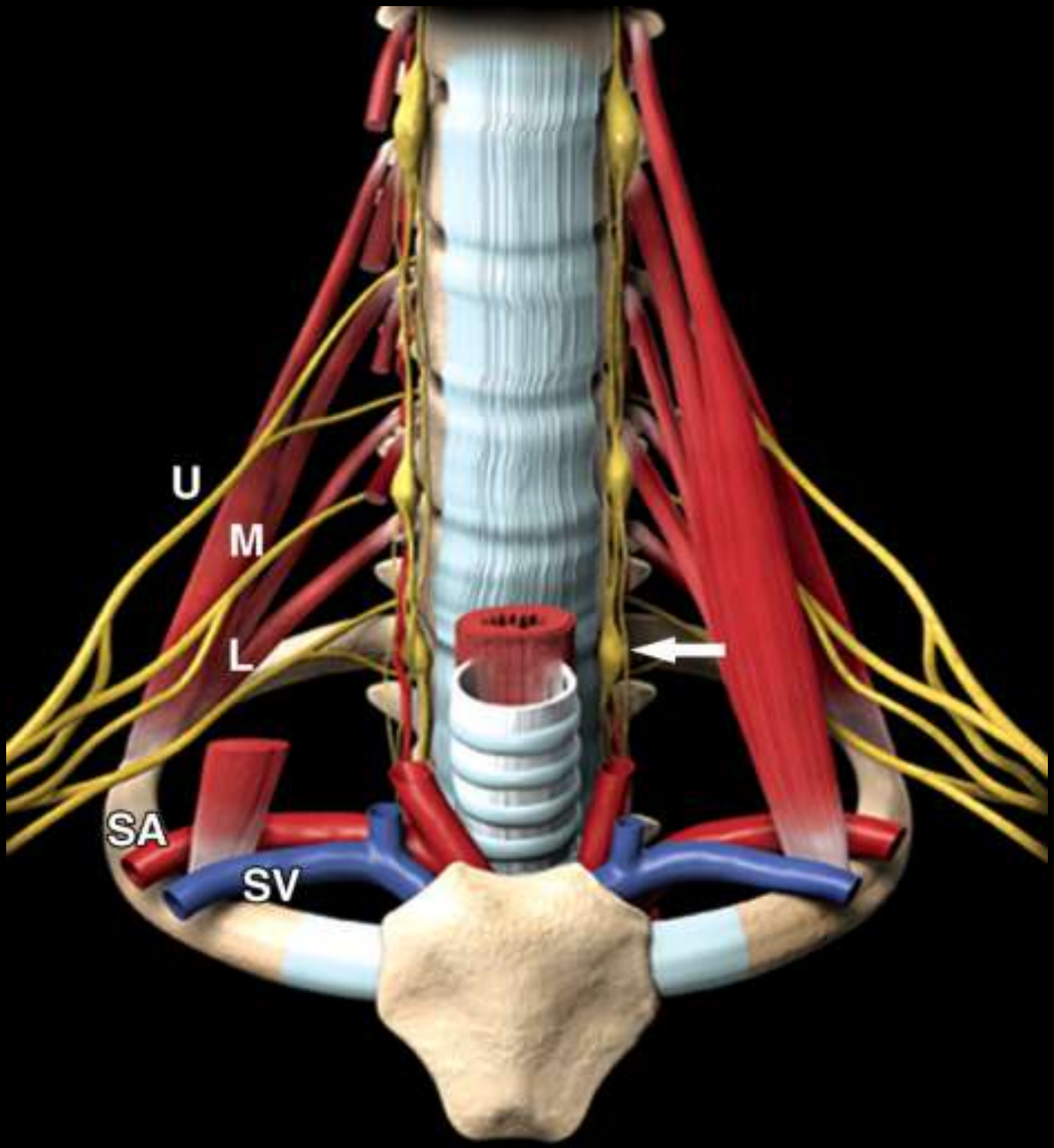

Bruzzi, J. F. et al. Radiographics 2008;28:551-560

Cervical Sympathetic Block
Stellate Ganglion

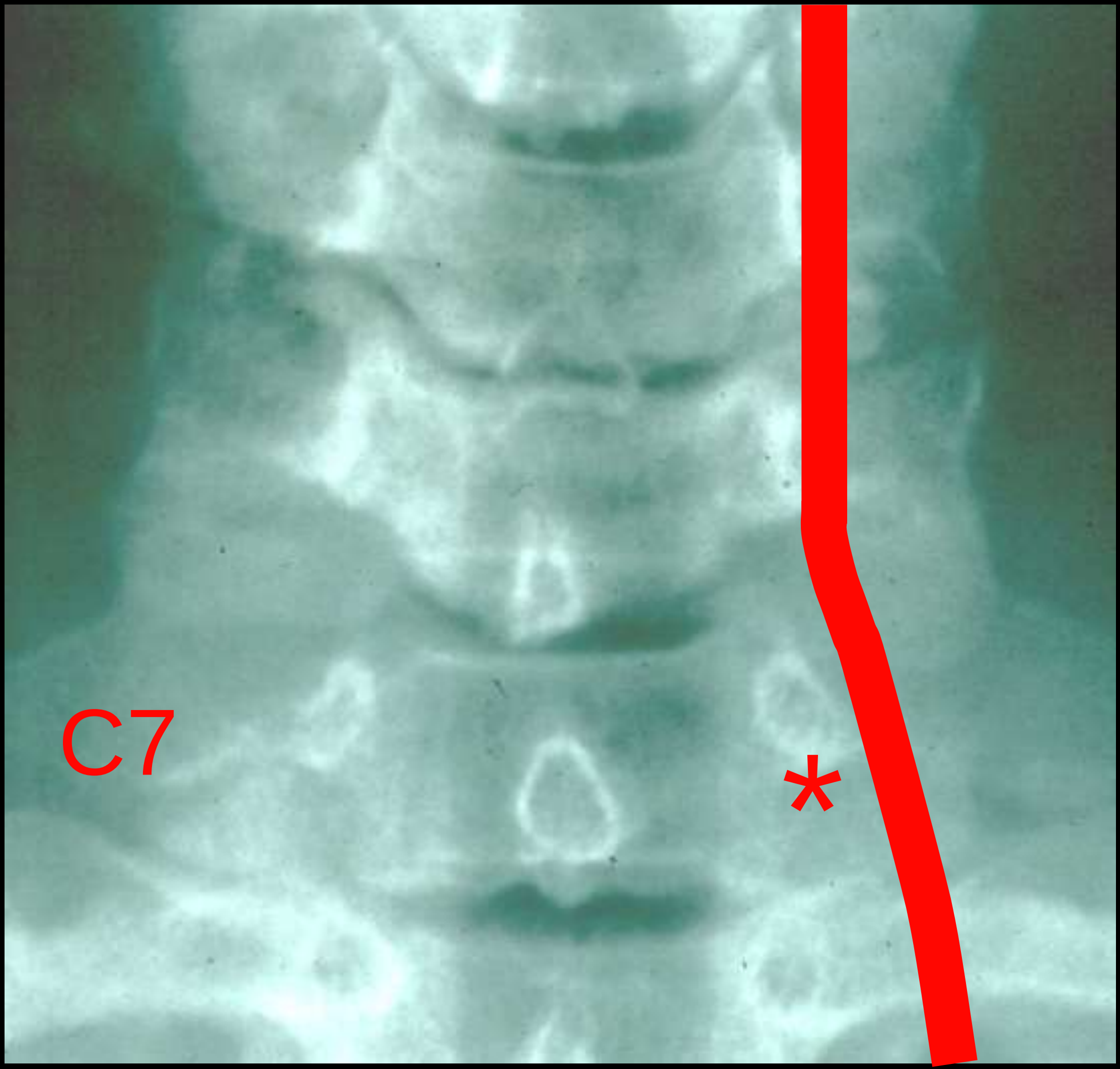

Cervical Sympathetic Block Stellate Ganglion

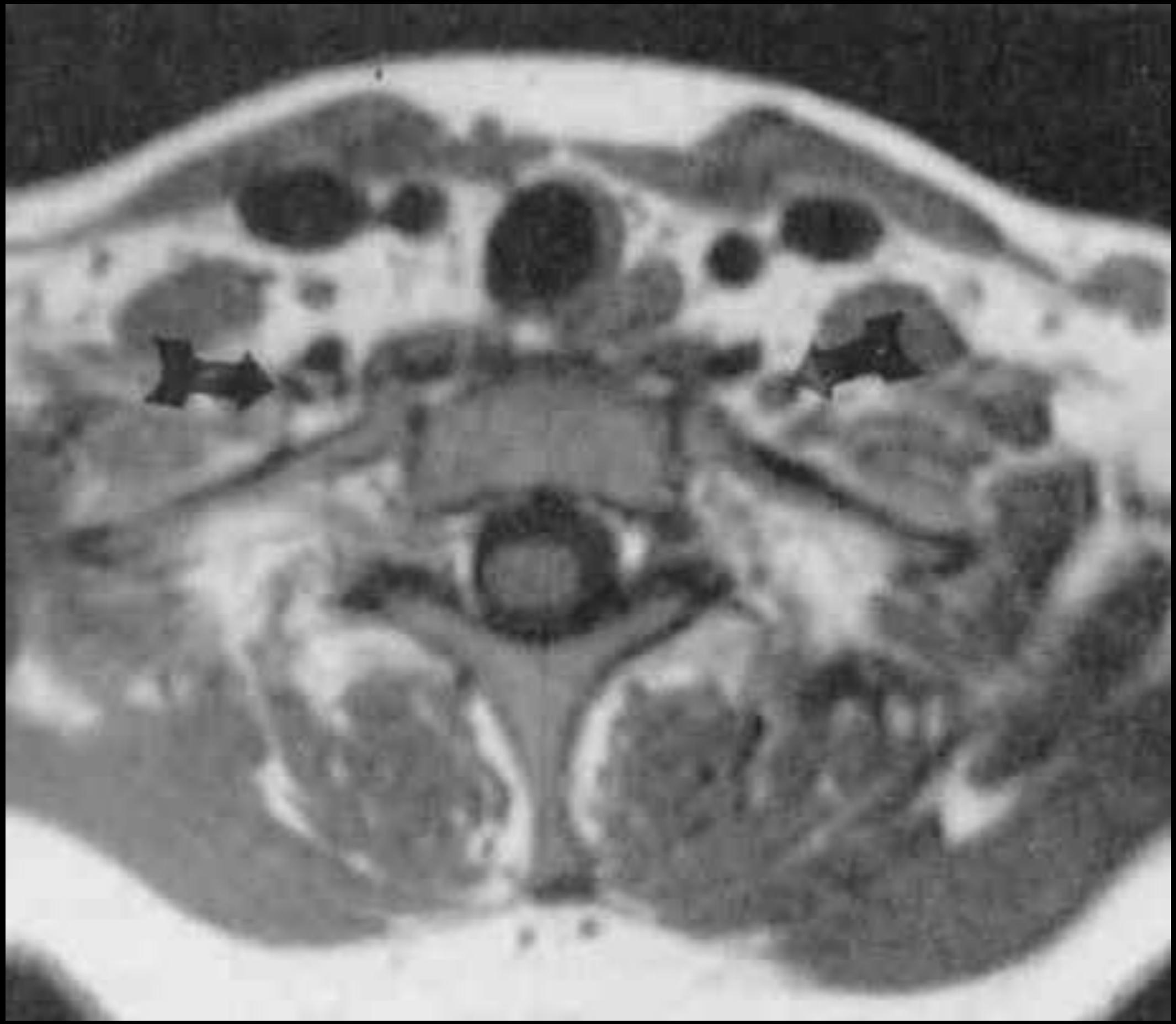

Cervical Sympathetic Block

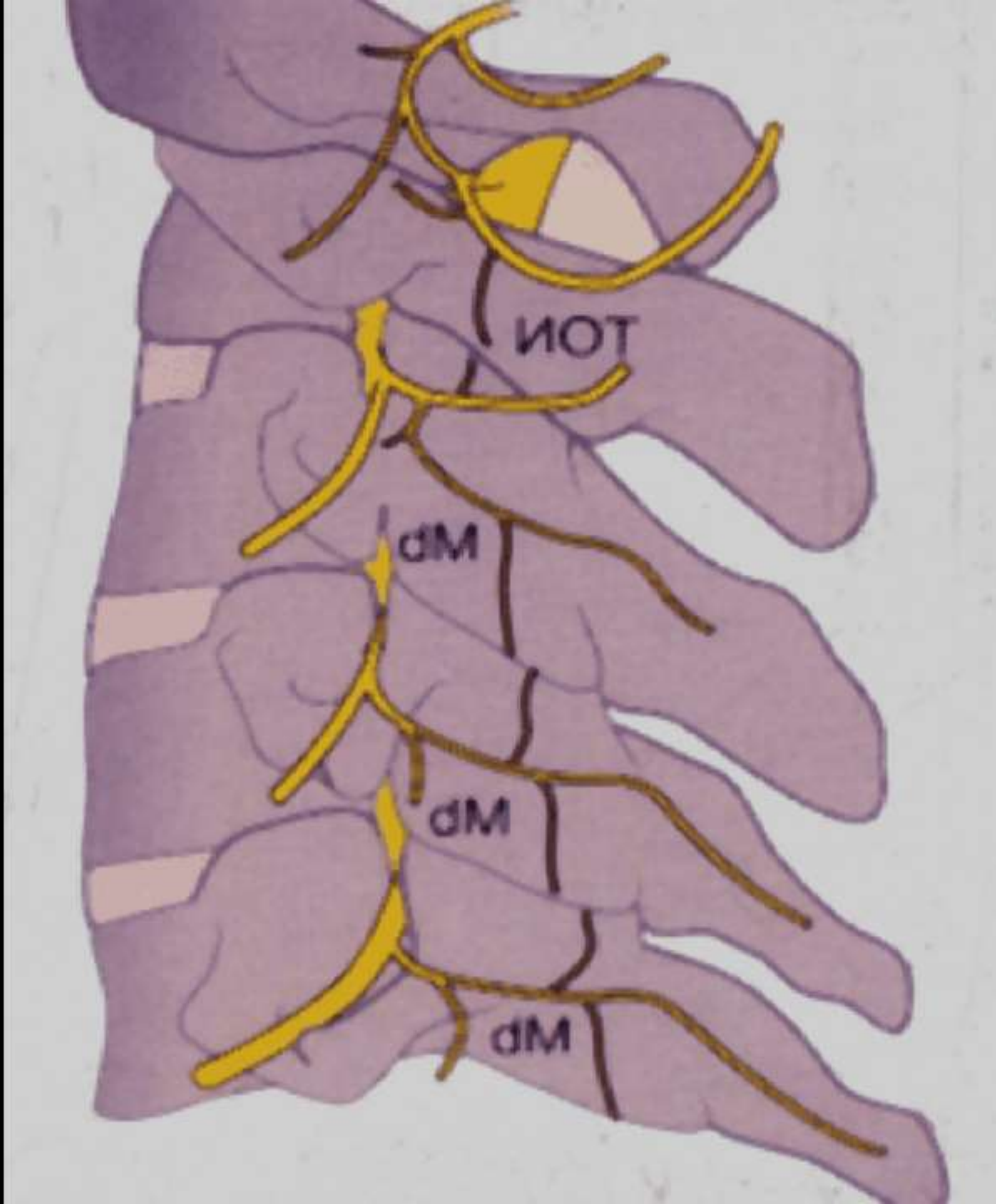

TON
Mb
Mb
Mb

Medial Branch Localization

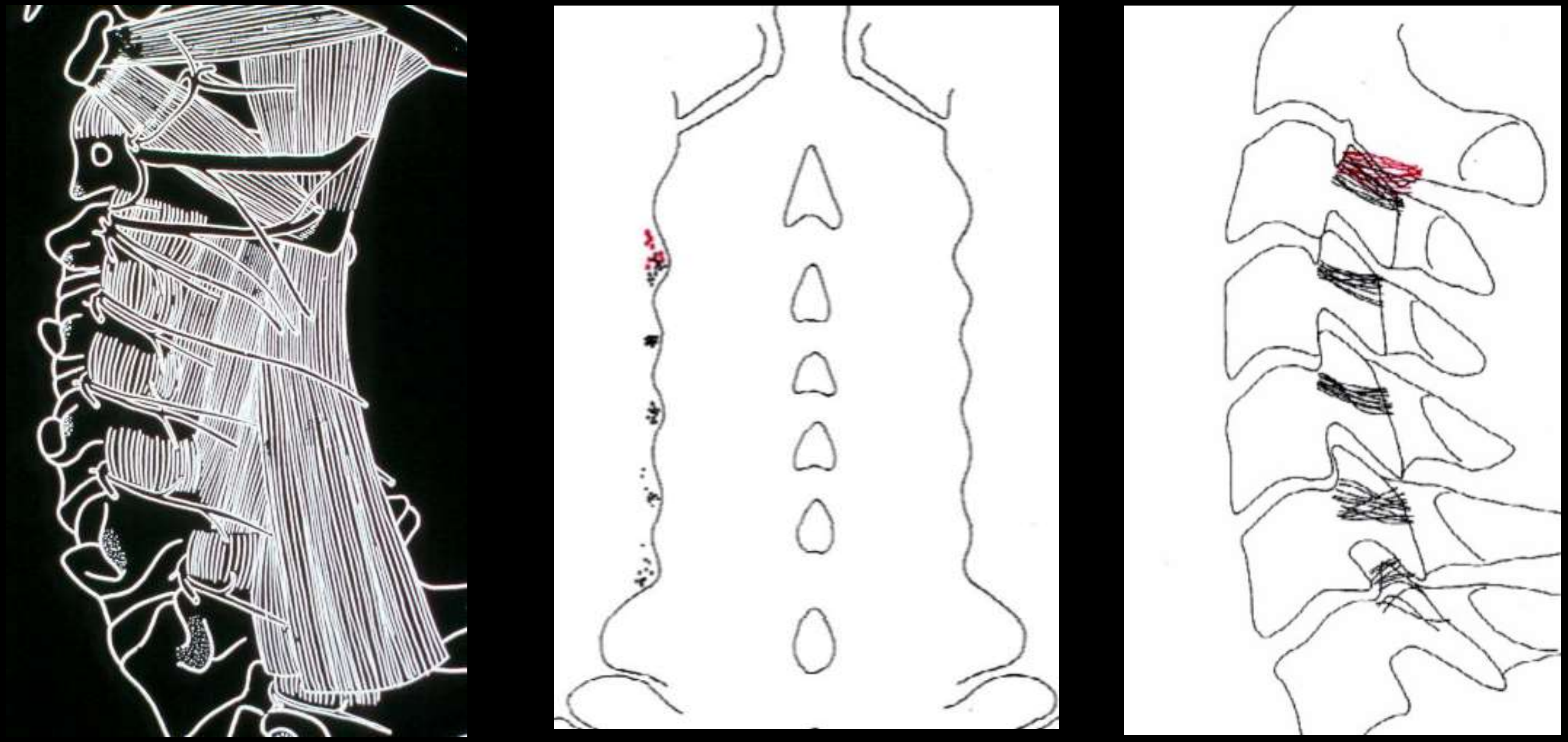

S.M. LORD Ph.D, 1996, University of Newcastle

Cervical Medial Branches

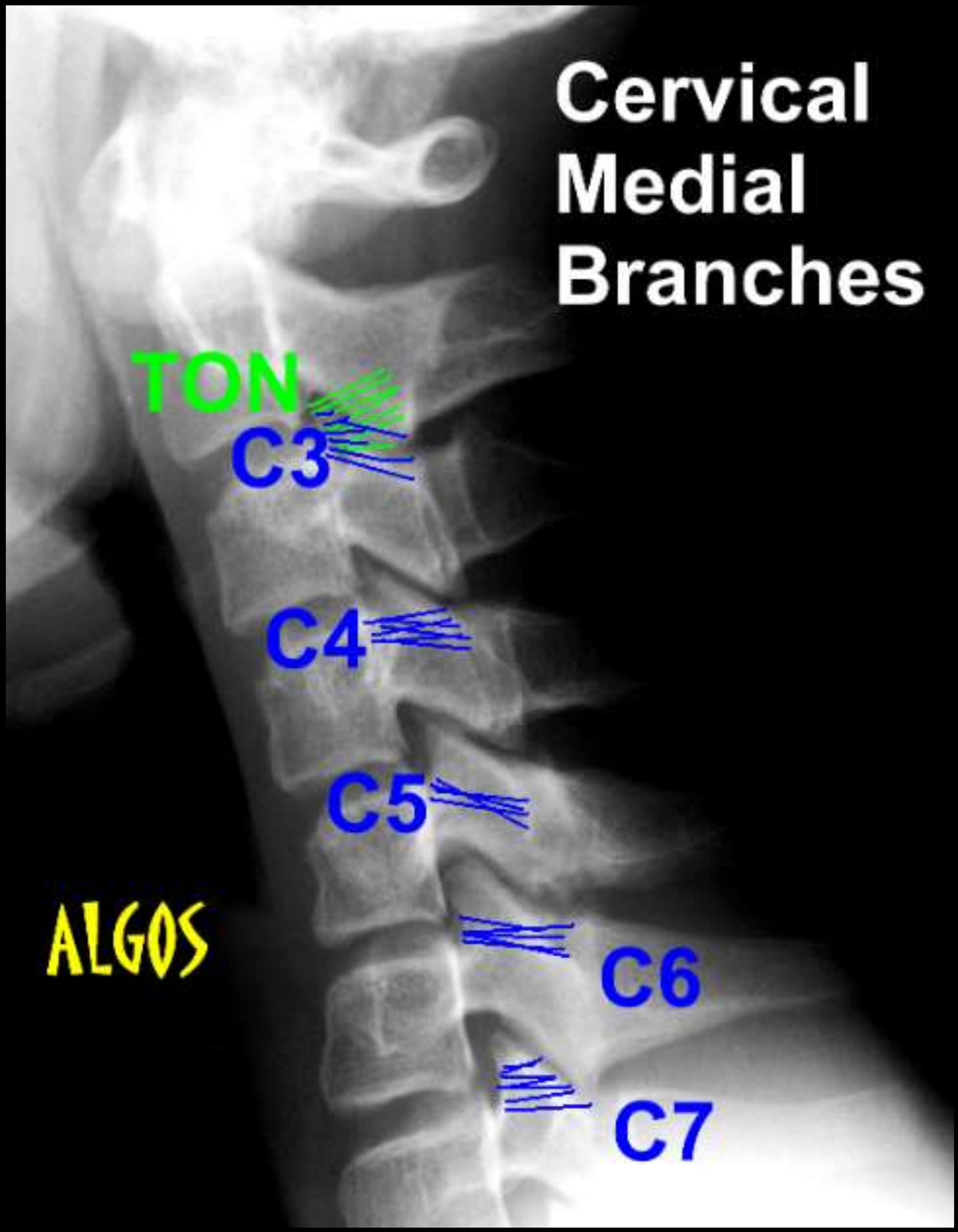

Medial Branch Localization

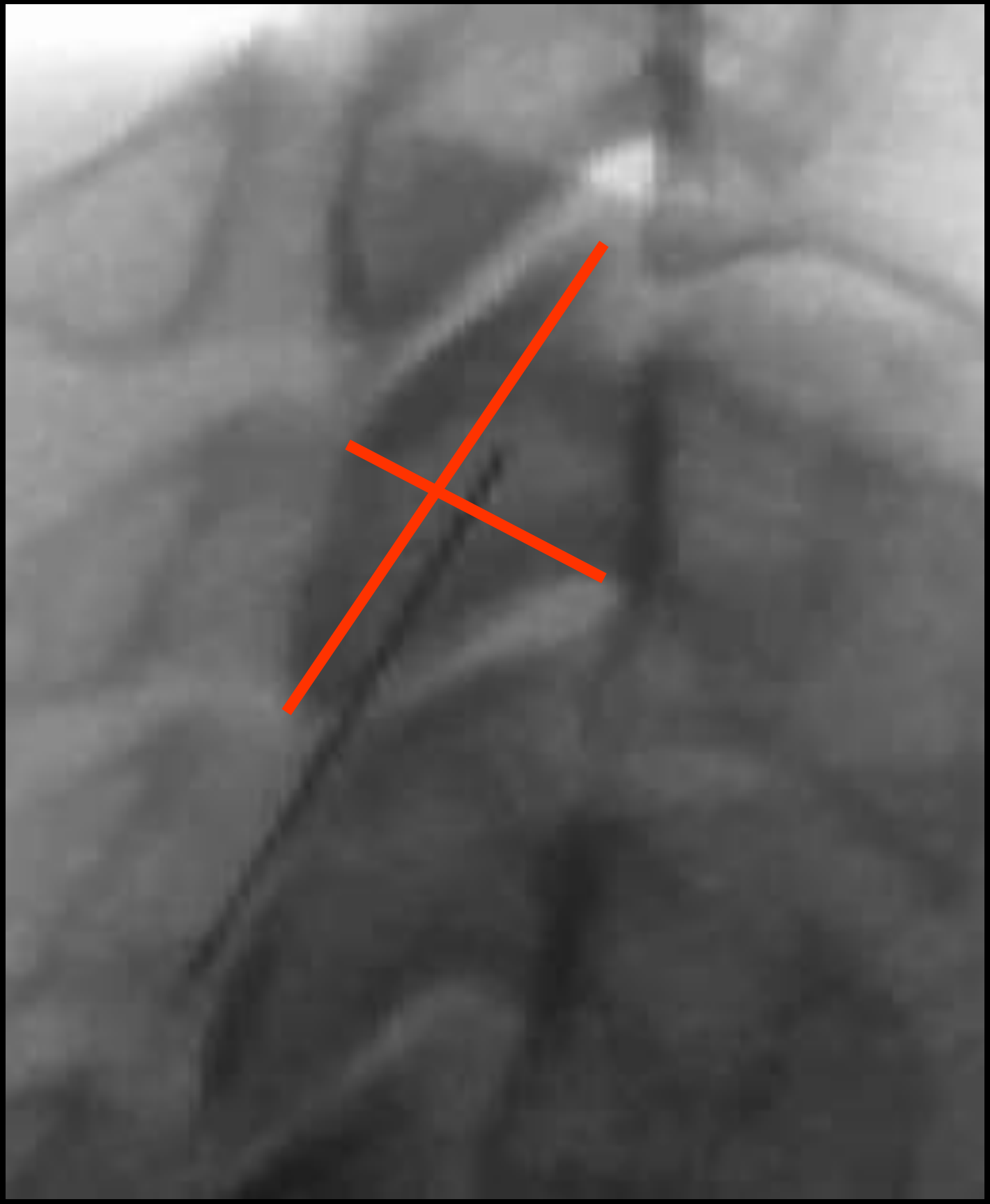

Centrode of articular pillar

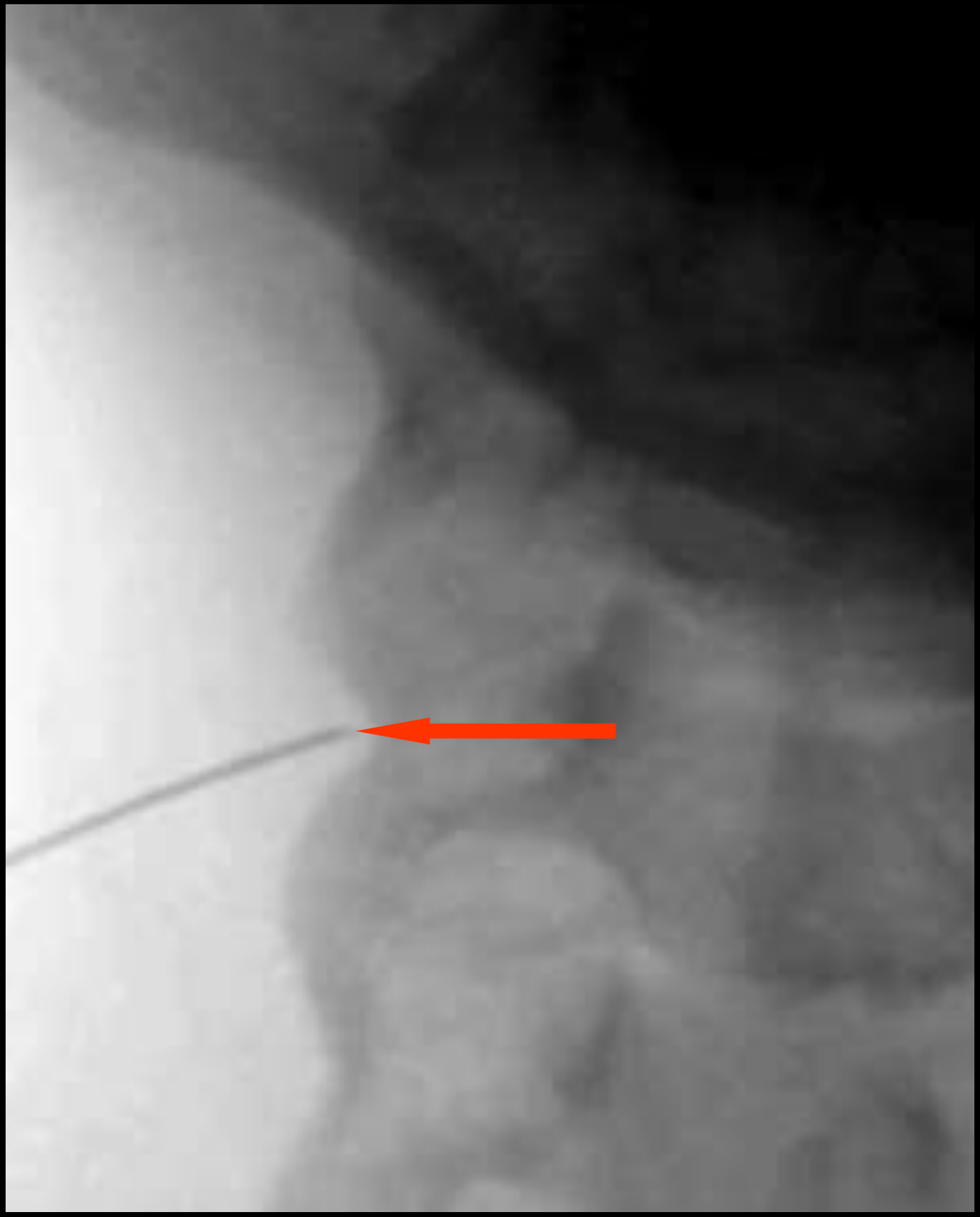

Waist of articular pillar

Recession

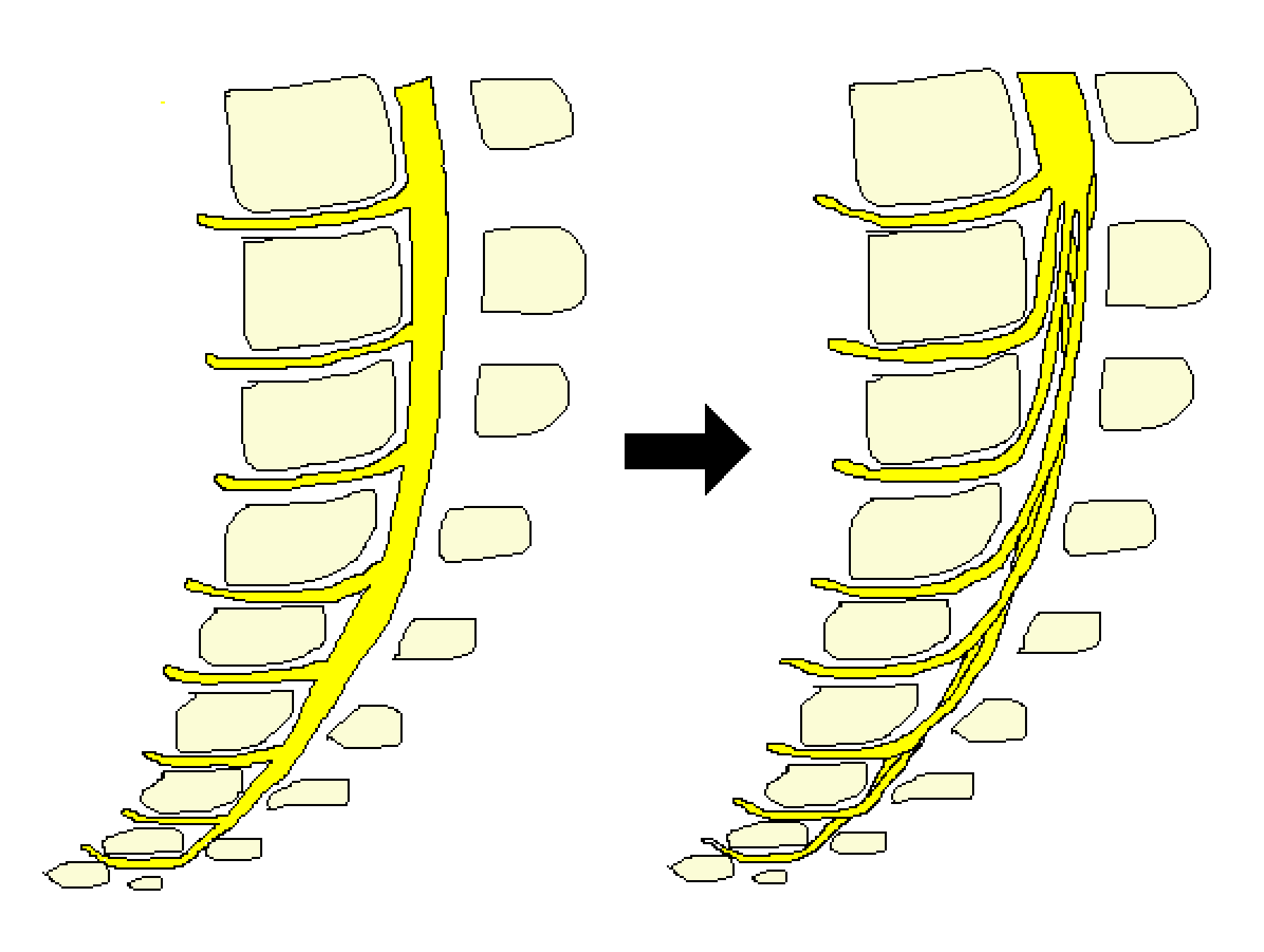

T2-WI FSE

Central Canal Anatomy: MR Spinal Cord

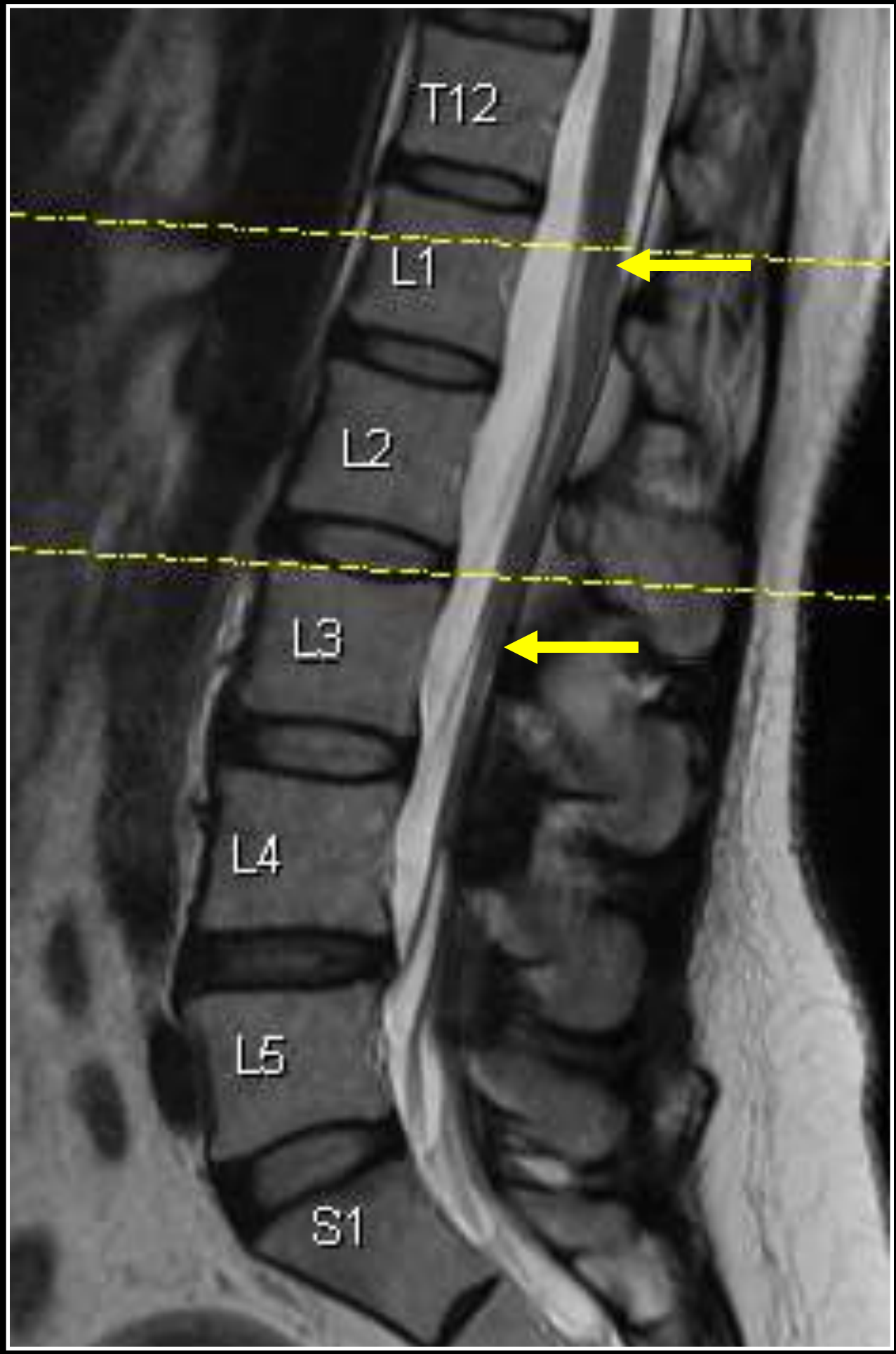

- The conus most commonly terminates at or just above L1-2
- Below this are the cauda equina nerve roots

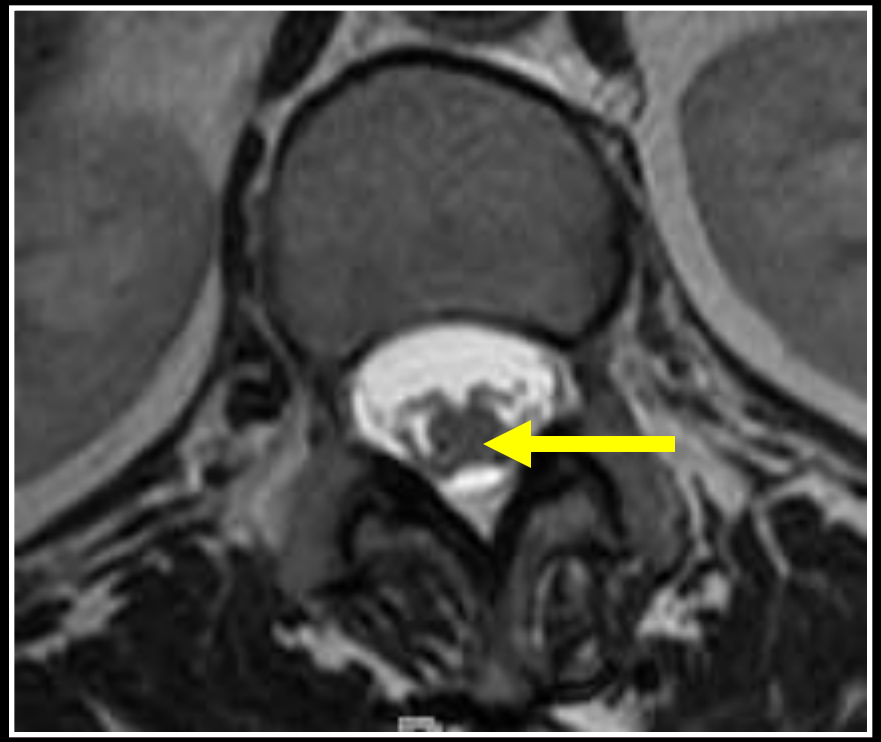

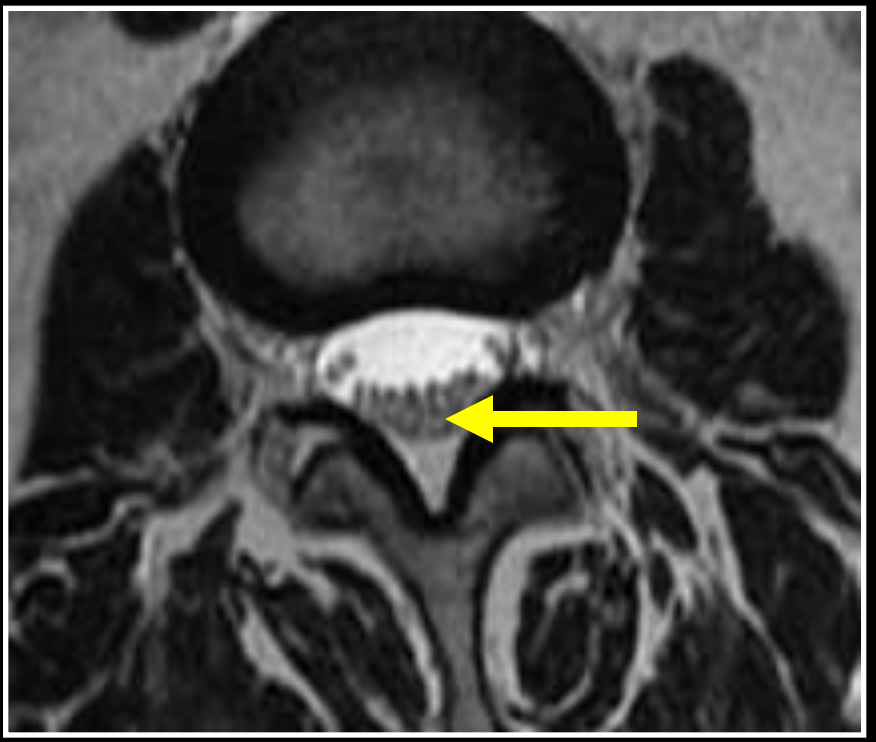

Courtesy of Anna Nidecker and Ari Blitz

PITFALLS: CONJOINED NERVE ROOT SLEEVE

T1-WI SE

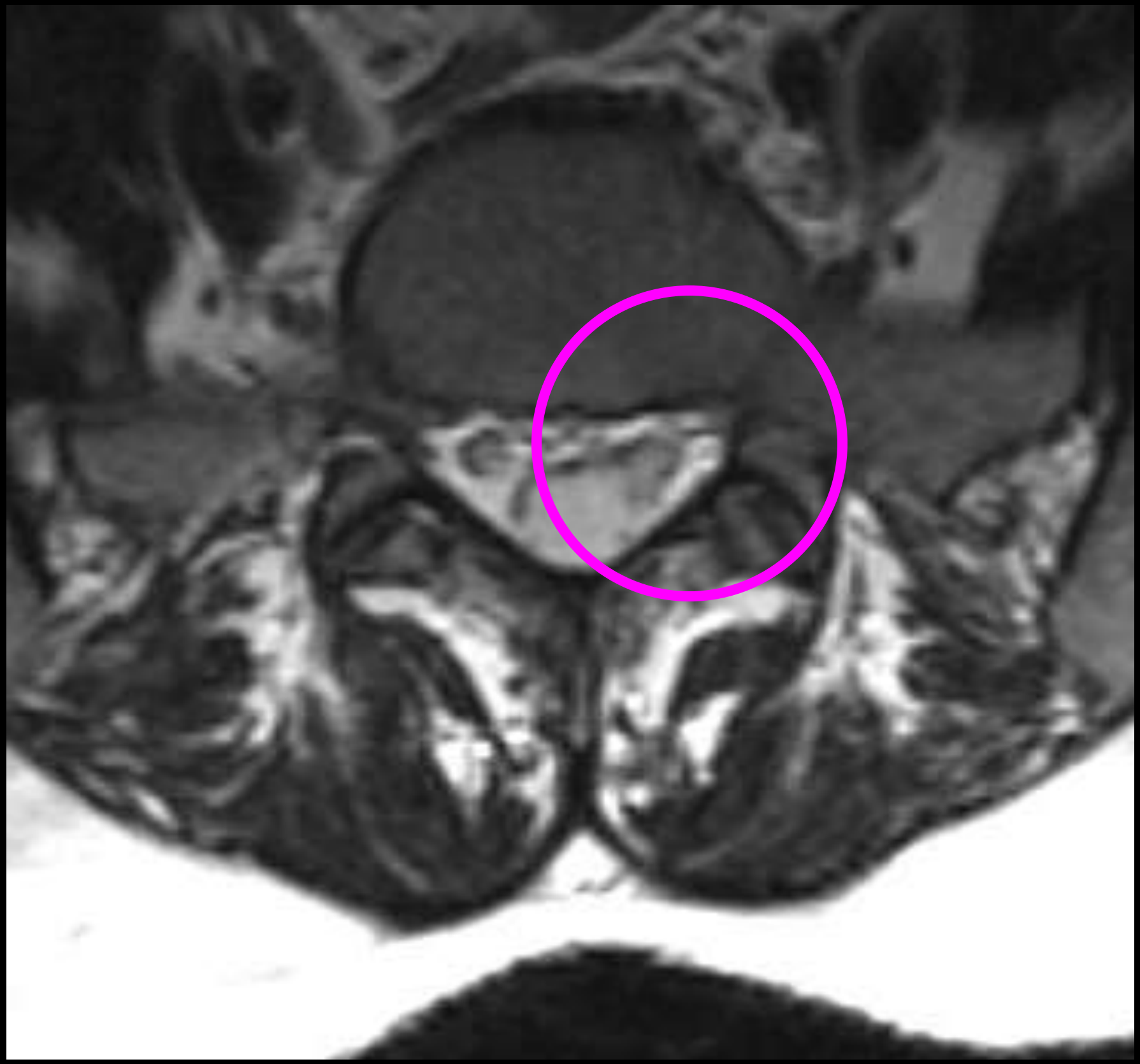

T2-WI FSE

Innervation of Ventral Aspect Of Spinal Column

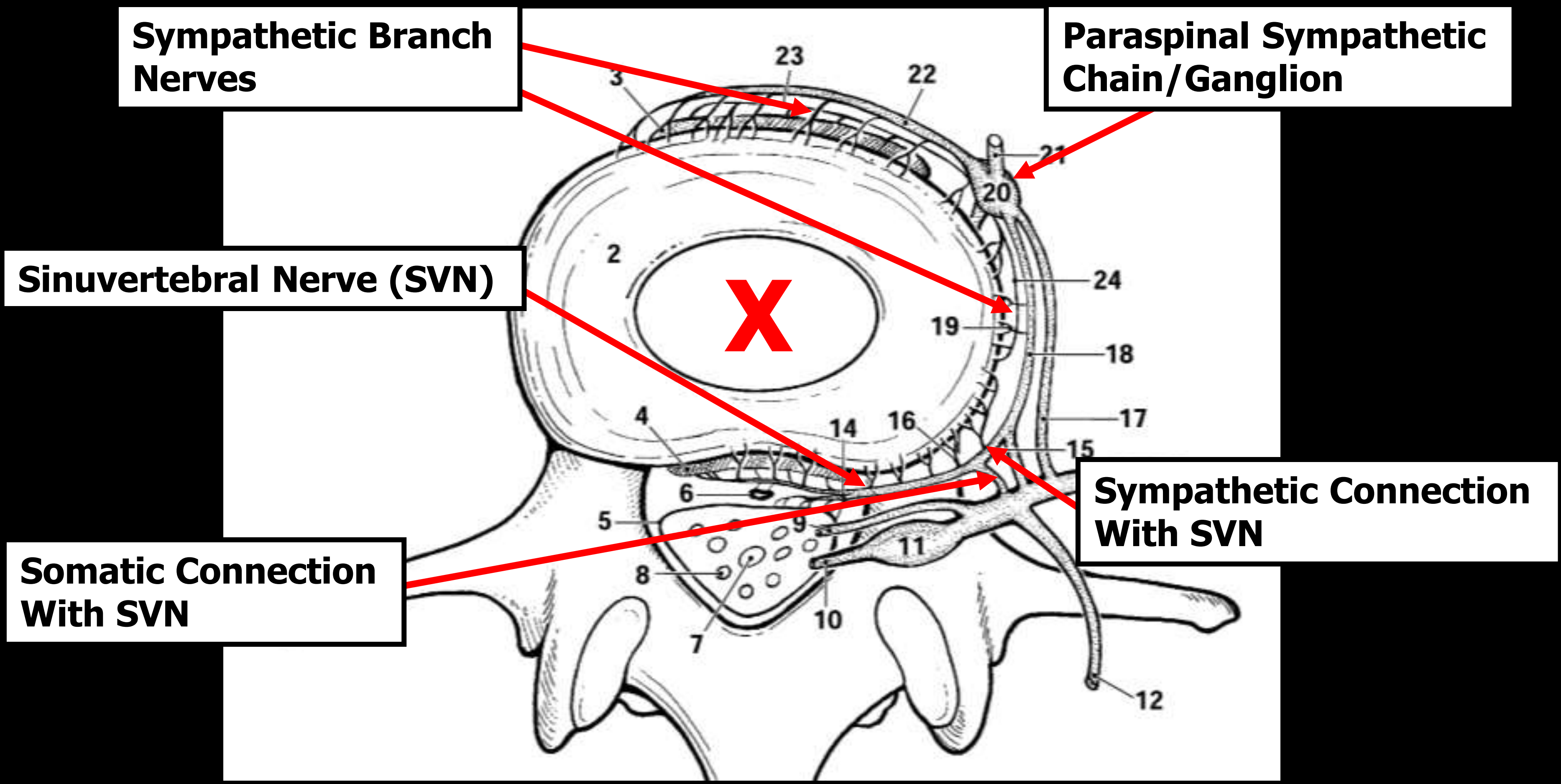

Courtesy of J. Randy Jinkins, MD

Somatic Innervation: Sinuvertebral Nerve of Luschka [Recurrent Meningeal Nerve]

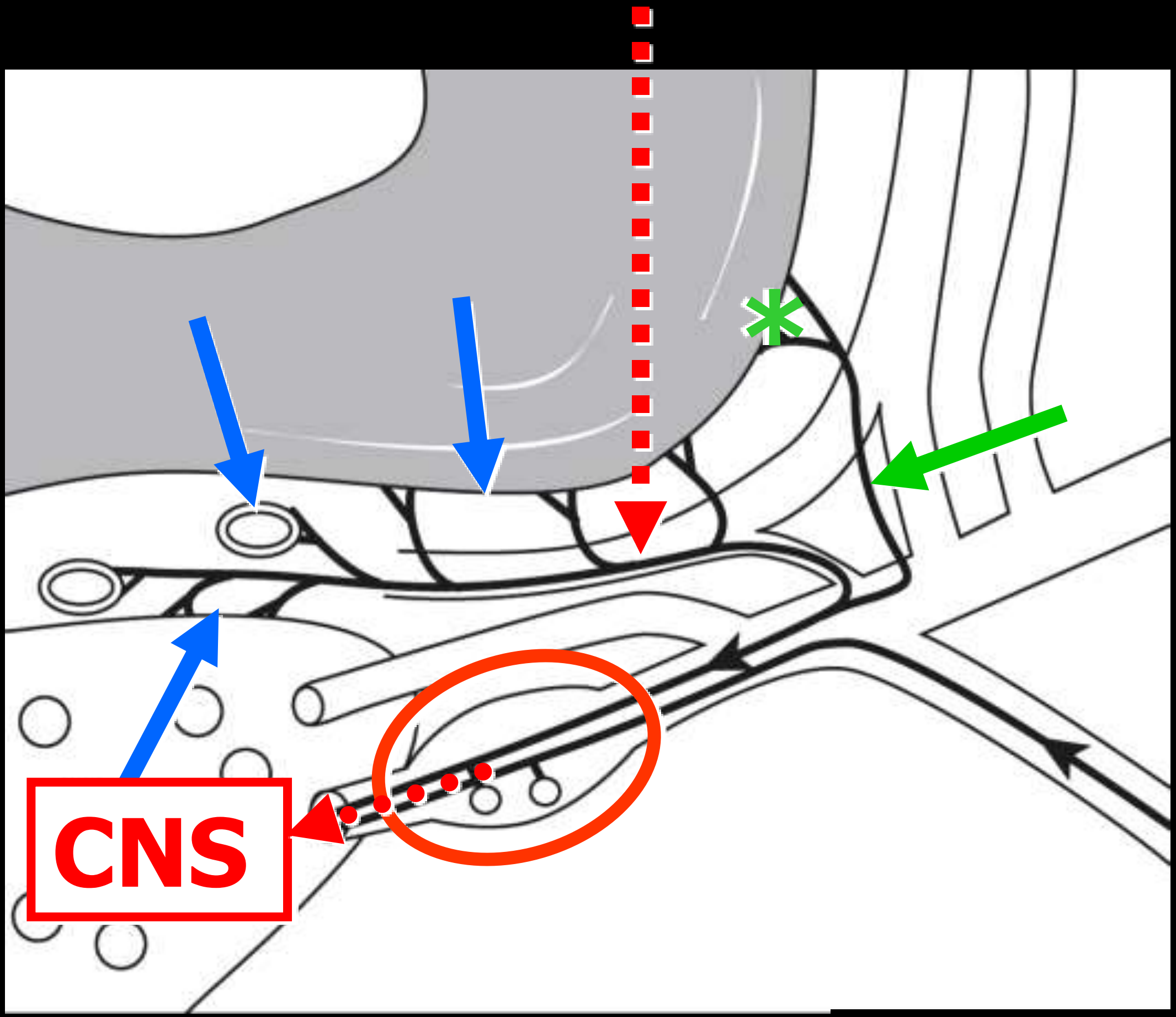

Courtesy of J. Randy Jinkins, MD

Innervation of Dorsal Aspect Of Spinal Column: I

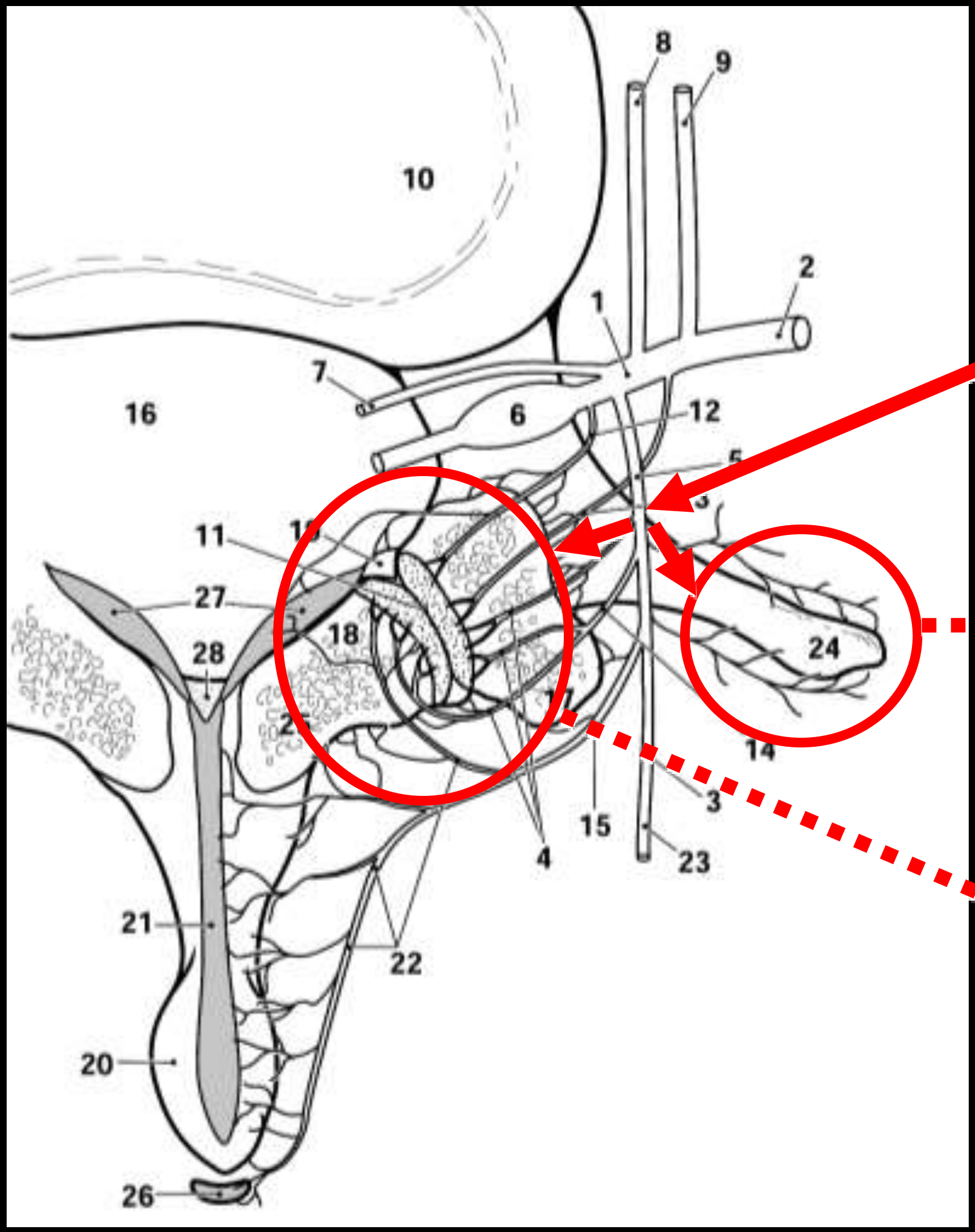

Dorsal Ramus: Common Trunk

Transverse Process

Posterior Facet Joint, Lamina, Pars Int.

Courtesy of J. Randy Jinkins, MD

Innervation of Dorsal Aspect Of Spinal Column: II

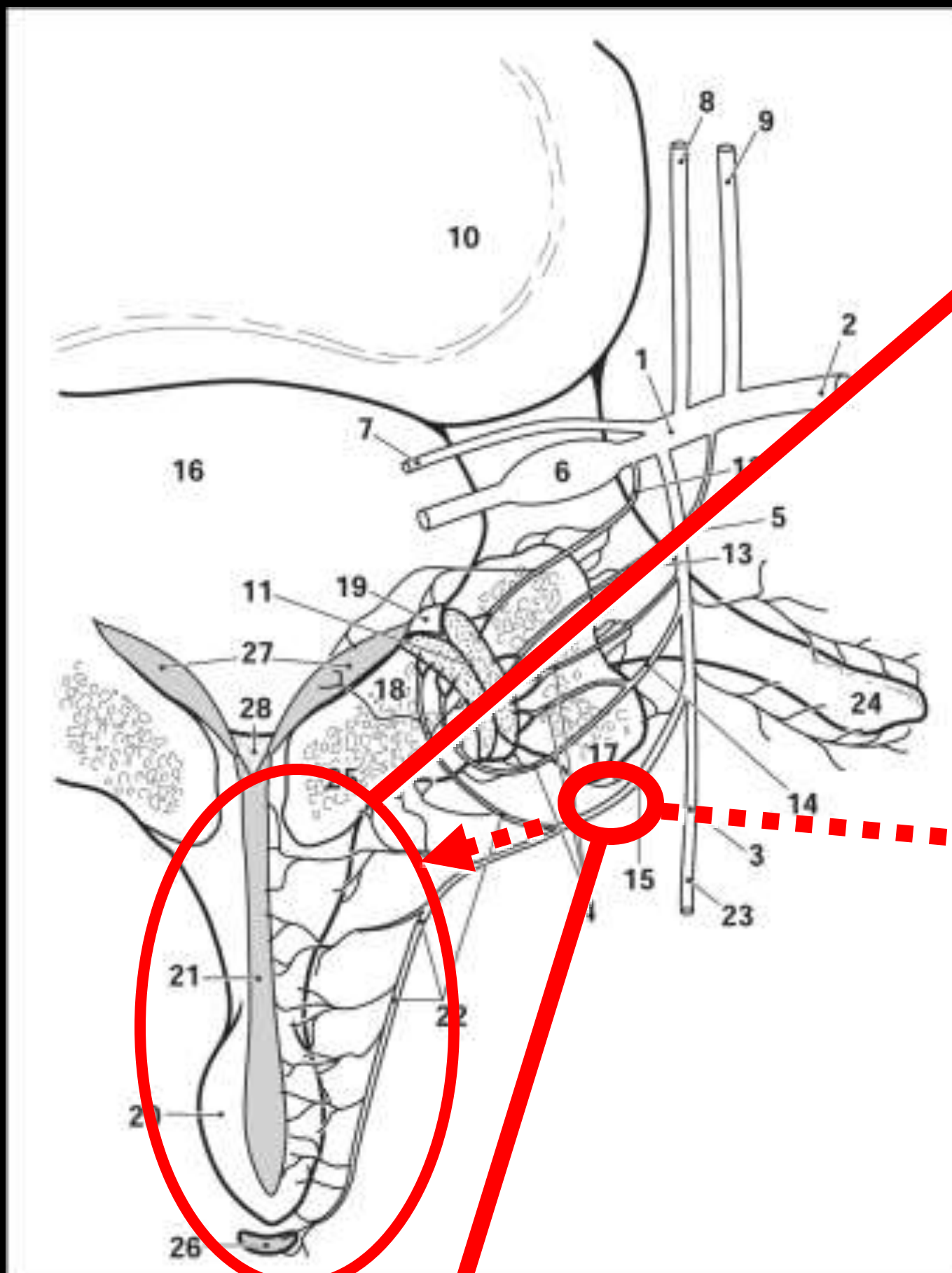

Spinous Process, Interspinous Ligament, Supraspinous Ligament

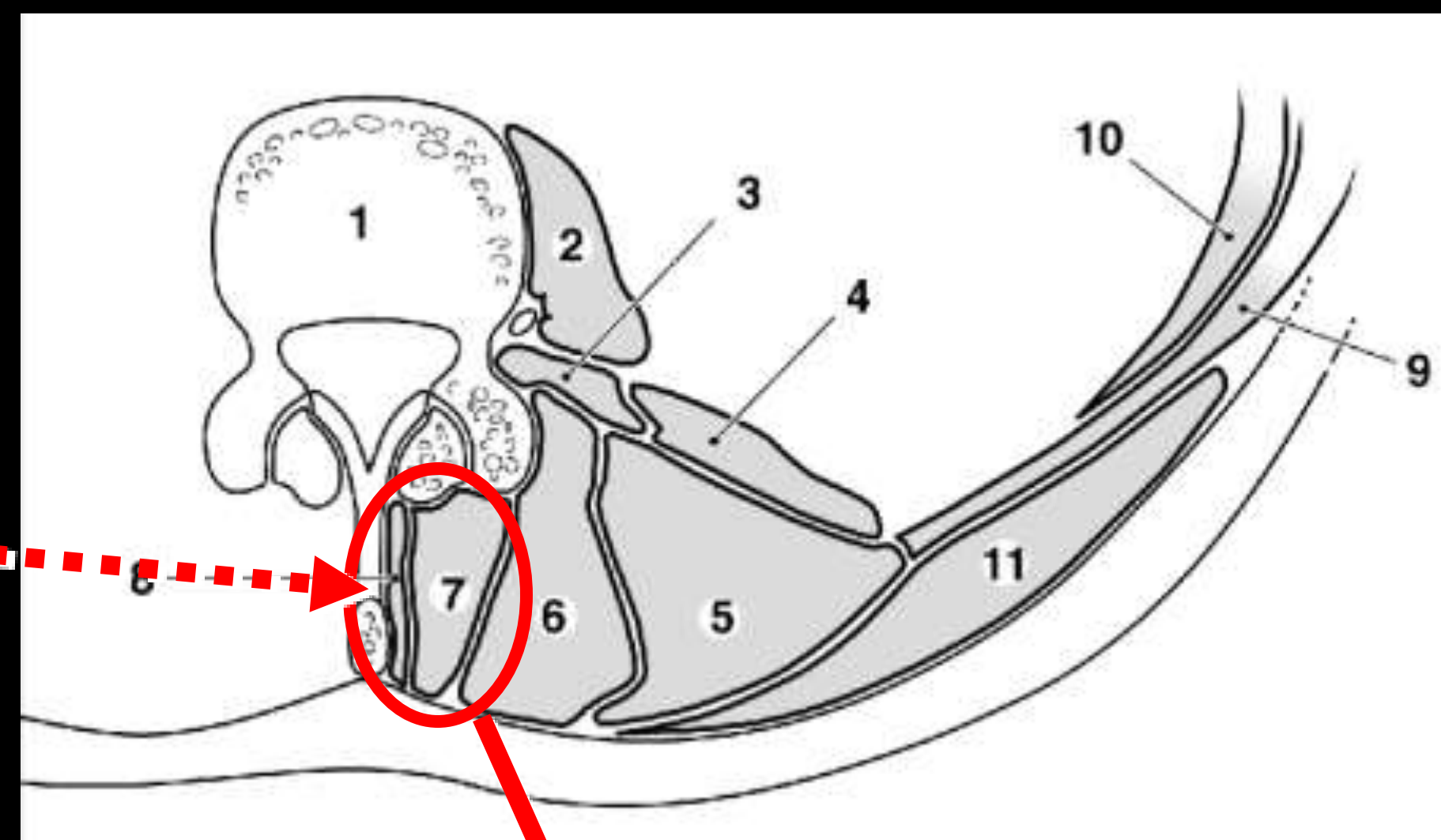

Intrinsic Spinal Muscles: Interspinalis + Multifidus Ms.

Medial Branch: Dorsal Ramus

Courtesy of J. Randy Jinkins, MD

Contents

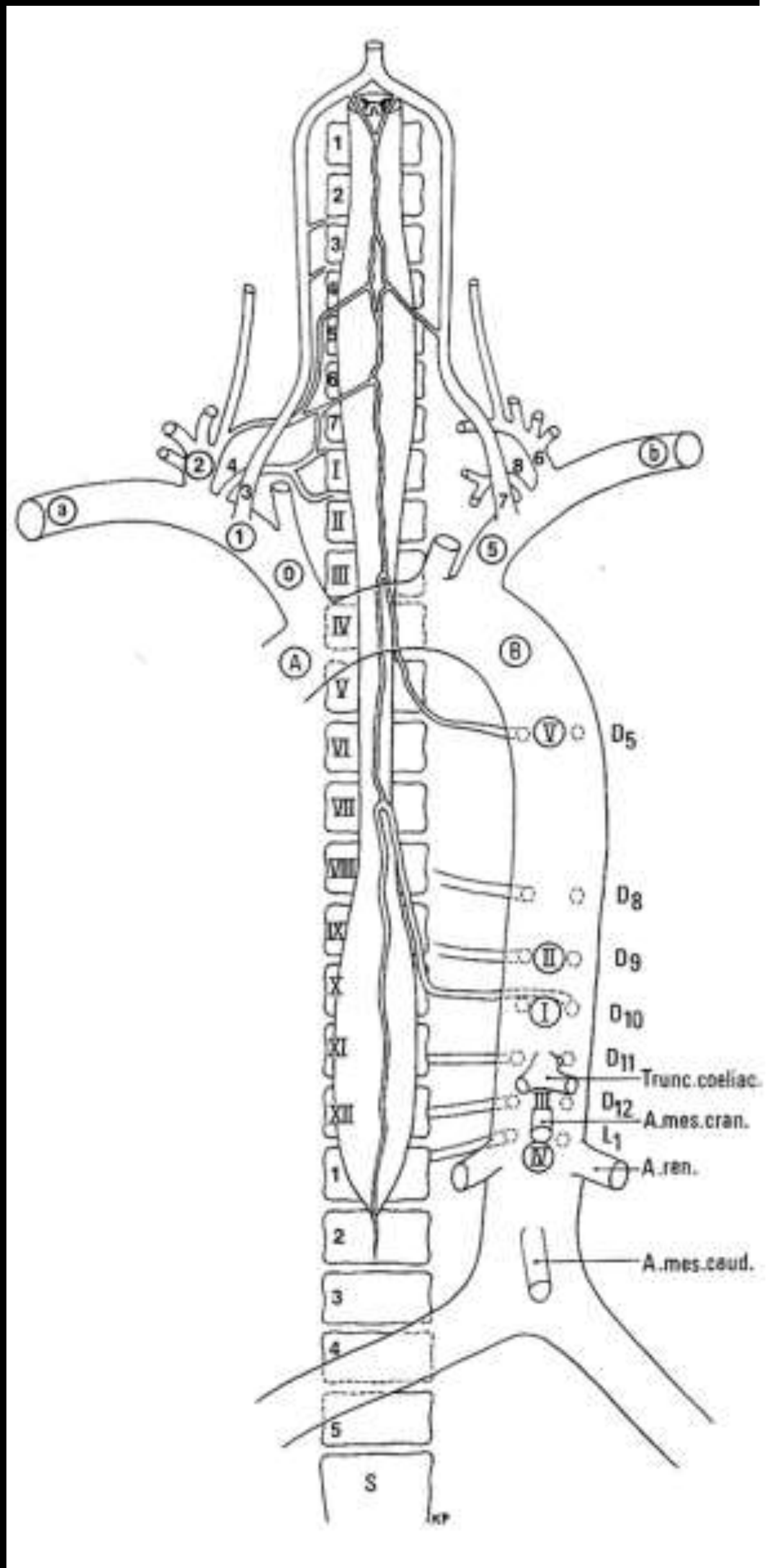

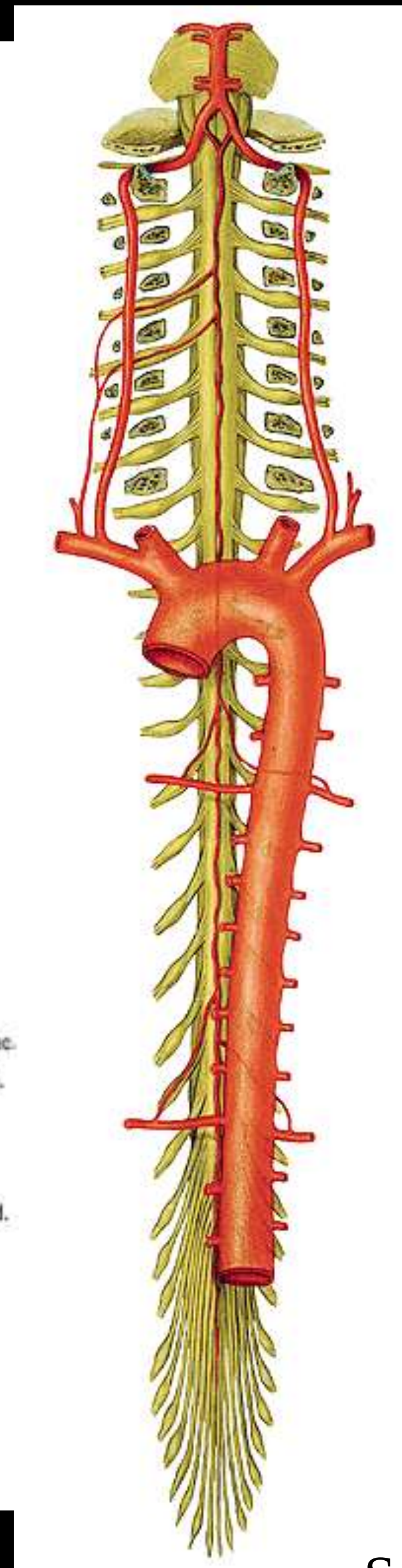

Sc

A. cervicalis profunda

A. cervicalis ascendens

A. vertebralis

A. subclavia

Aa. intercostales posteriores

A. radicularis (anterior) magna

Aa. lumbales

Aa. sacrales laterales



Tillmann, 2004

A. cervicalis profunda

A. cervicalis ascendens

A. vertebralis

A. subclavia

Aa. intercostales posteriores

A. radicularis (anterior) magna

Aa. lumbales

Aa. sacrales laterales

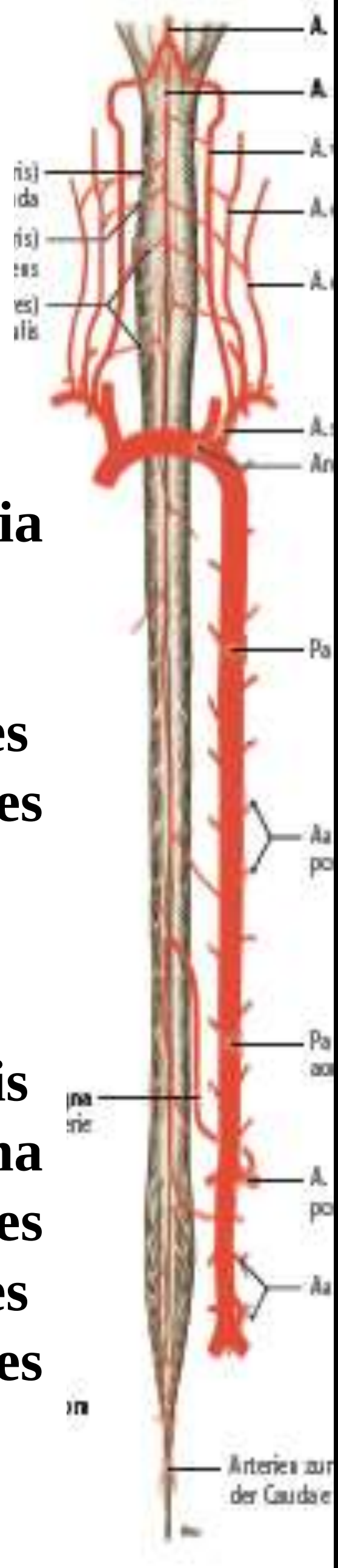

Tillmann, 2004

The Vert

- The paired vertebral arteries arise from the **subclavian** artery
- They ascend through the transverse processes of the upper 6 cervical vertebrae
- Pass behind the lateral mass of C1 and enter the dura *behind* the occipital condyle
- Ascend through the foramen magnum and join to form the **basilar artery**

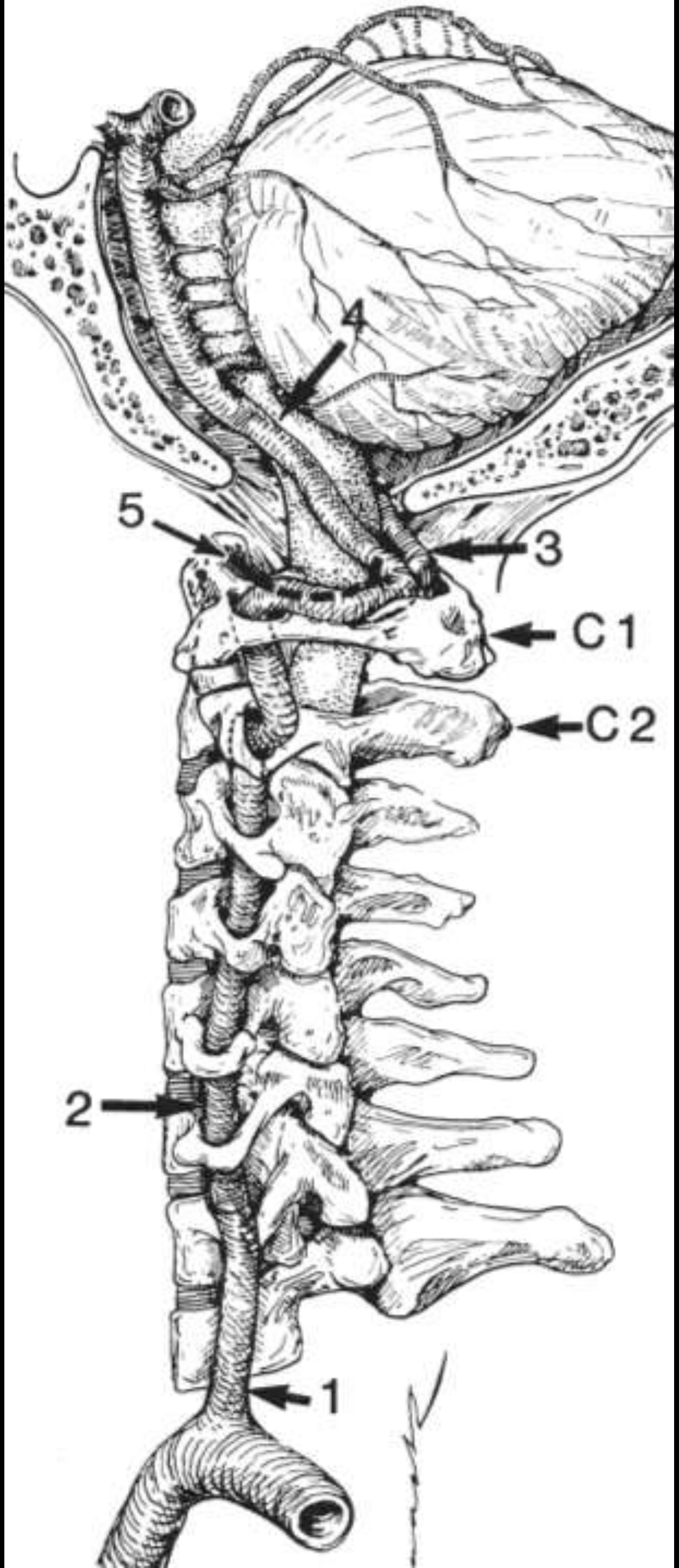

Vertebral Artery:

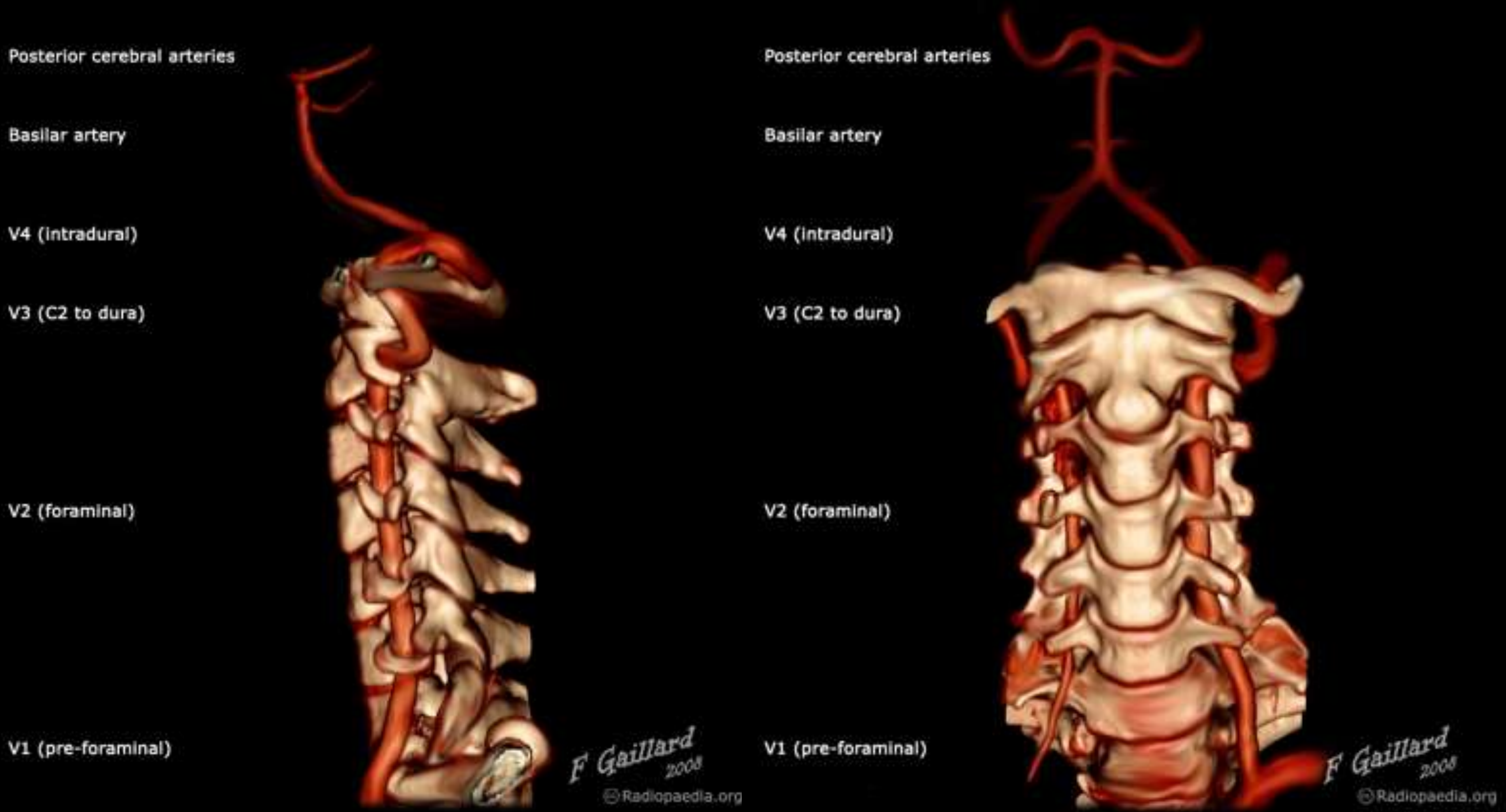

Vertebral artery: foramen transversarium , anterior neural foramen
Lateral to C1-C2 joint, pierces dura above C1 arch

Cervical Vasculature

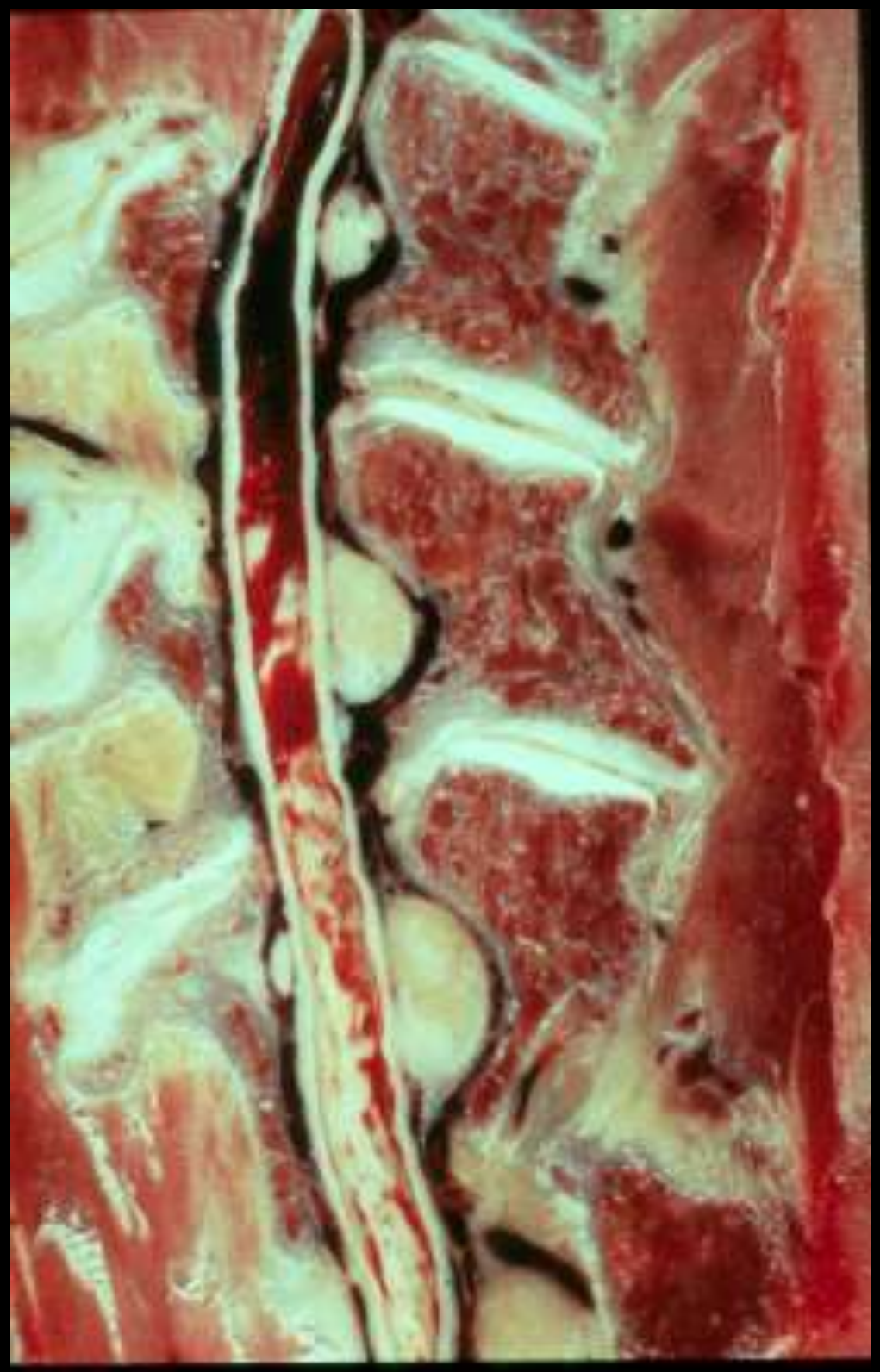

2D time-of-flight sequence

Vascular Supply to the Spinal Cord

Section courtesy of Adam Flanders, MD

Arterial Supply

- Arterial supply to the spine through the radicular arteries
- Not at all levels
- Largest arises in the thoracic region- the artery of Adamkiewicz

(Nolte Fig 10-29)

Arterial Supply

- Anterior spinal artery and two posterior spinal arteries originate from vertebral arteries and supply the superior cord
- Spinal radicular arteries arise from vertebral, deep cervical, posterior intercostal, lumbar, and lateral sacral arteries
- Radicular arteries enter through neuroforamina and divide into anterior and posterior branches to supply vertebrae, meninges, and cord

Arterial supply

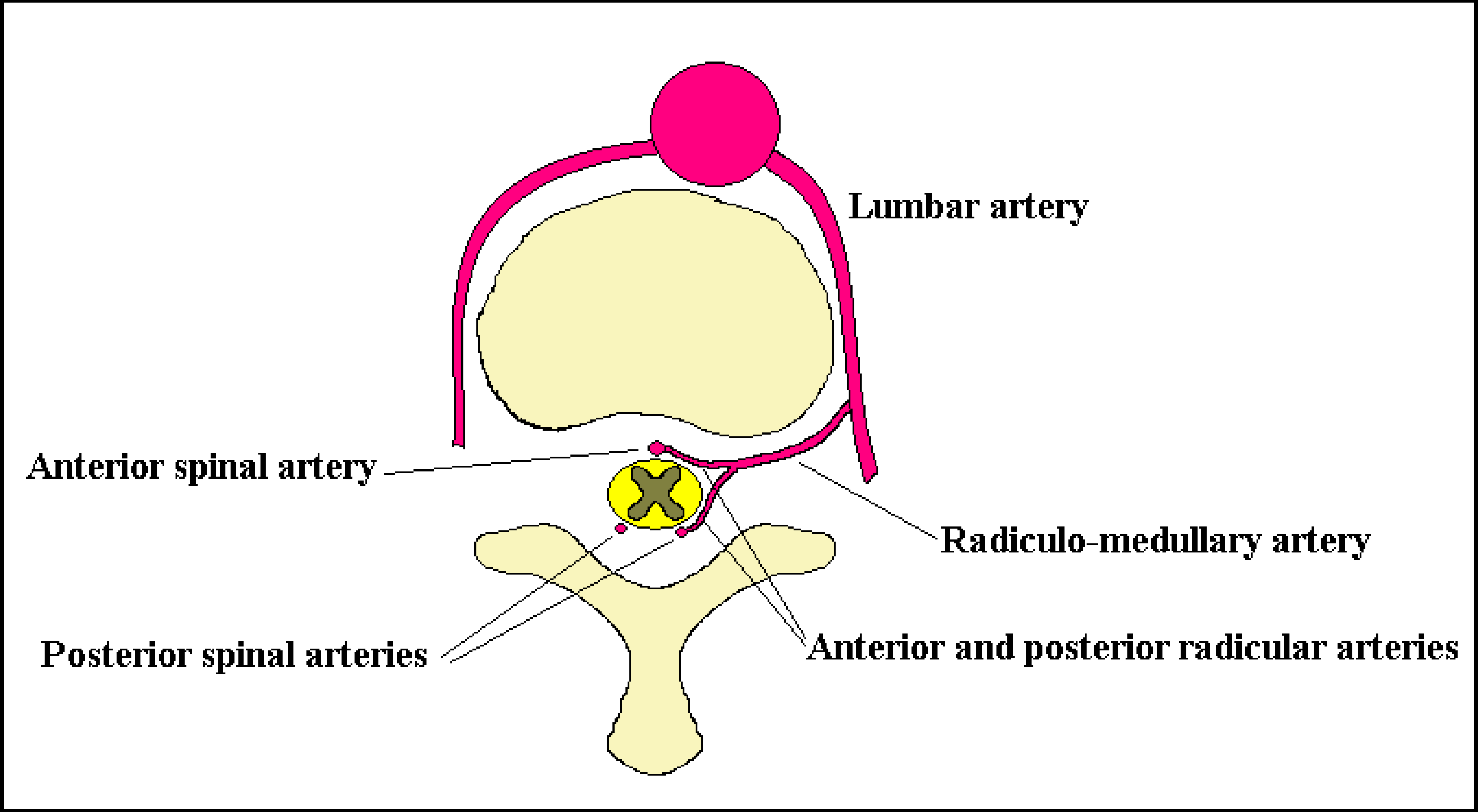

Sagittal contrast-enhanced MR angiographic images (T1-weighted gradient-echo sequence [5.9/1.9; flip angle, 30°]) obtained during two dynamic phases.

Nijenhuis R J et al. Radiology 2004;233:541-547

Radiology

Arterial Supply

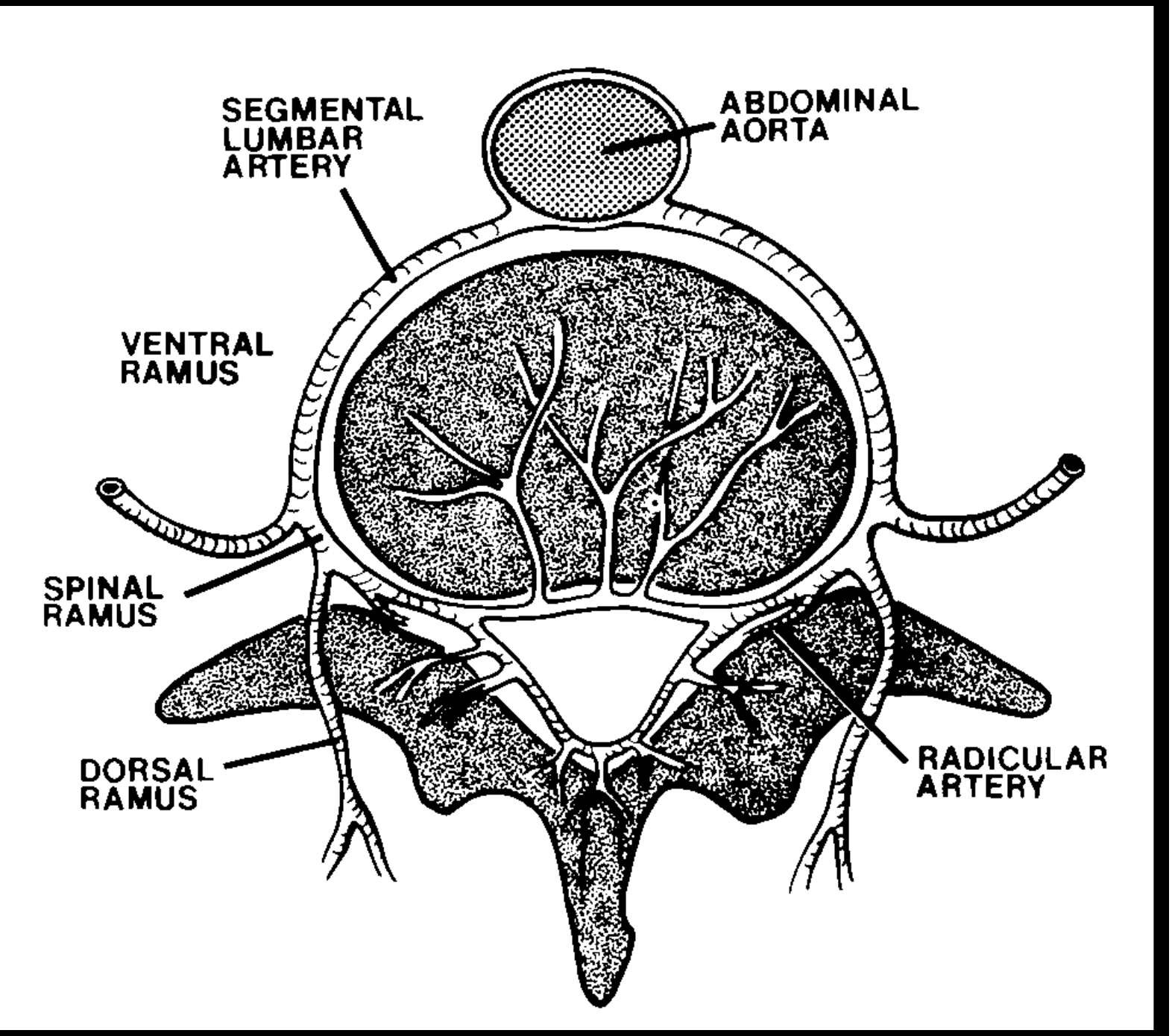

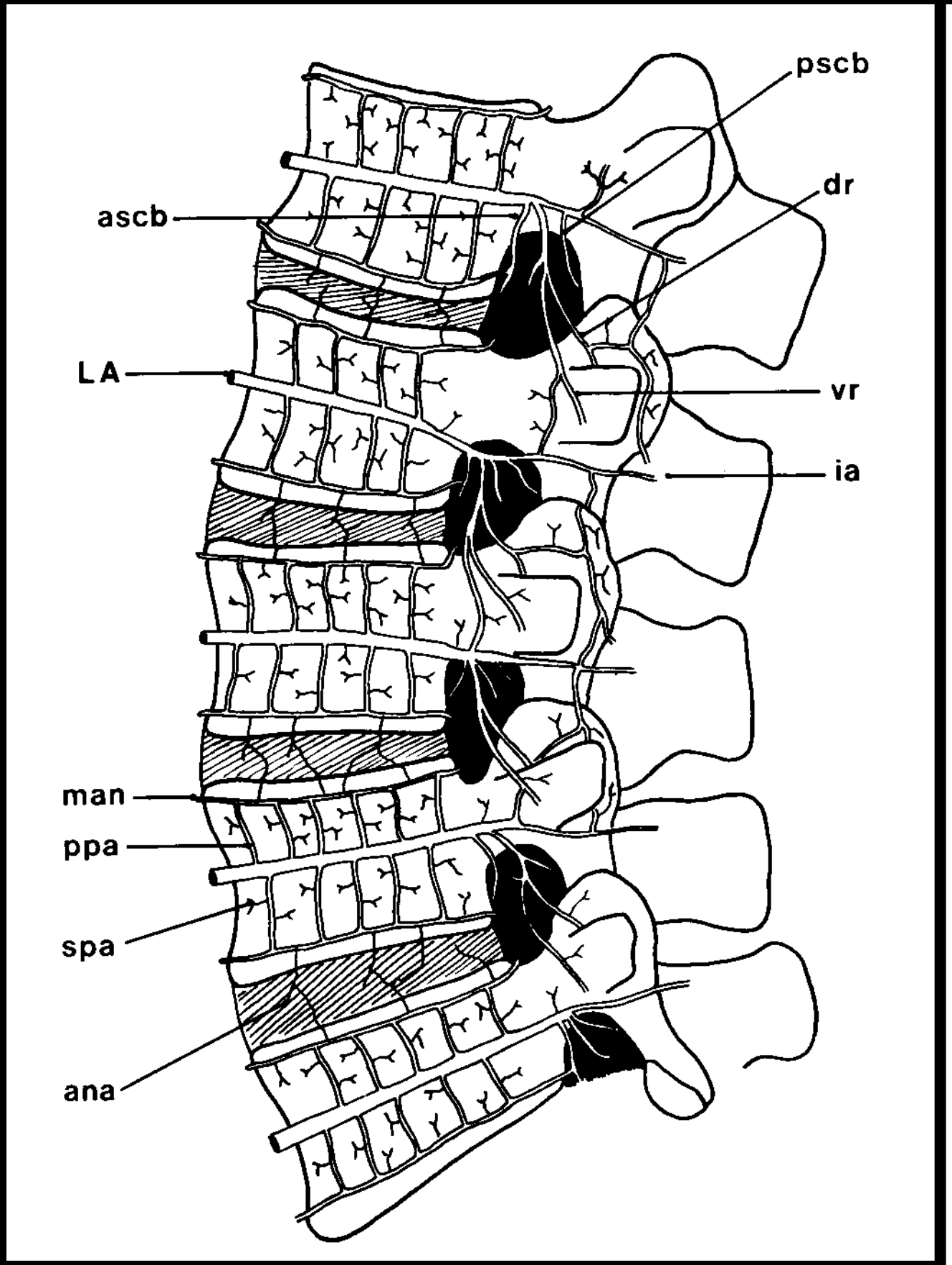

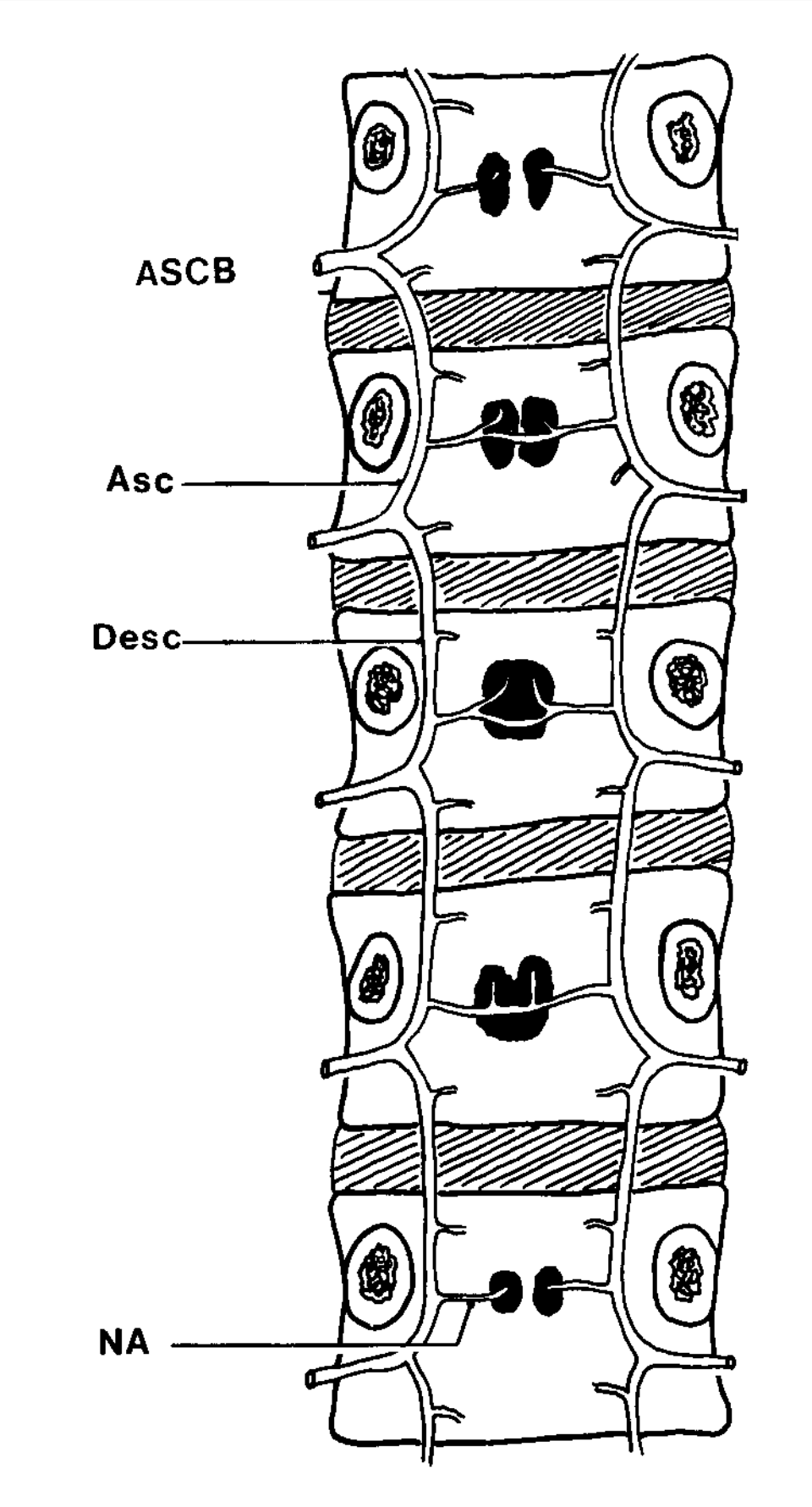

Spinal angiography

radicular artery

Spinal angiography

radicular artery

radiculomeningeal or radiculomedullary arteries

Vascular Anatomy of the Spinal Cord

Anterior Spinal Artery (ASA)

Posterior Spinal Arteries (PSA) ➔ paired

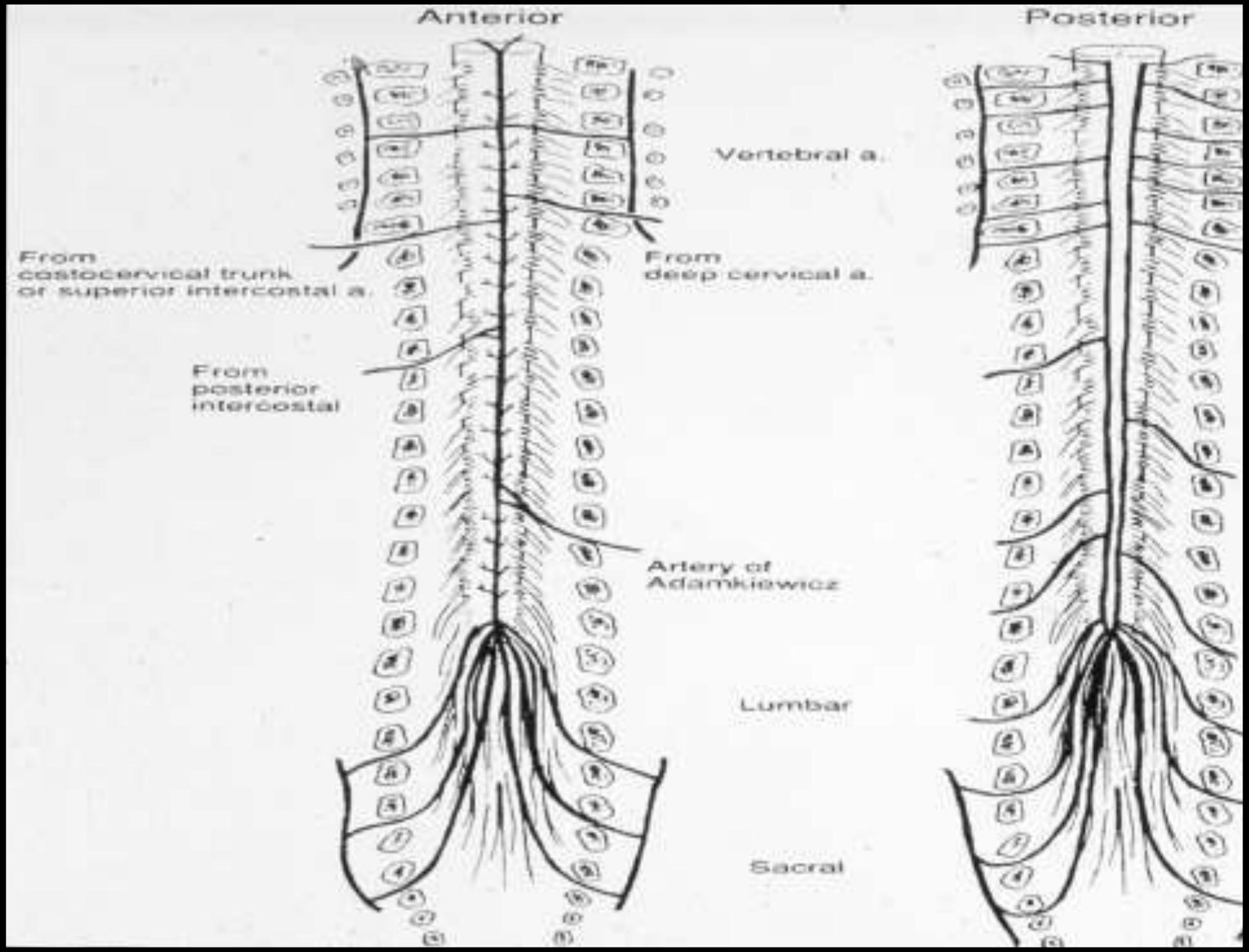

nomenclature

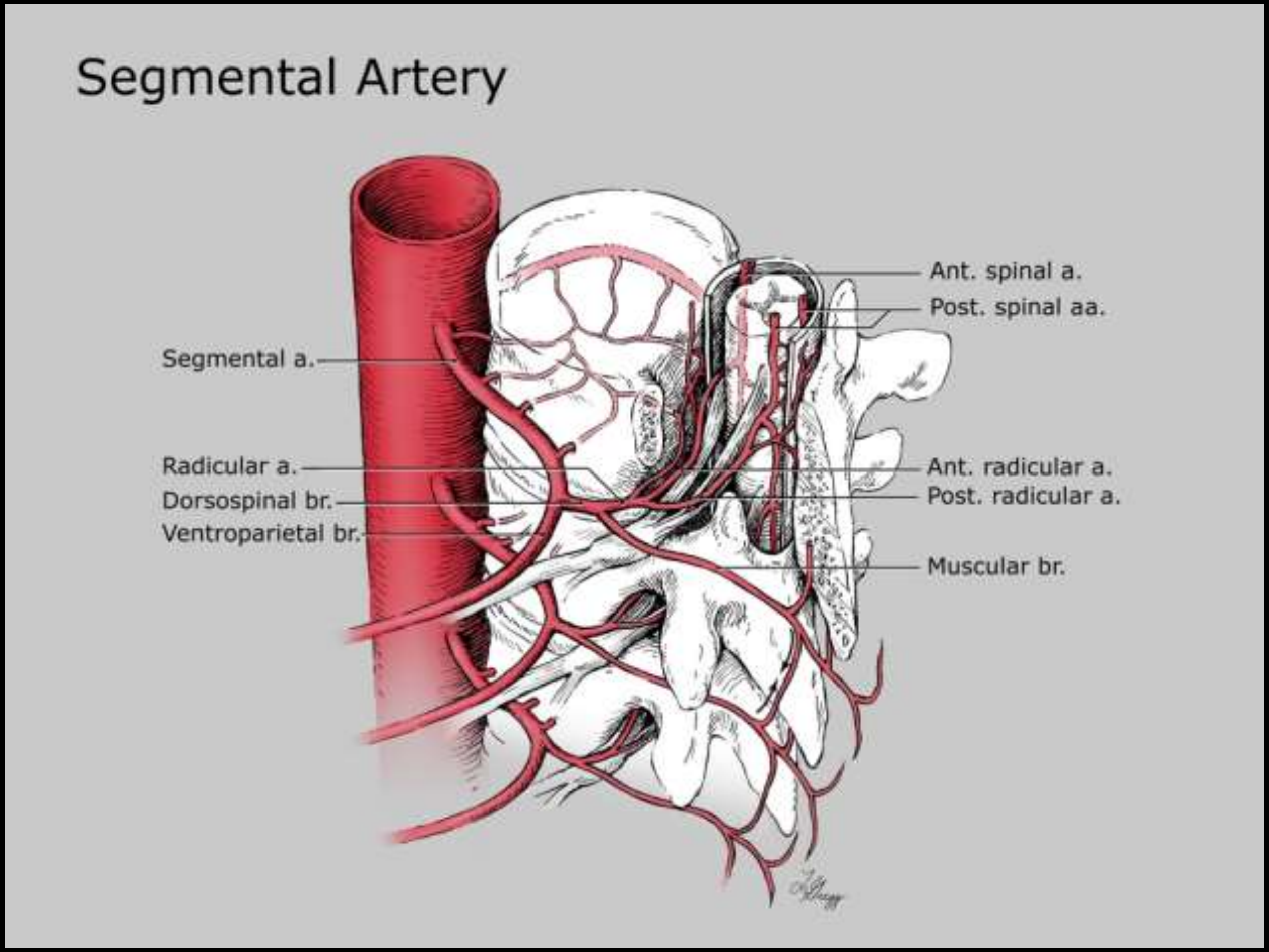

Courtesy of Philippe Gailloud, MD

Anterior Spinal Artery

- Three major regions of supply to the ASA
  - Cervicothoracic
  - Mid-thoracic
  - Thoraco-lumbar
- Borderzone (watershed) areas occur at the margins of each region.
- Adequate collateral flow is not always available across borderzone areas.
- Spinal cord is vulnerable to infarction in the event of systemic hypotension or compromise of a major radiculomedullary feeding vessel.

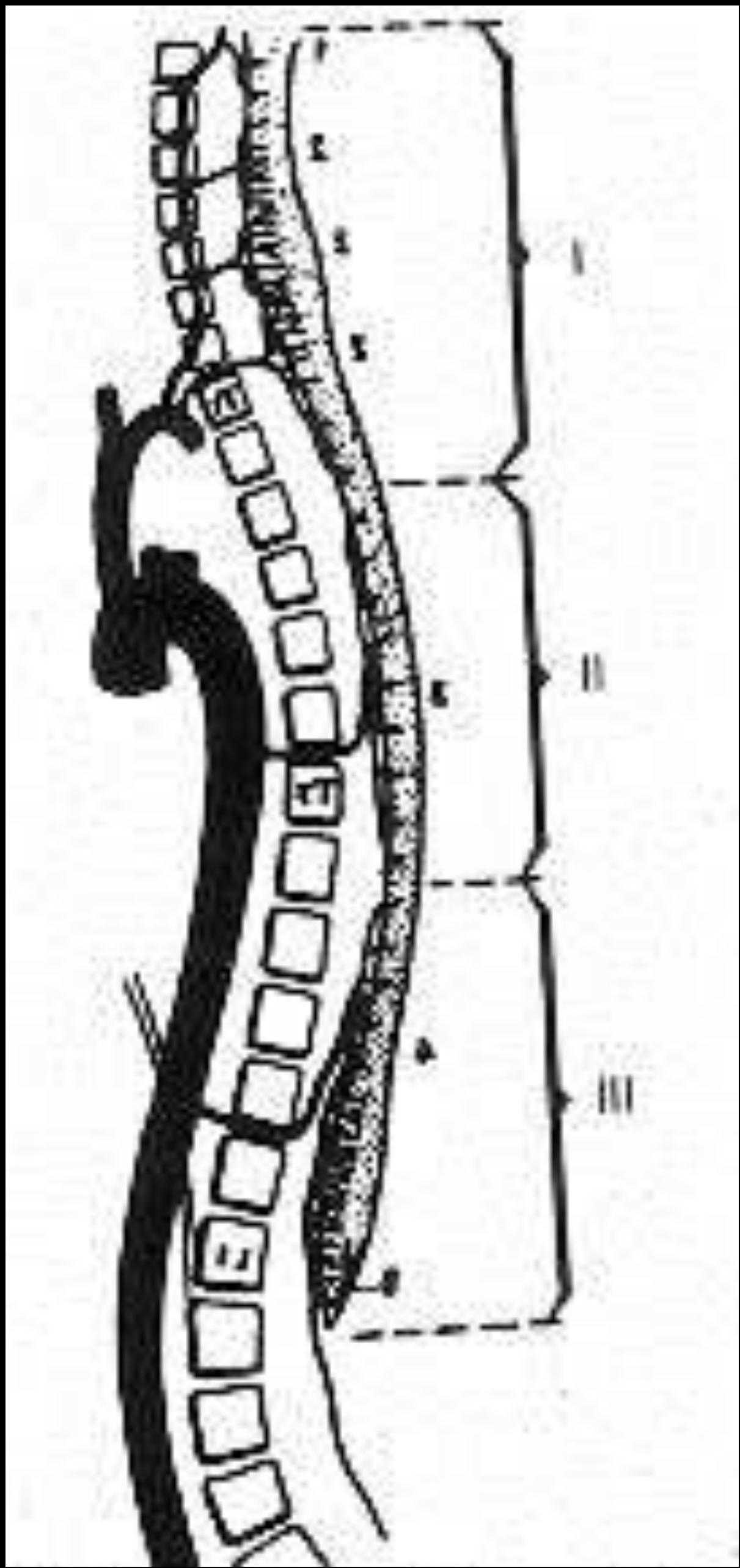

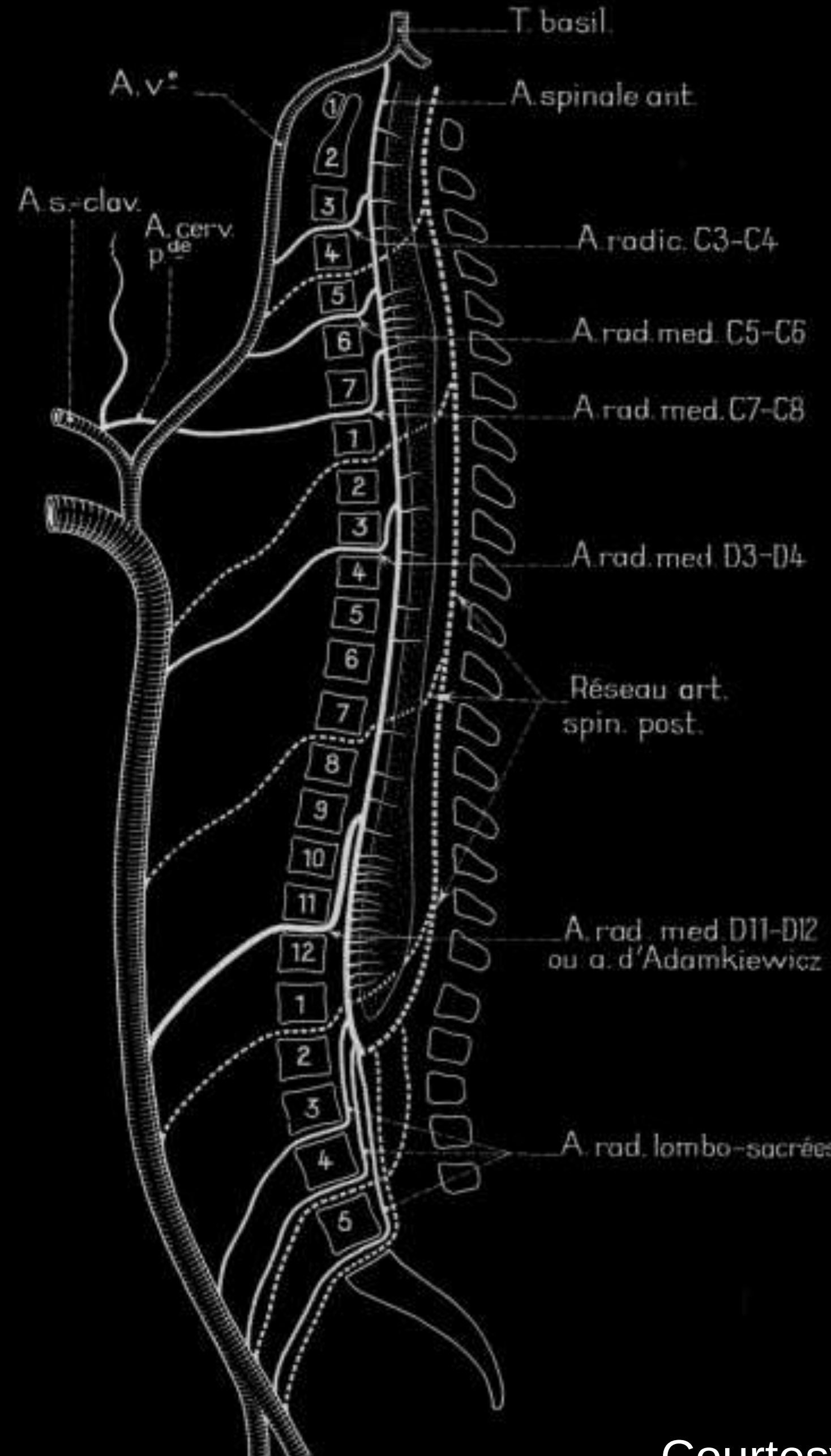

FIG. 8.

Courtesy of Philippe Gailloud, MD

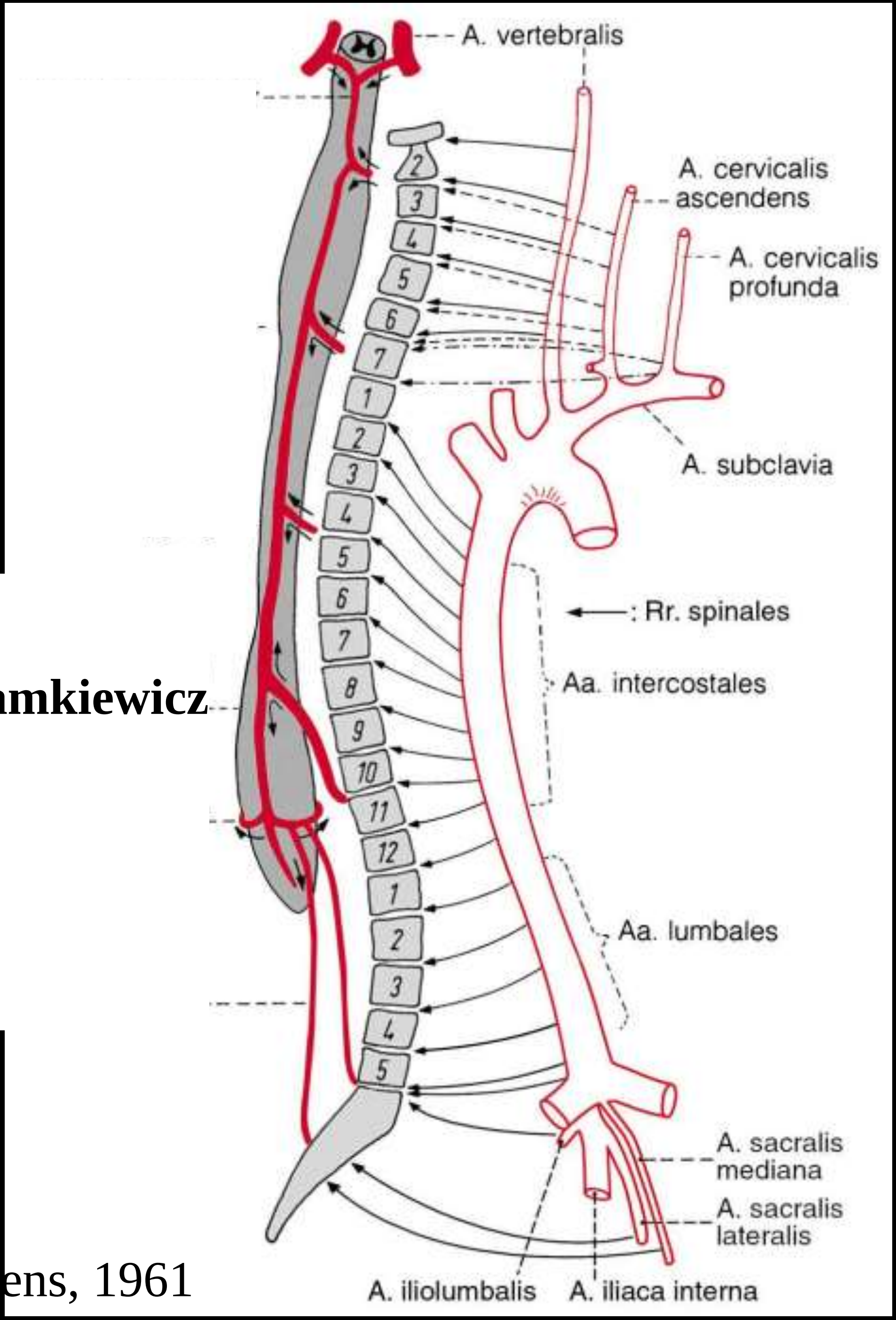
A. vertebralis
A. cervicalis ascendens
A. cervicalis profunda
A. subclavia
: Rr. spinales
Aa. intercostales
Aa. lumbales
A. sacralis mediana
A. sacralis lateralis
A. iliolumbalis
A. iliaca interna
mkiewicz

ens, 1961

Major Radiculomedullary Arteries

- C3 – arises from vertebral artery.
- C6 – (artery of cervical enlargement), arises from thyrocervical or costocervical trunk.
- T4 or T5 – arises from intercostal artery.
- T8 to conus – artery of lumbar enlargement (Adamkiewicz) aka. Arteria radicularis anterior magna.
  - Arises from an intercostal or lumbar artery.
  - "Hairpin-loop" configuration due to differential growth of spinal and spinal cord.

Contributors to Anterior Spinal Artery

Multiple vertebral contributors

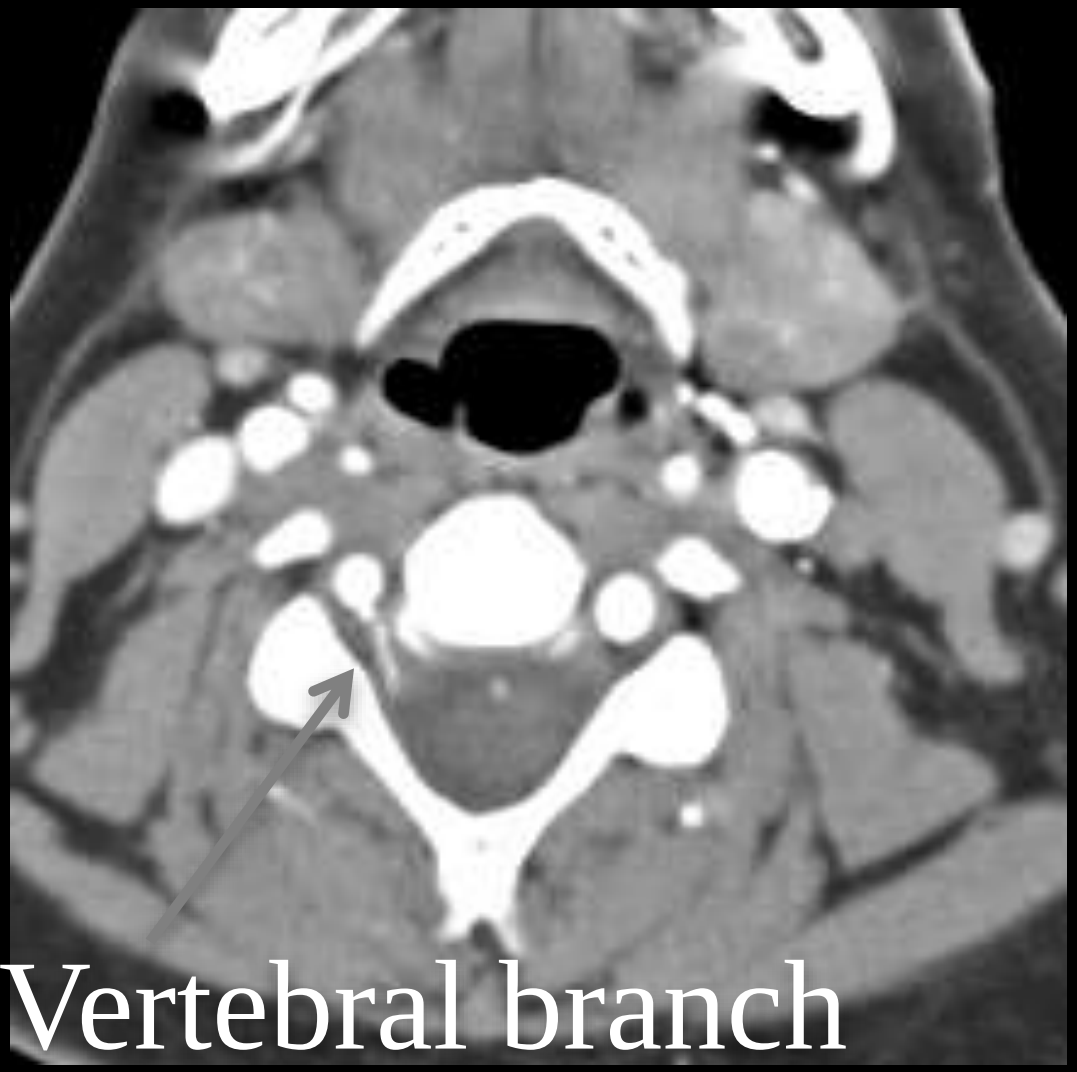

Thyro-cervical trunk

functional adaptation

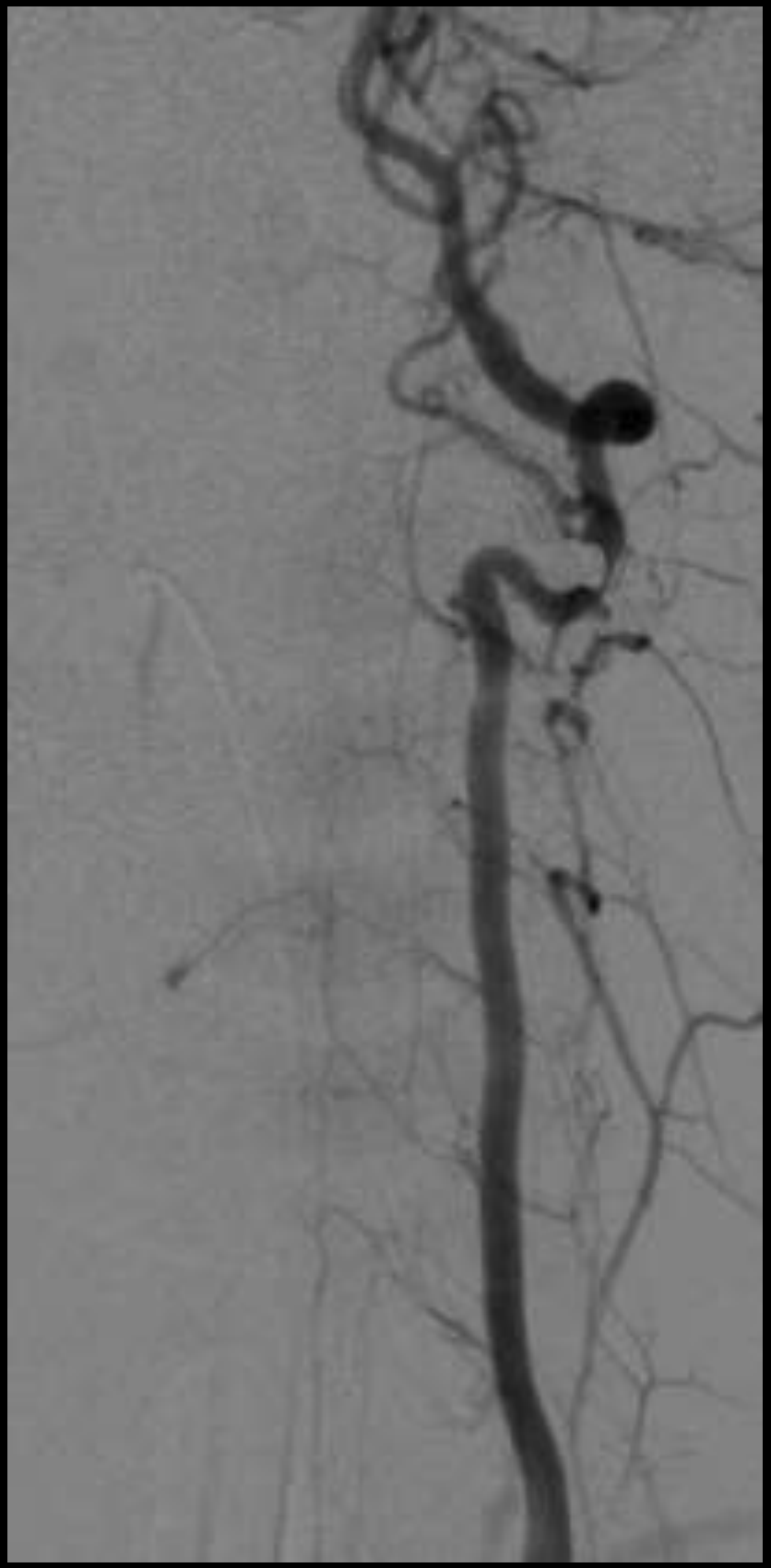

artery of the cervical enlargement

Courtesy of Philippe Gailloud, MD

Thyro-cervical trunk contributes to ASA via left C6 foramen

Coronal multiplanar reformations from contrast-enhanced T1-weighted gradient-echo MR images (5.9/1.9; flip angle, 30°)

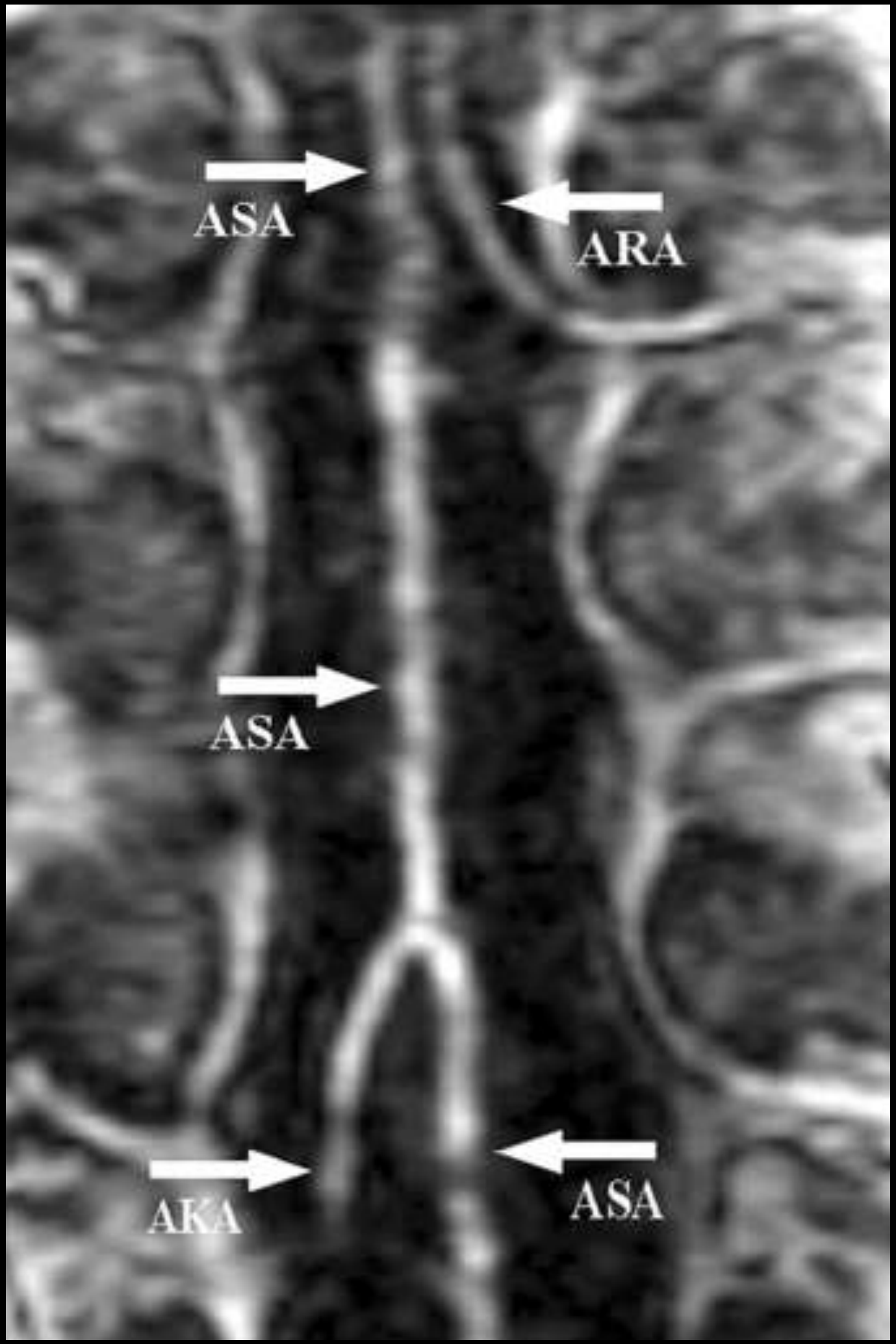

Nijenhuis R J et al. Radiology 2004;233:541-547

Radiology

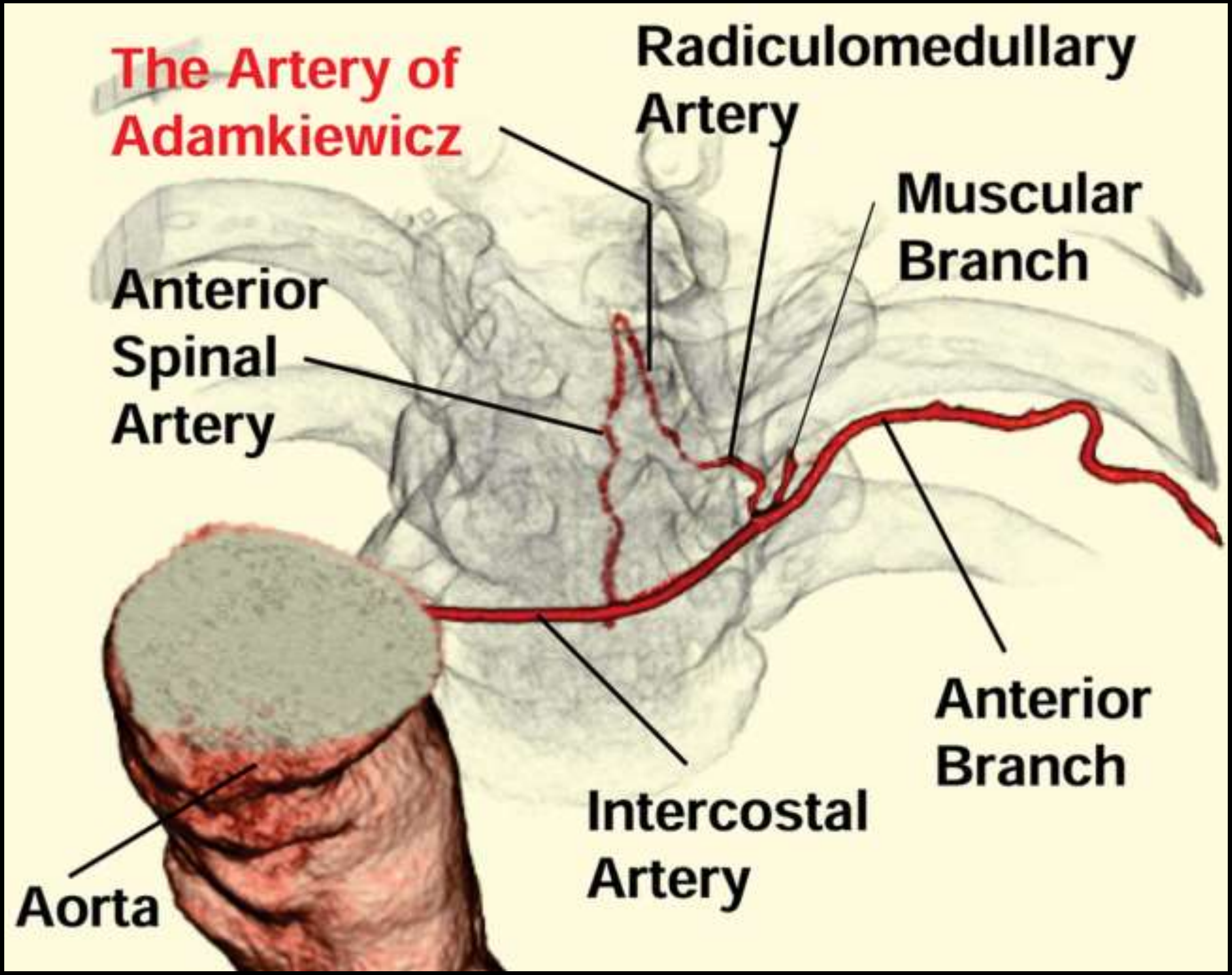

Yoshioka K et al. Radiographics 2006;26:S63-S73

RadioGraphics

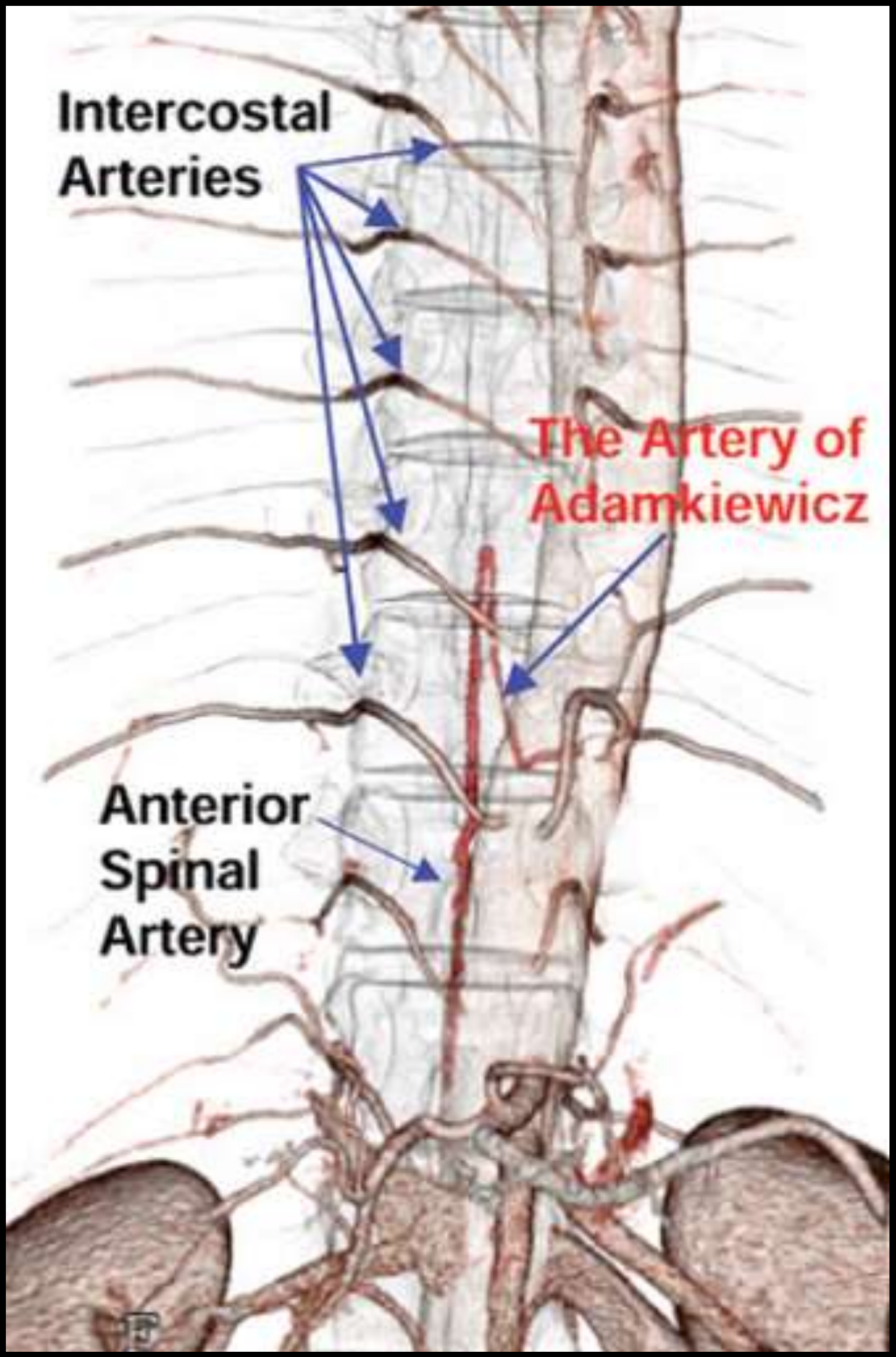

RadioGraphics

functional adaptation

artery of the lumbar enlargement
artery of Adamkiewicz

Courtesy of Philippe Gailloud, MD


T11

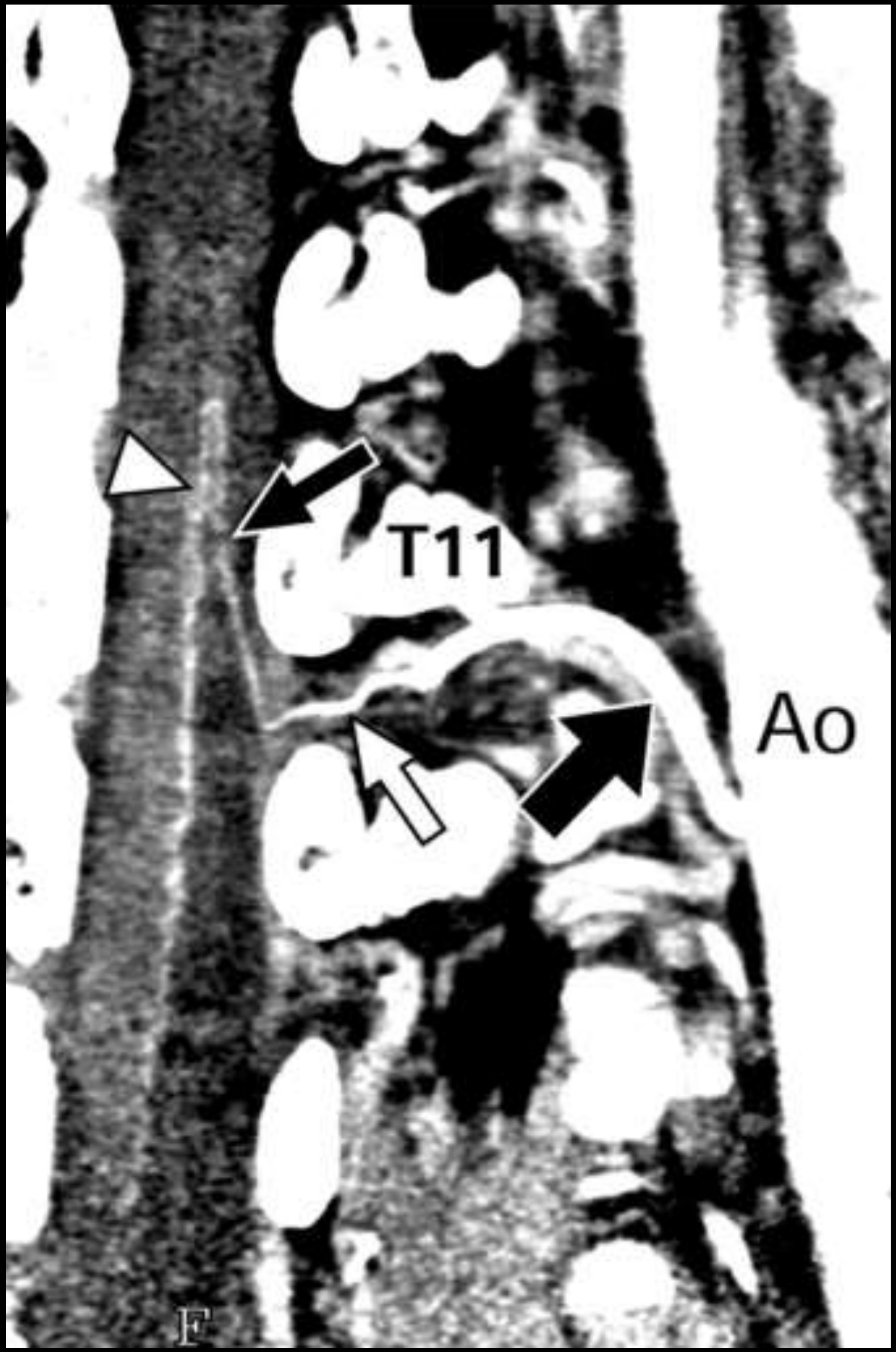

RadioGraphics

Artery of Adamkiewicz

functional adaptation

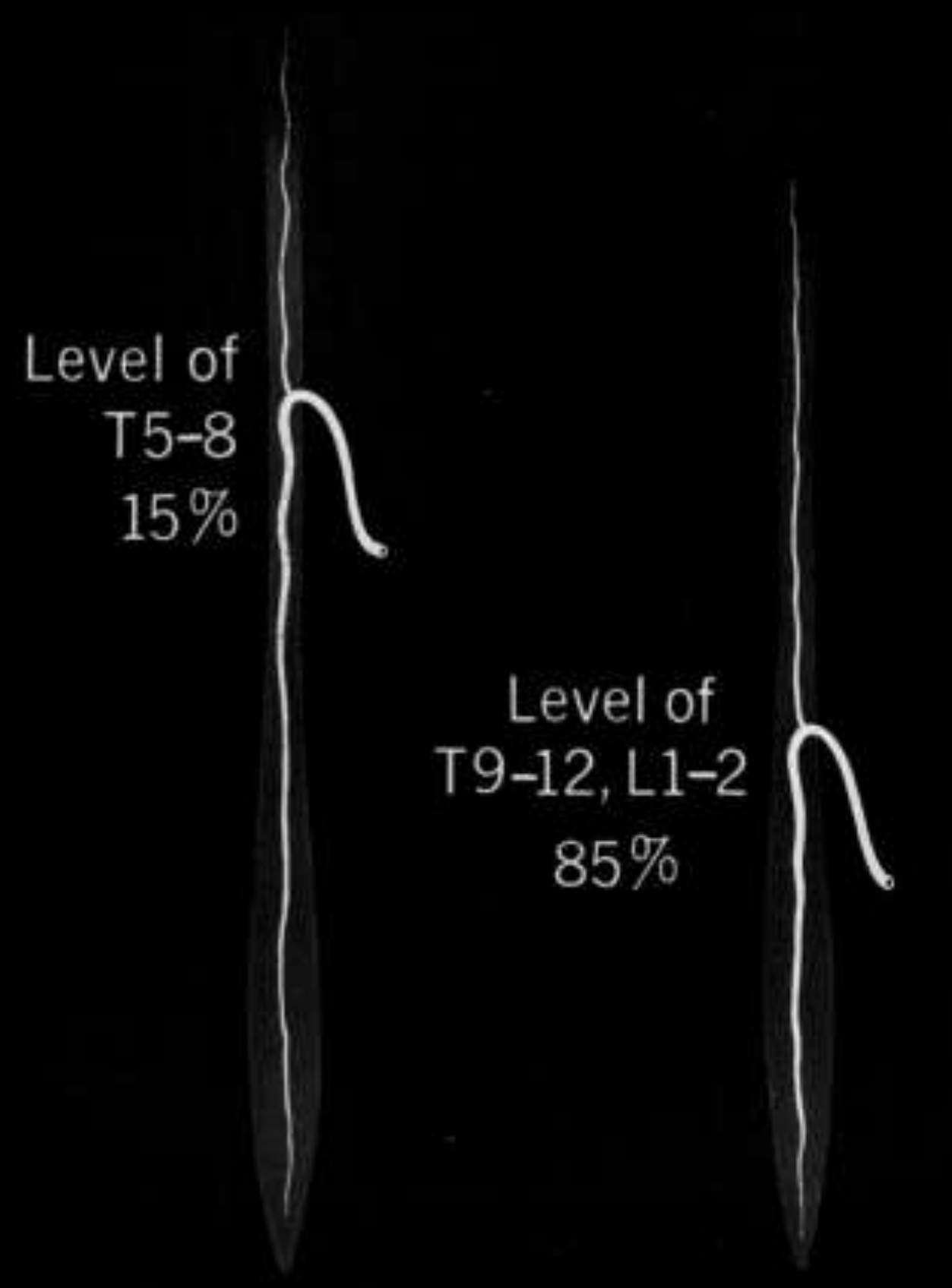

artery of the lumbar enlargement
artery of Adamkiewicz

Courtesy of Philippe Gailloud, MD

Spinal Arteries

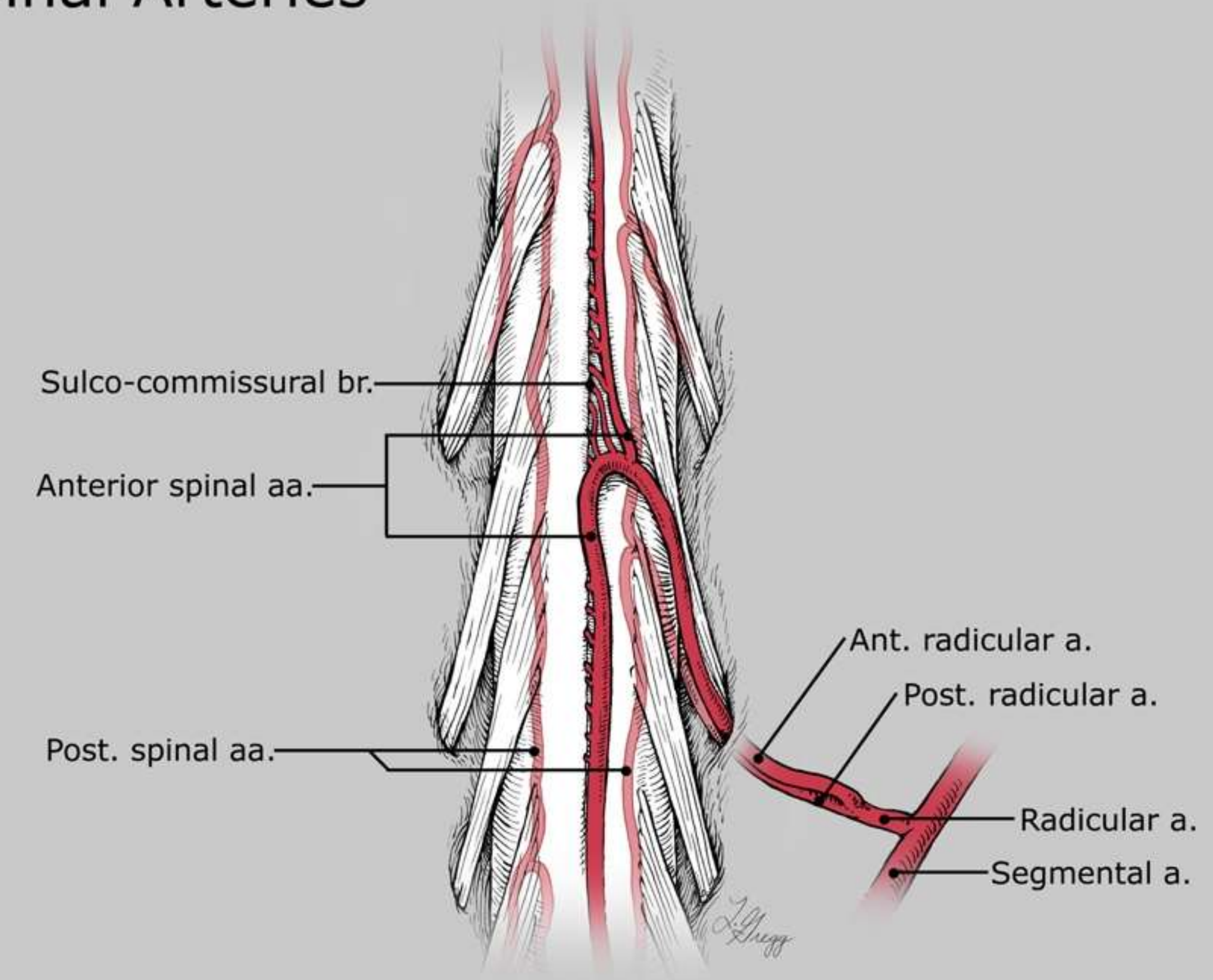

Courtesy of Philippe Gailloud, MD

Posterior Spinal Arteries

- Smaller and more uniform in caliber compared to the ASA.
- Frequent inter-communications across the dorsal surface of the cord connect the two PSA’s.
- Infrequent intercommunications along the lateral surfaces of the cord between the PSA’s and the ASA (circumferential pial arterial plexus).

the posterior spinal axis

posterior arterial network

Courtesy of Philippe Gailloud, MD

the posterior spinal axis

posterior arterial network

Courtesy of Philippe Gailloud, MD

Posterior Spinal Artery

Anastamoses Between ASA & PSA's

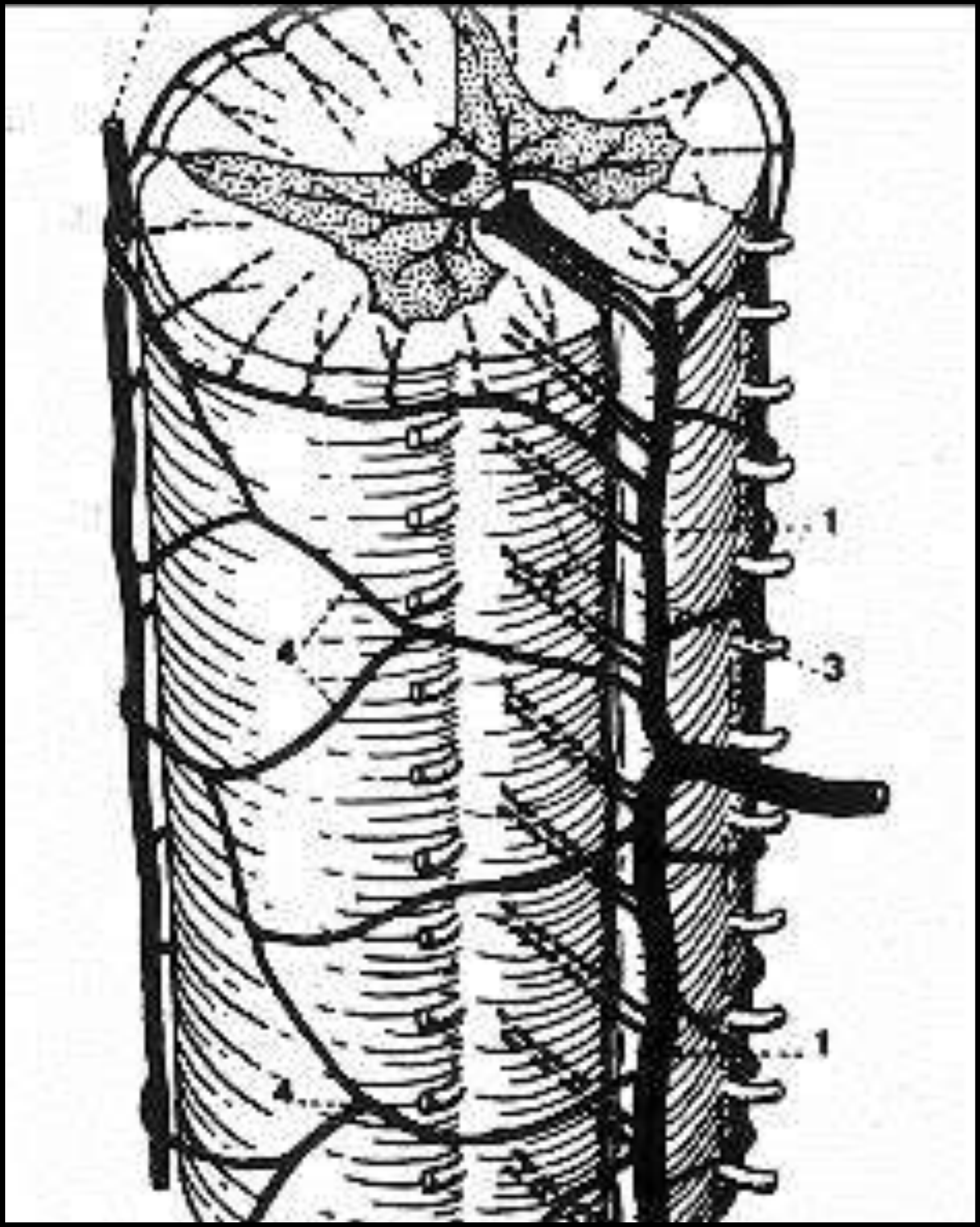

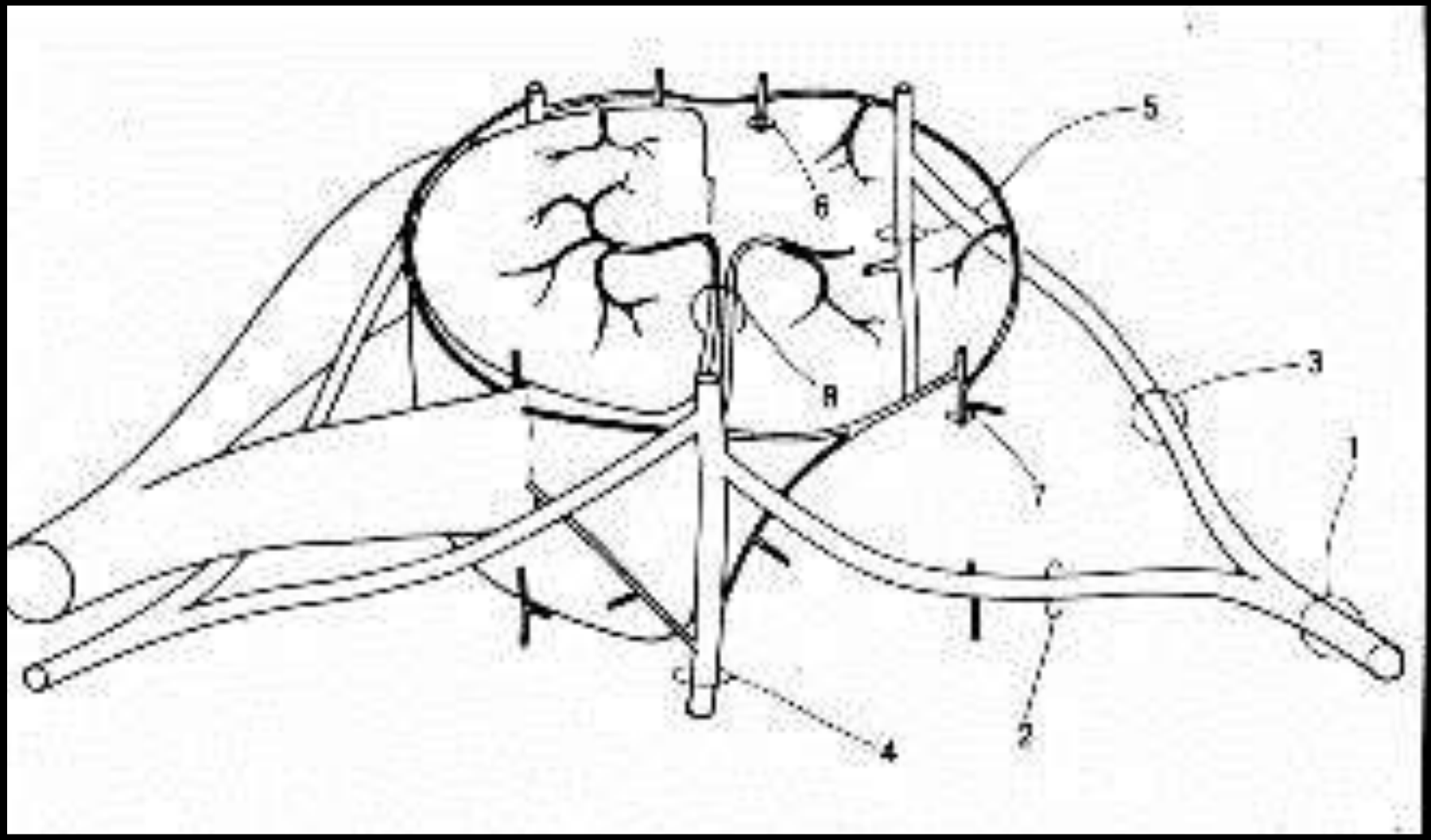

intraspinal arterial circulation

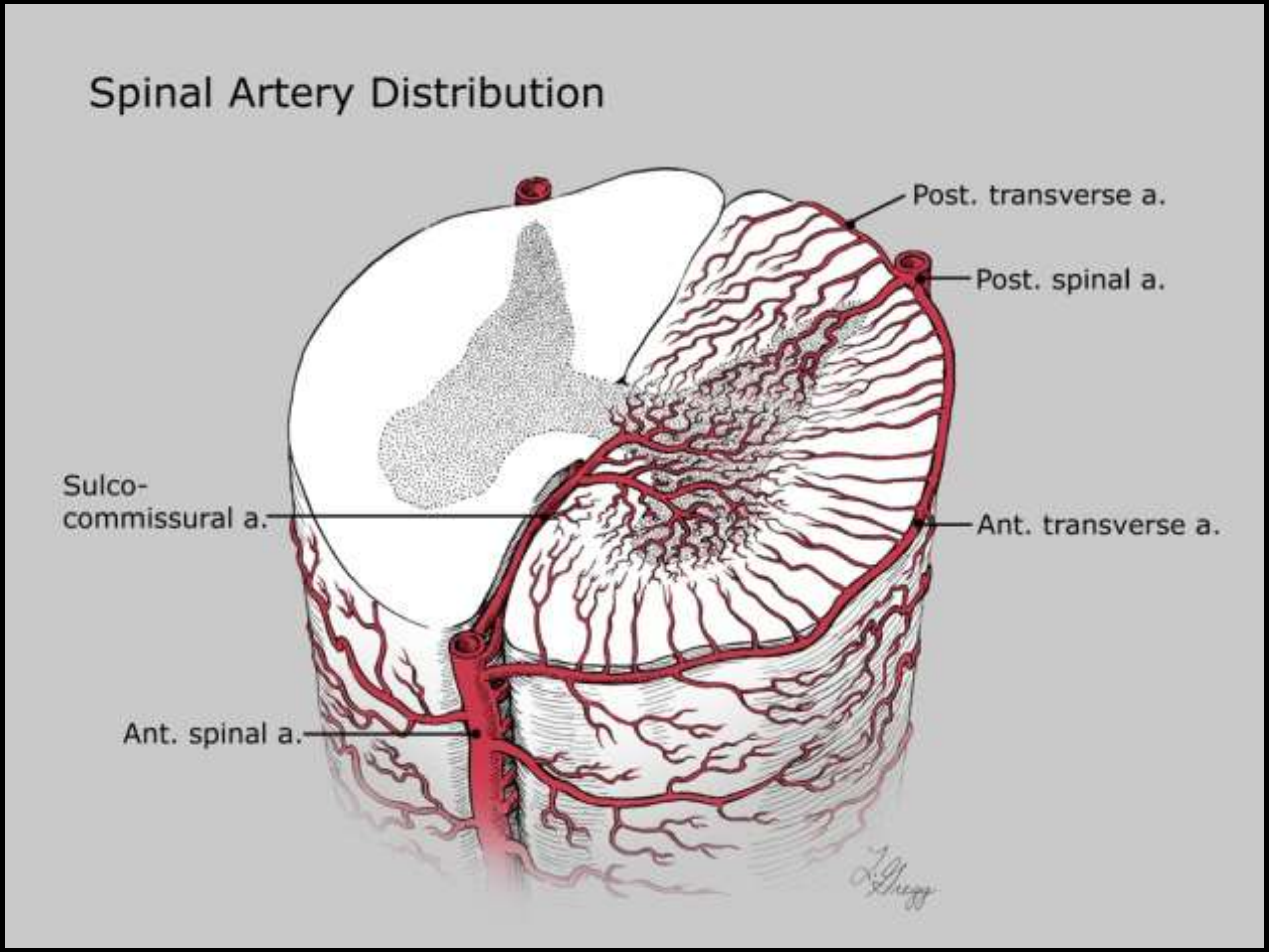

Courtesy of Philippe Gailloud, MD

Arterial supply

Ventral

Dorsal

Microangiogram from Nolte

There is one anterior spinal artery

Two posterior spinal arteries

Anterior spinal artery feeds the central cord (arrow)

(Nolte Fig 10-30)

intraspinal arterial circulation

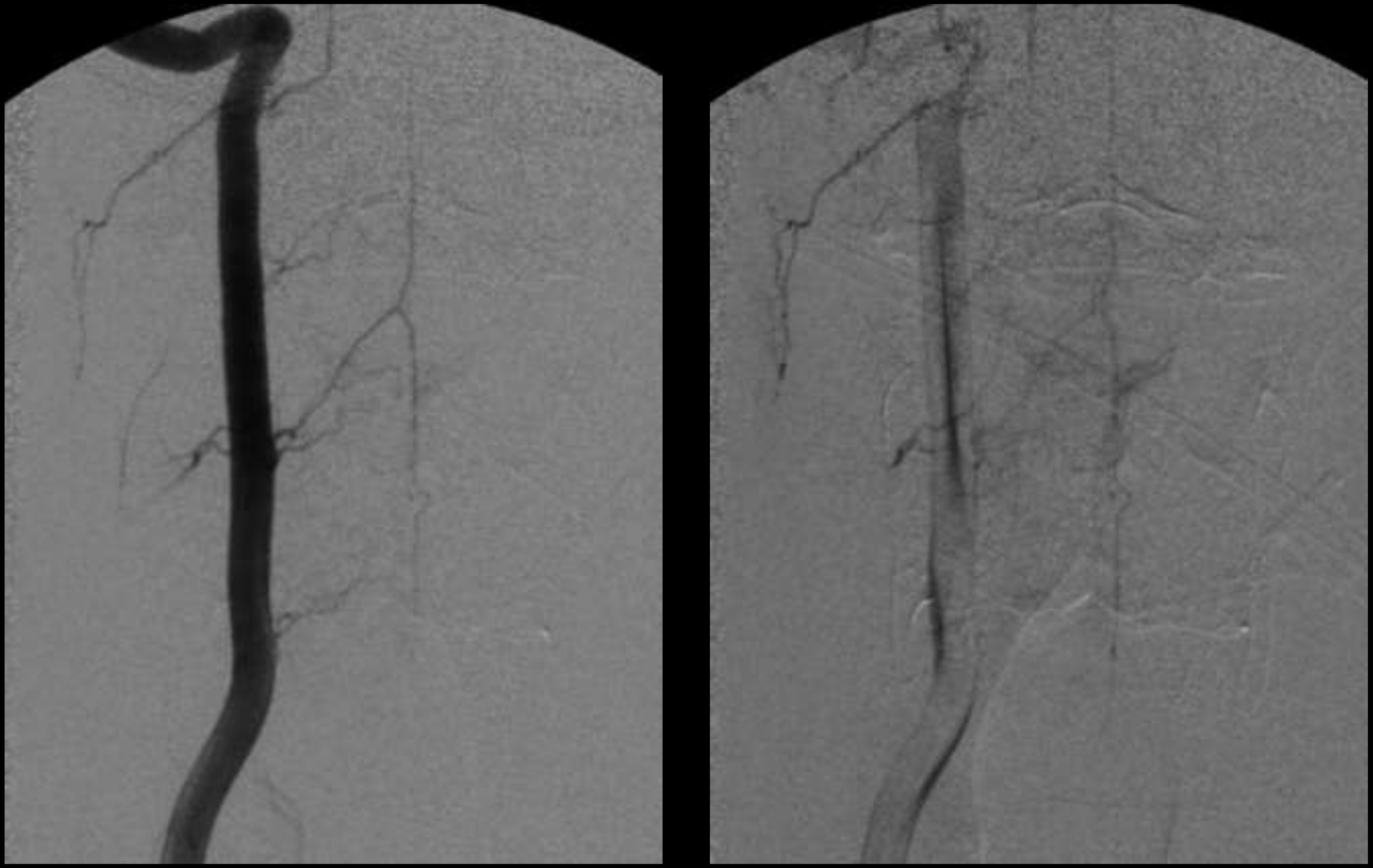

the sulcocomissural arteries

Courtesy of Philippe Gailloud, MD

intraspinal arterial circulation

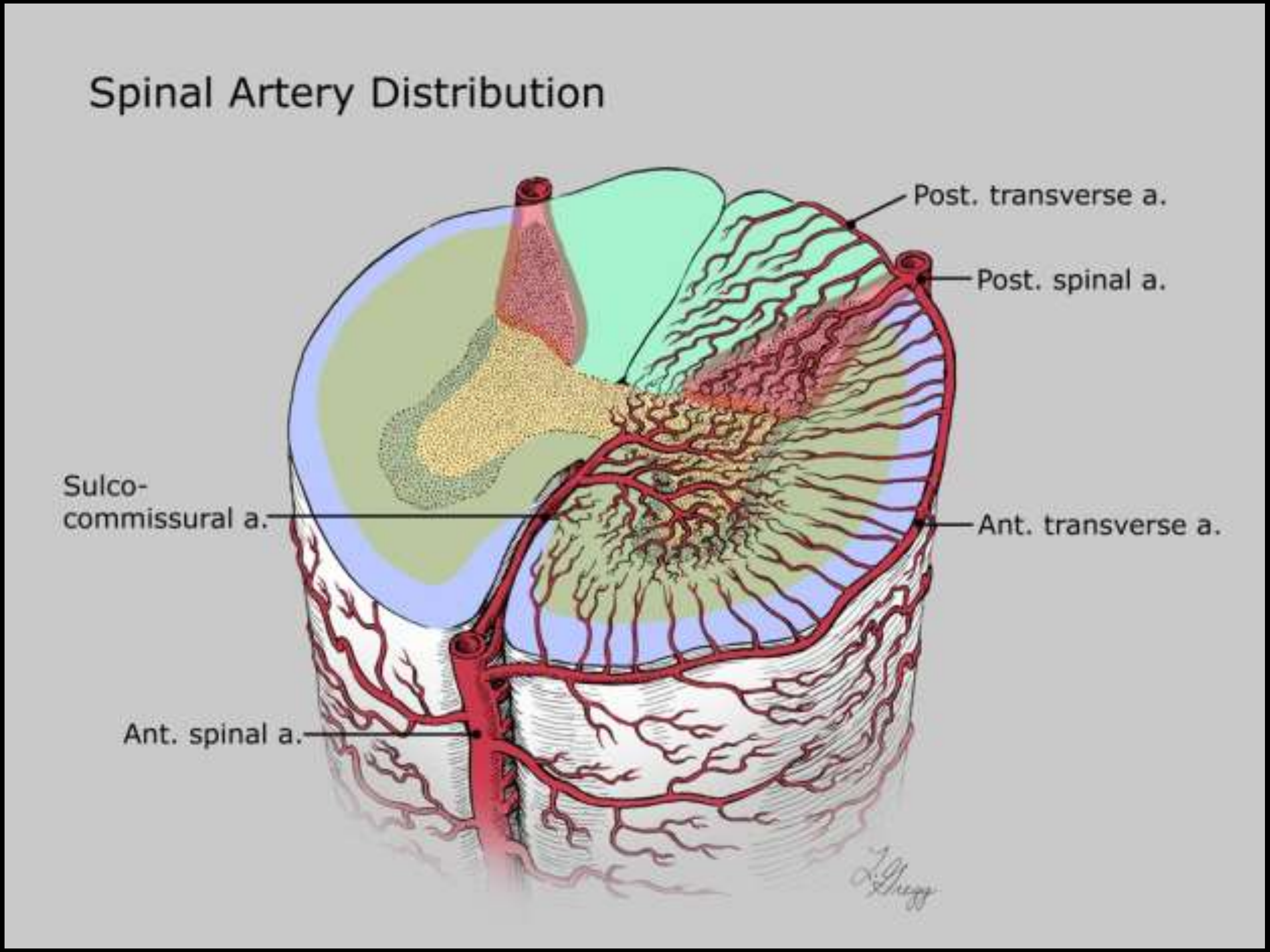

Courtesy of Philippe Gailloud, MD

intraspinal arterial circulation

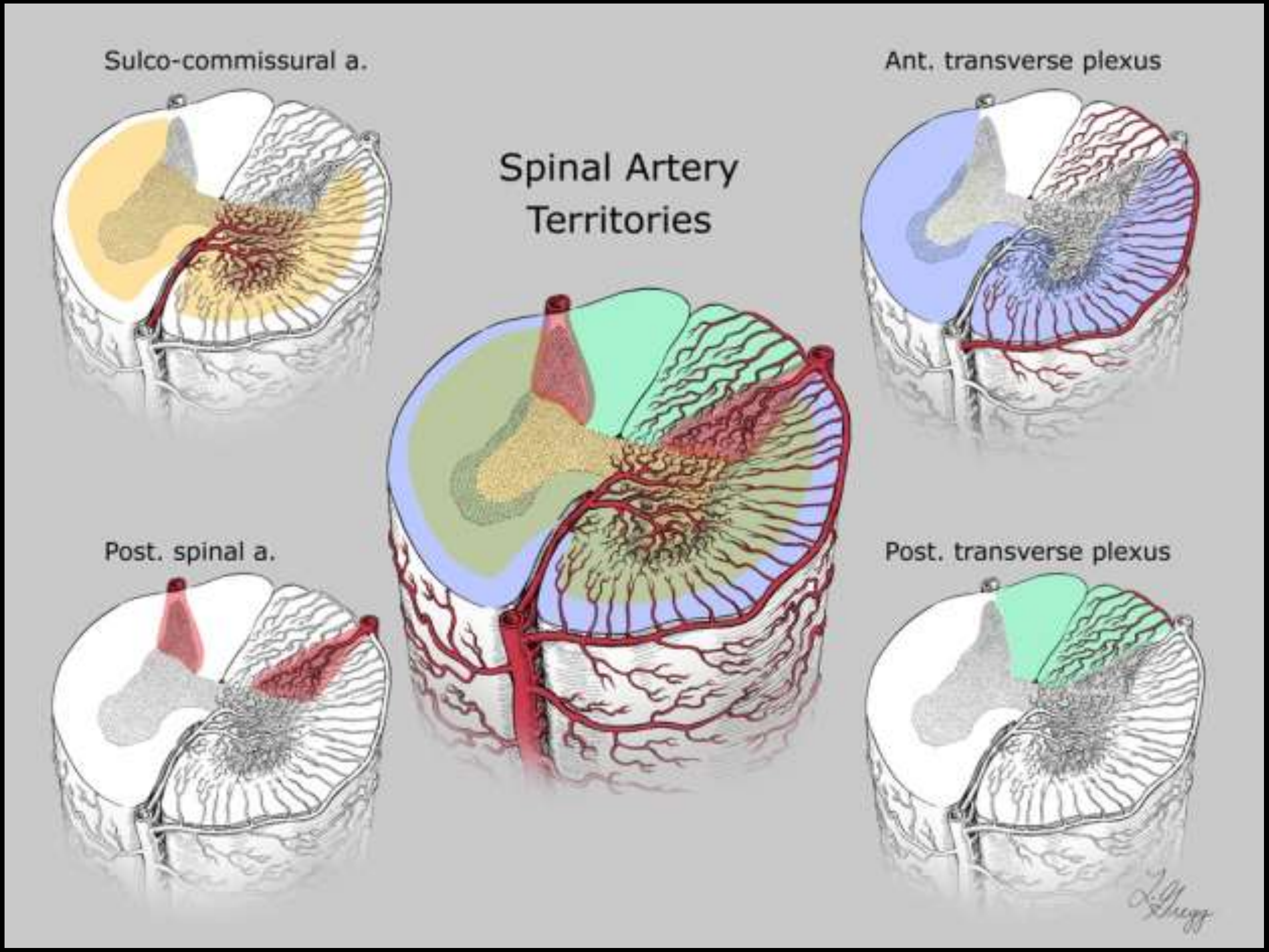

Courtesy of Philippe Gailloud, MD

Venous Drainage

- Venous blood drains into external vertebral plexus and then internal plexus via basivertebral veins
- Basivertebral plexus has “Y” appearance on axial view
- Cord and vertebral plexi drain via radicular and intervertebral veins through neuroforamina into vertebral vein, ascending lumbar veins, and azygous system

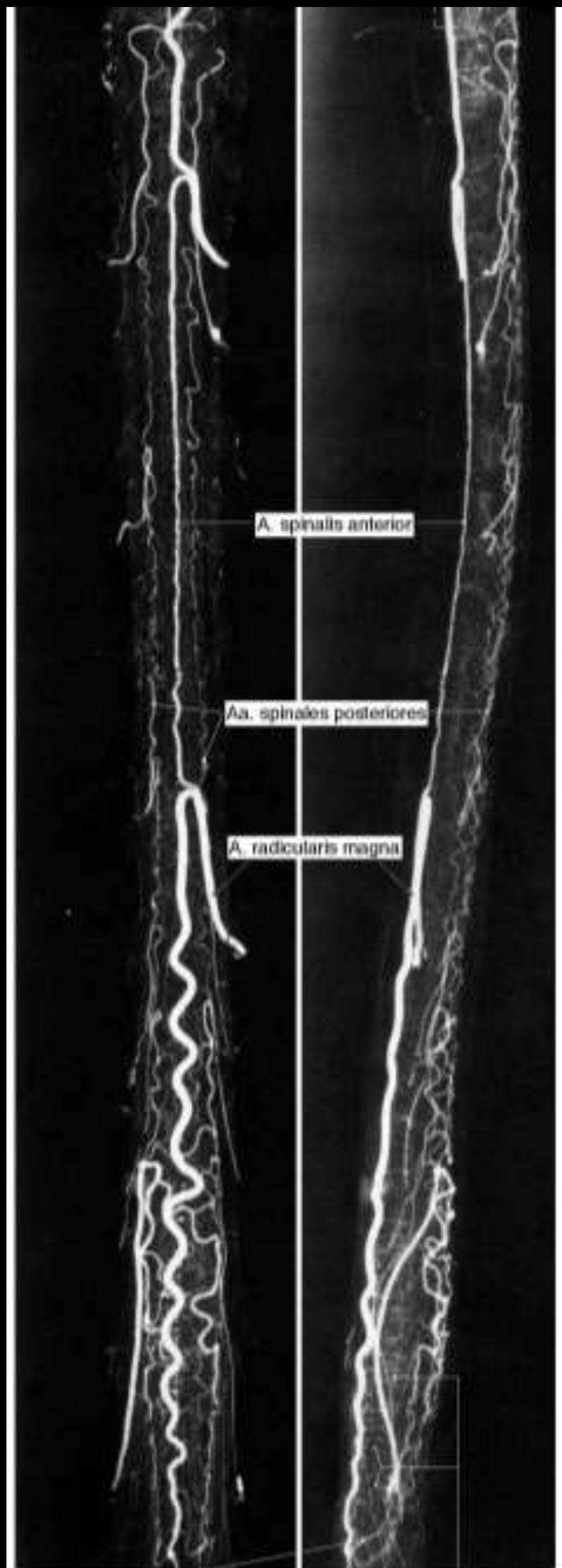
A. spinalis anterior
Aa. spinales posteriores
A. radicularis magna

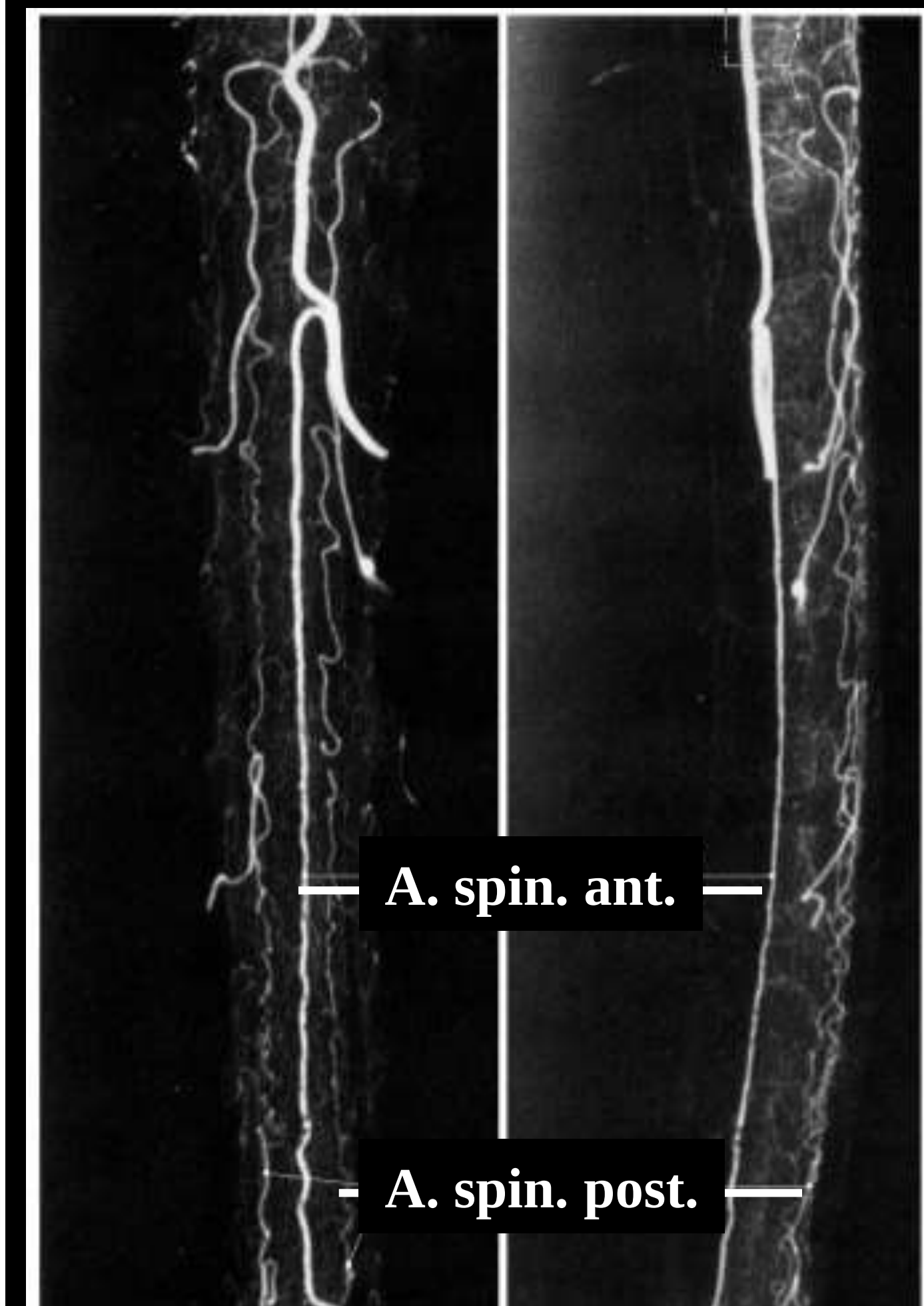
A. spin. ant.
A. spin. post.

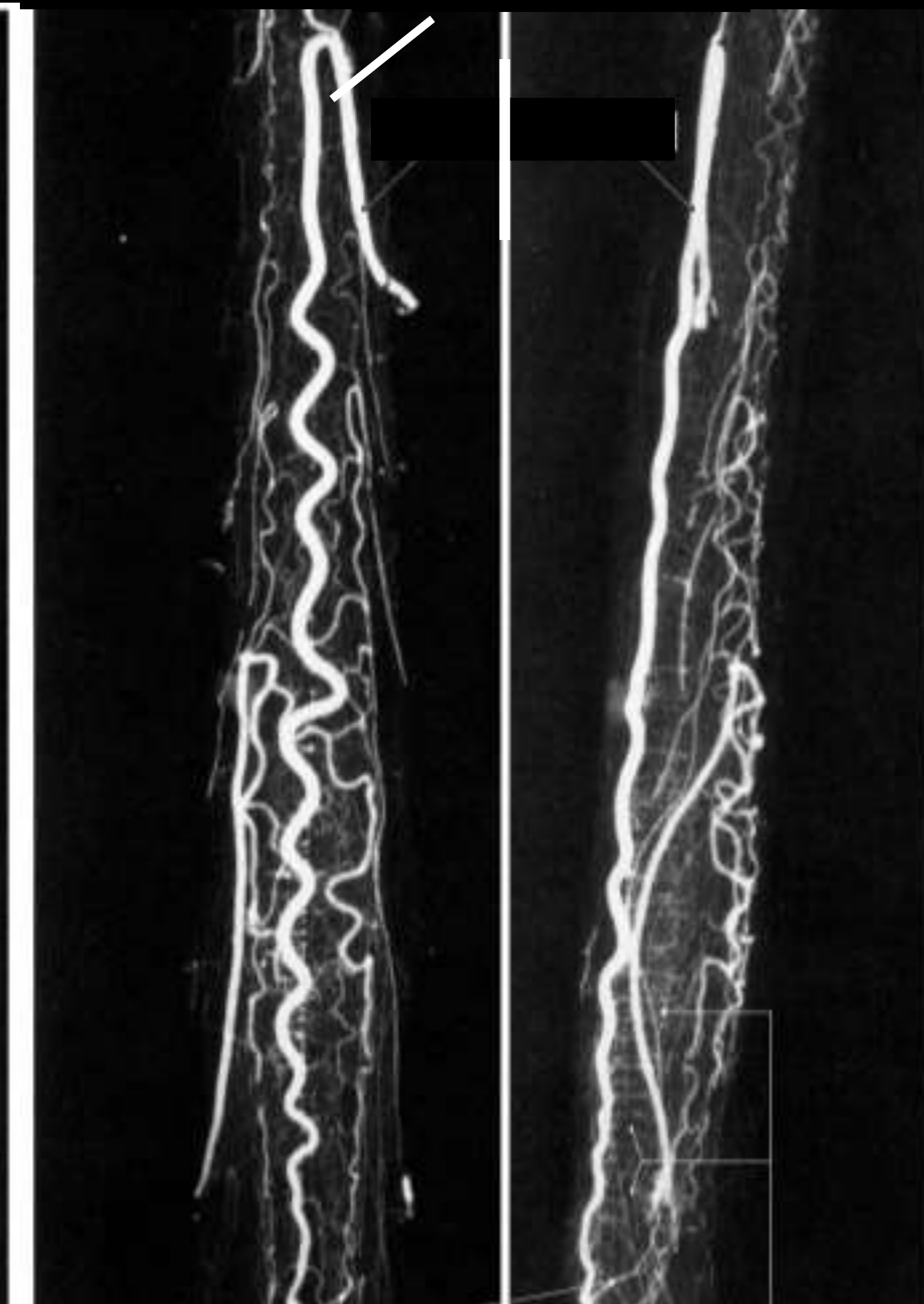
A. rad. magna

Cervical Veins

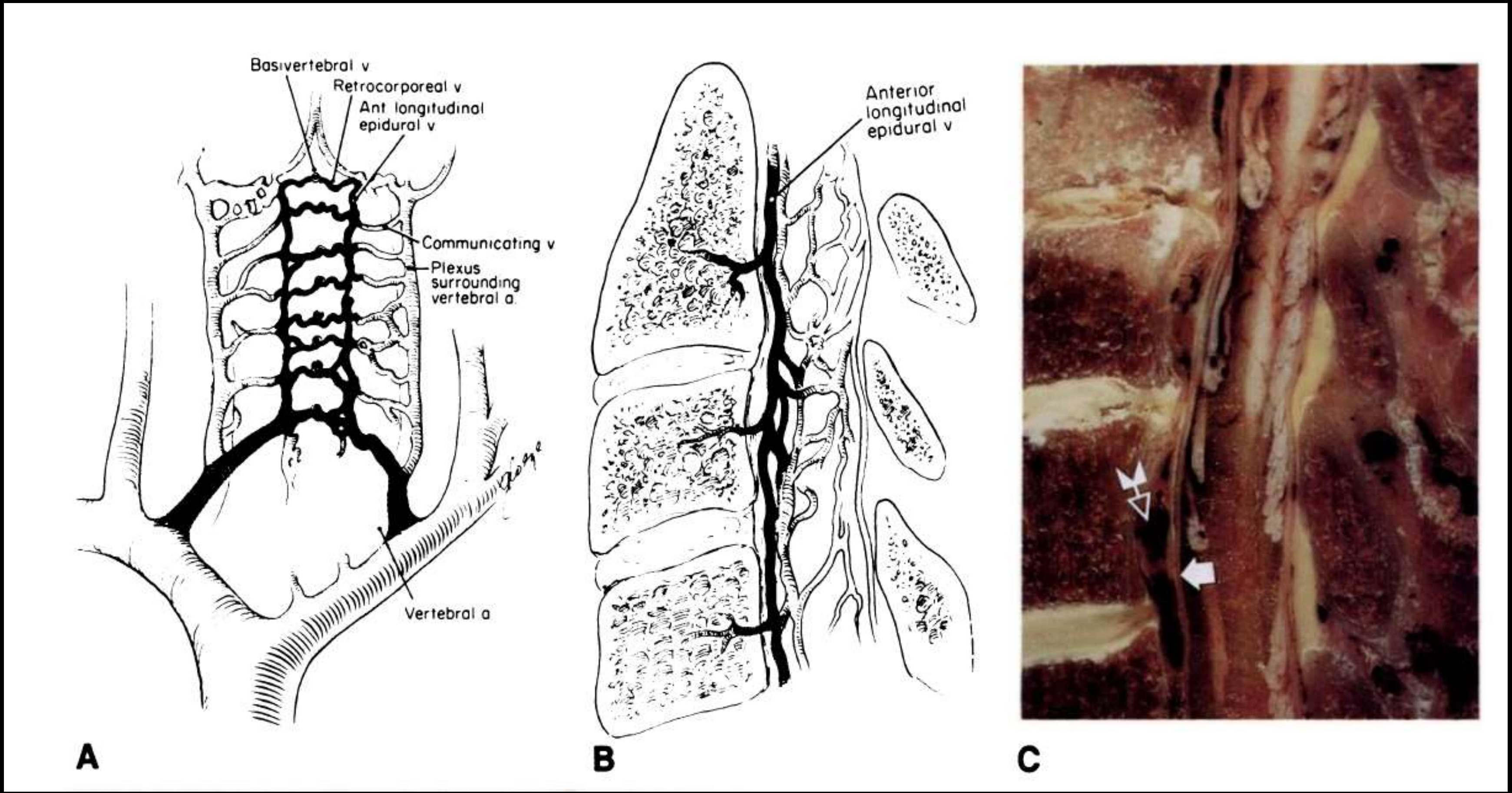

A B C

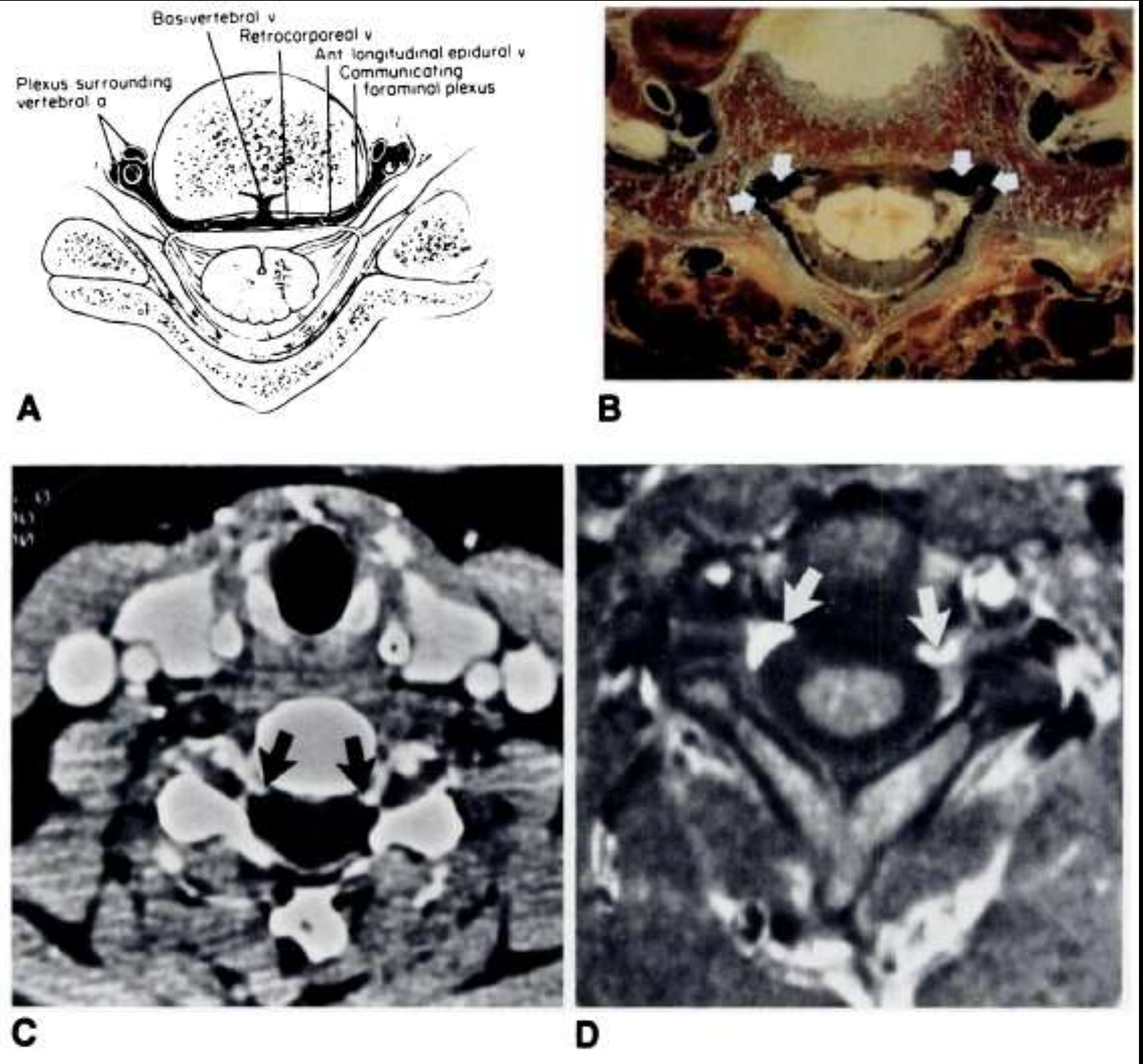

Basivertebral v
Retrocorporeal v
Ant longitudinal epidural v
Communicating foraminal plexus
Plexus surrounding vertebral a
A
B
C
D

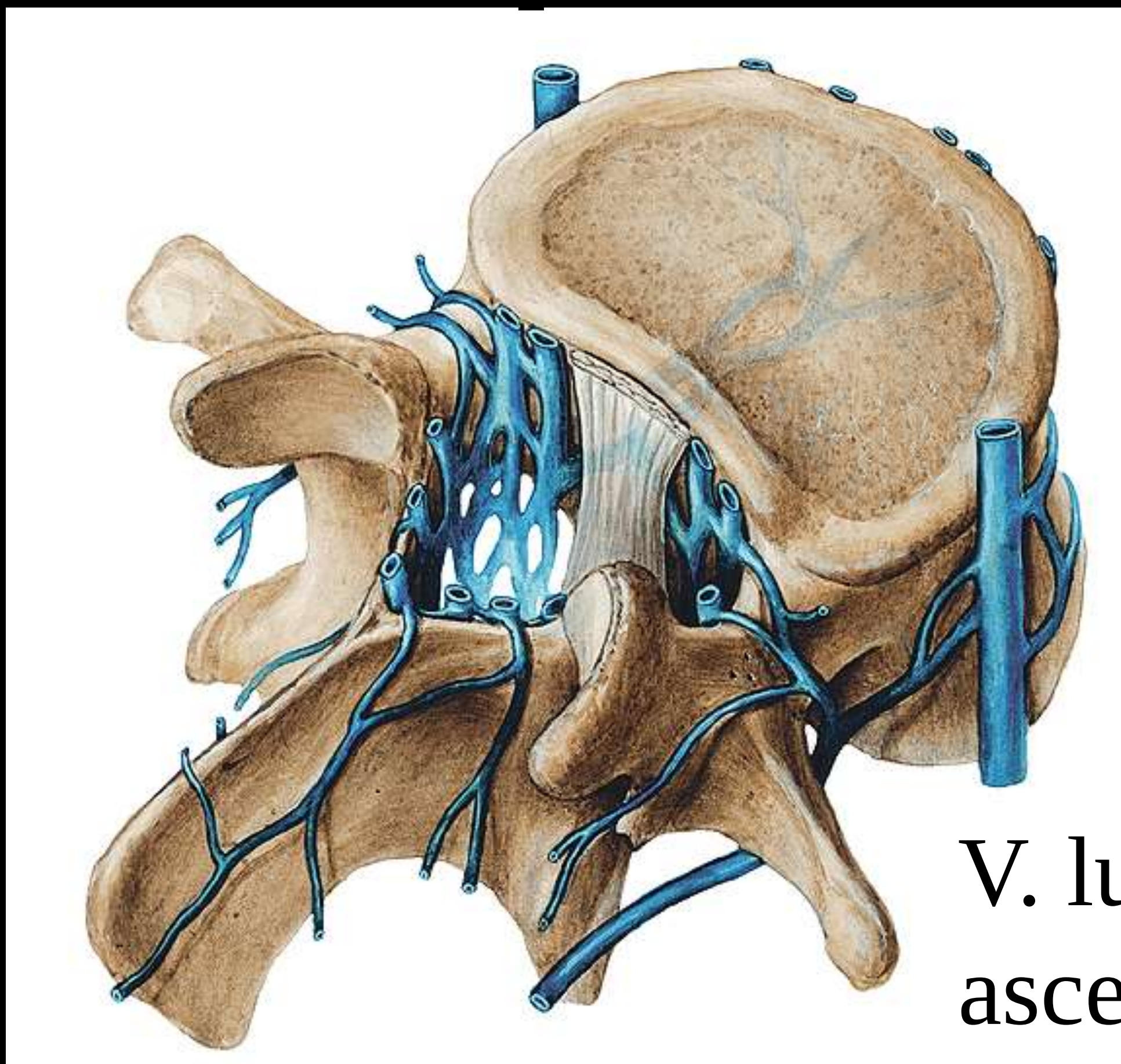
V. lu
asce

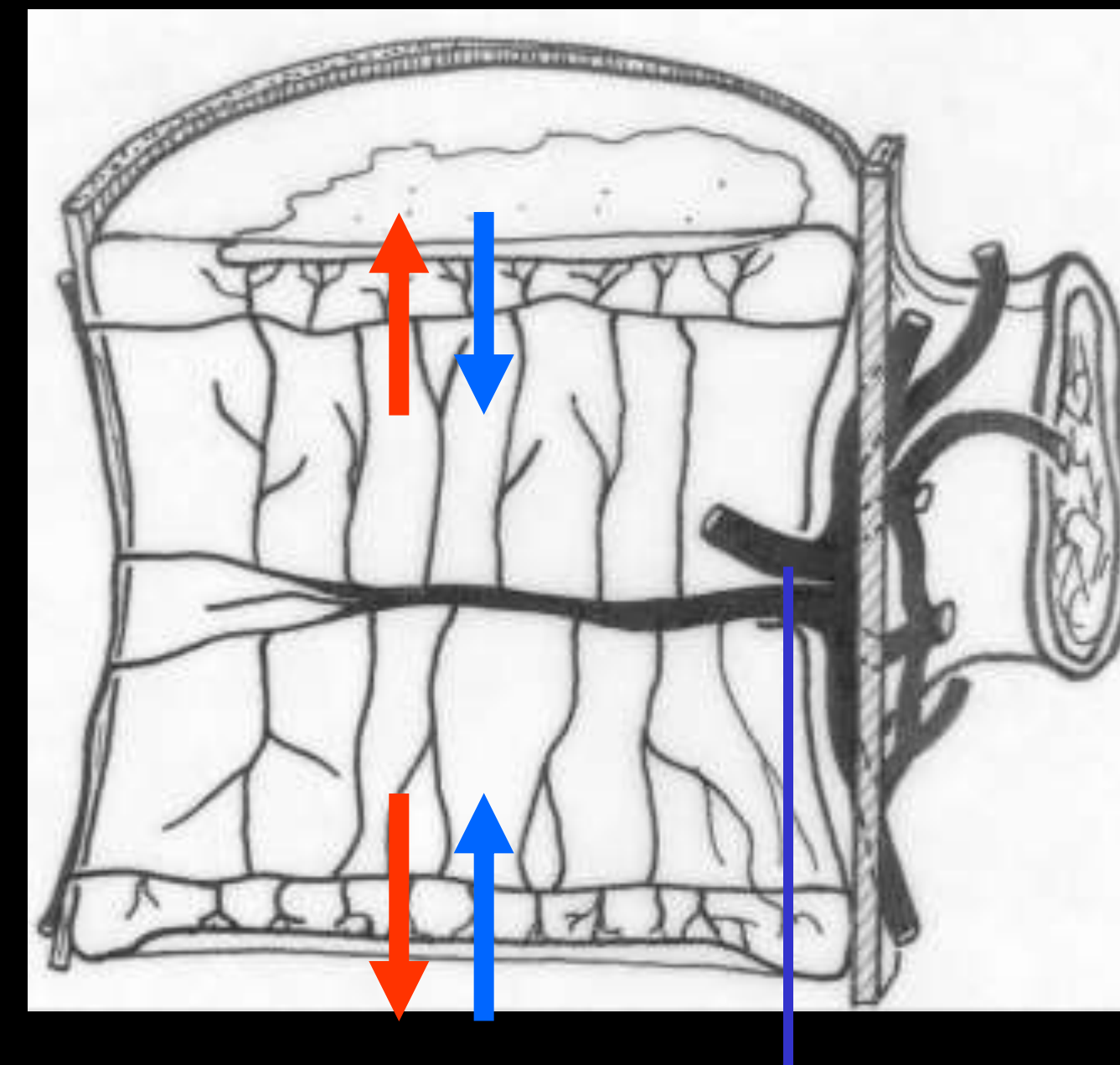

Venous Drainage

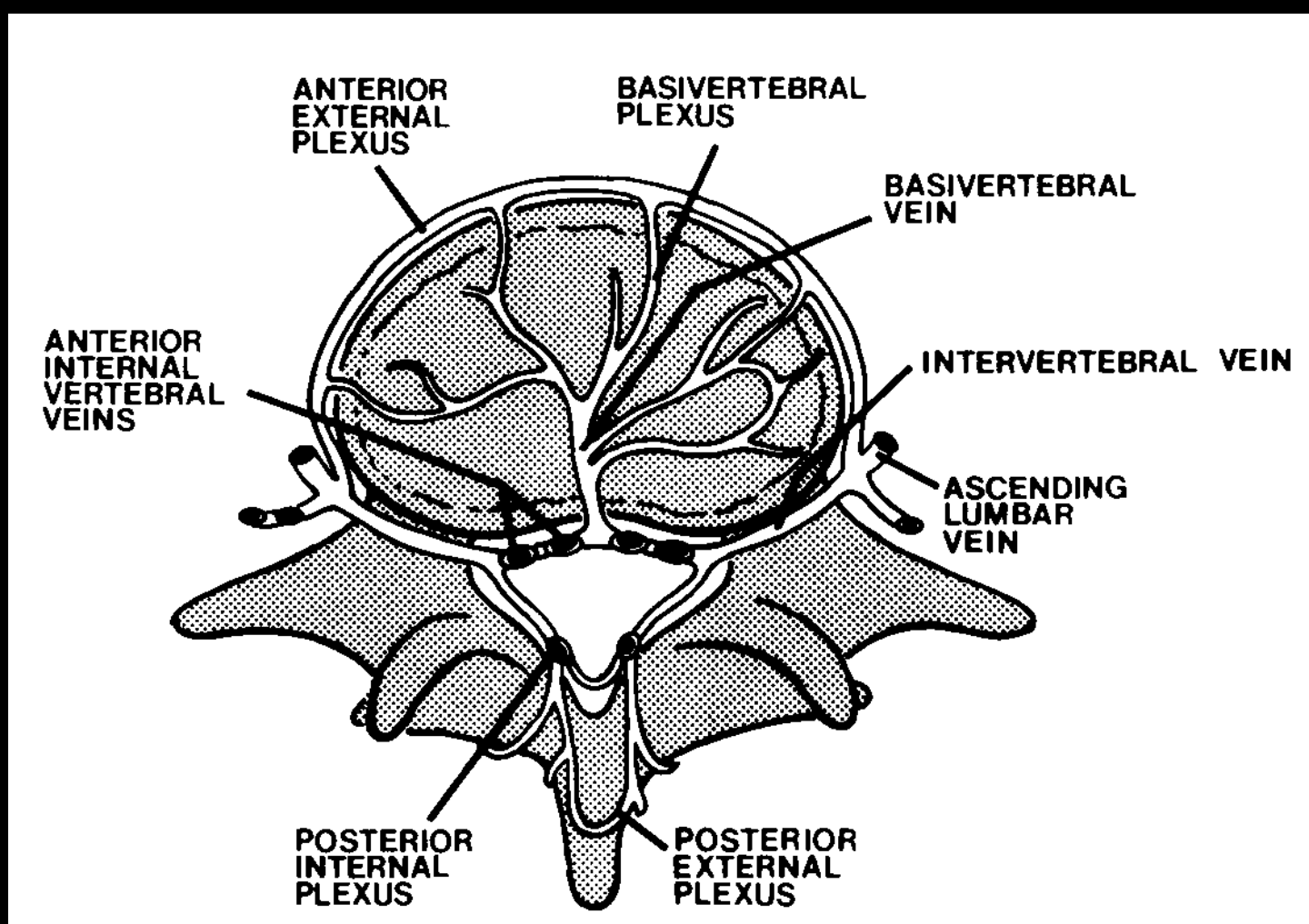

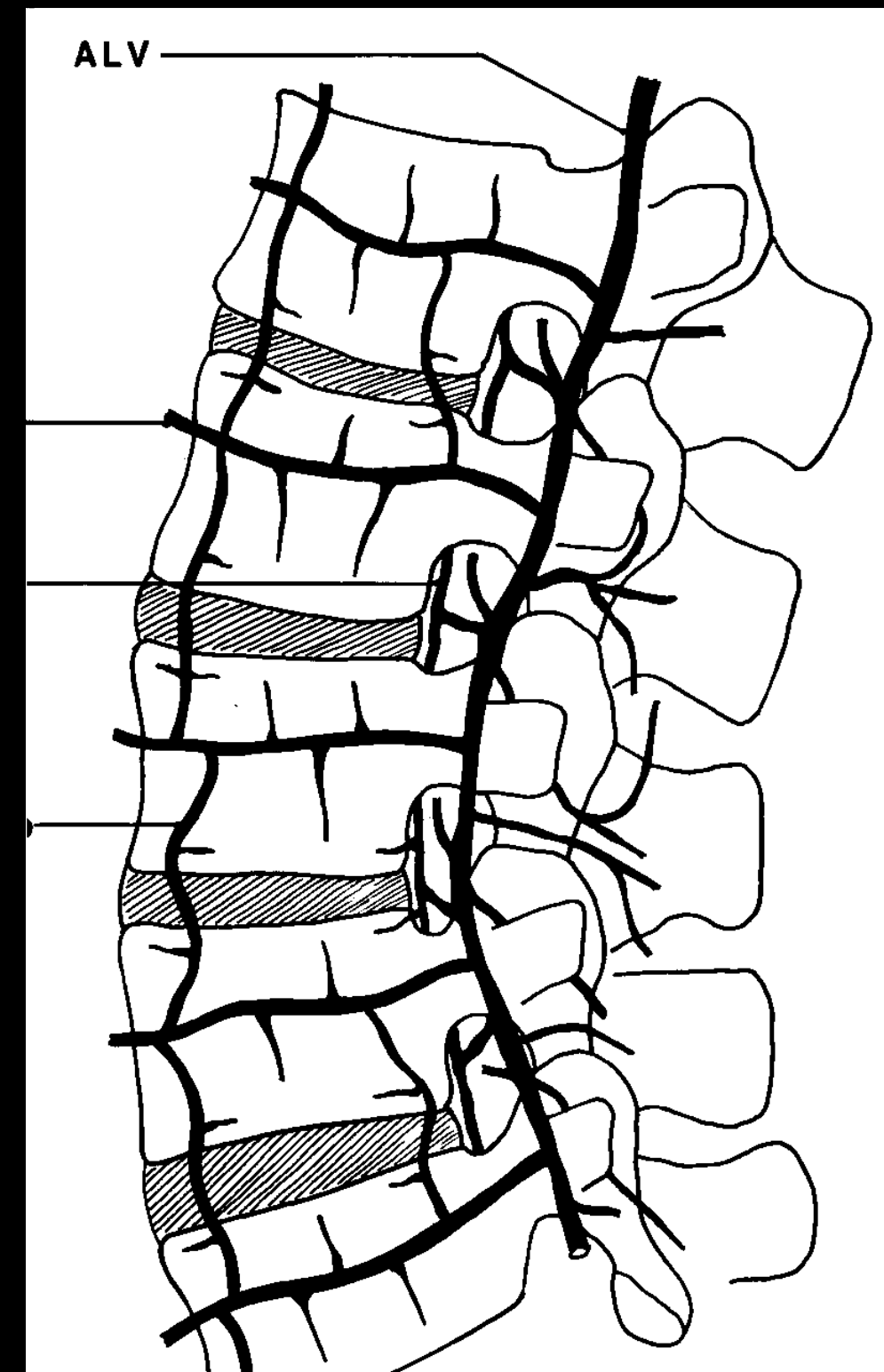

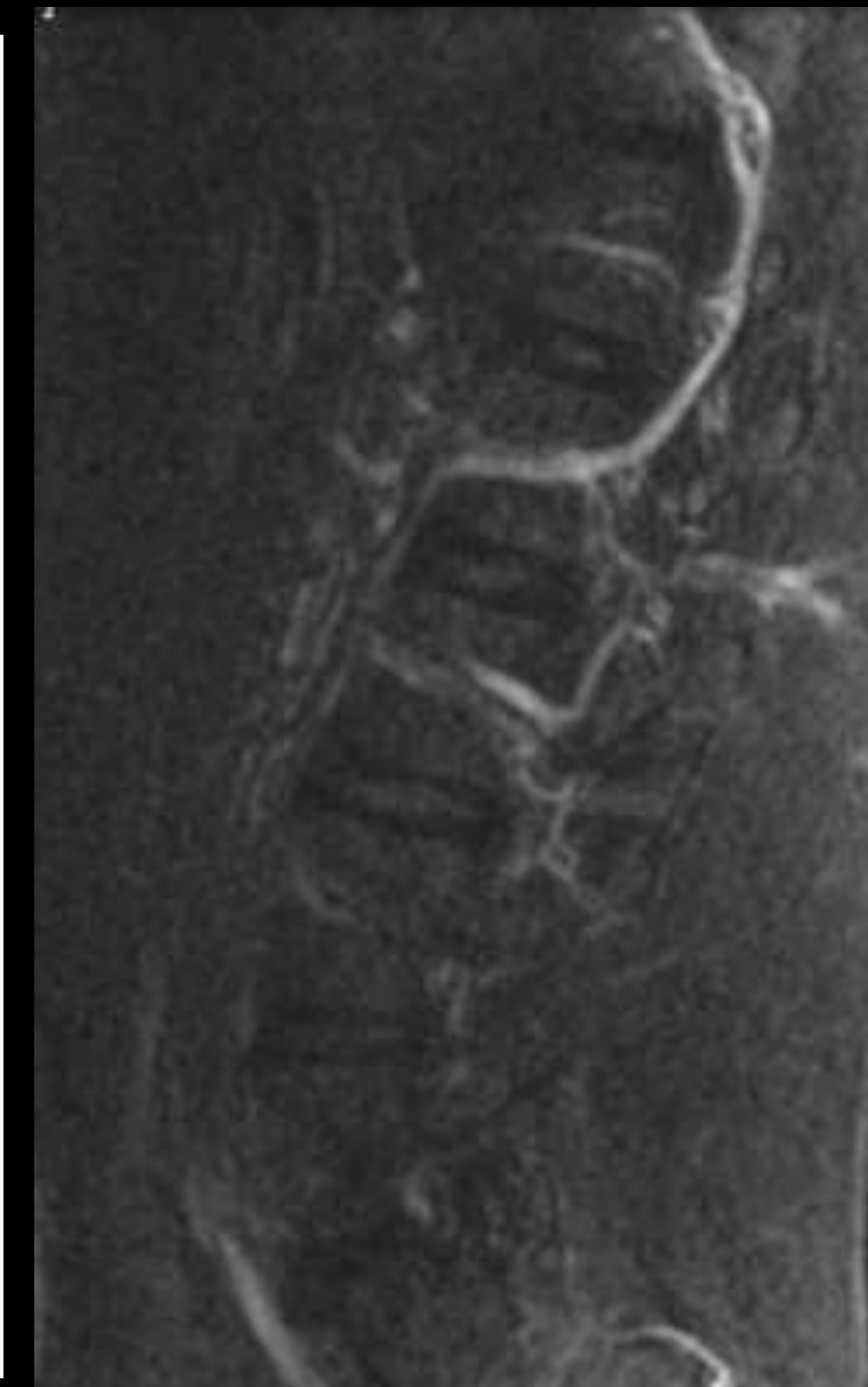

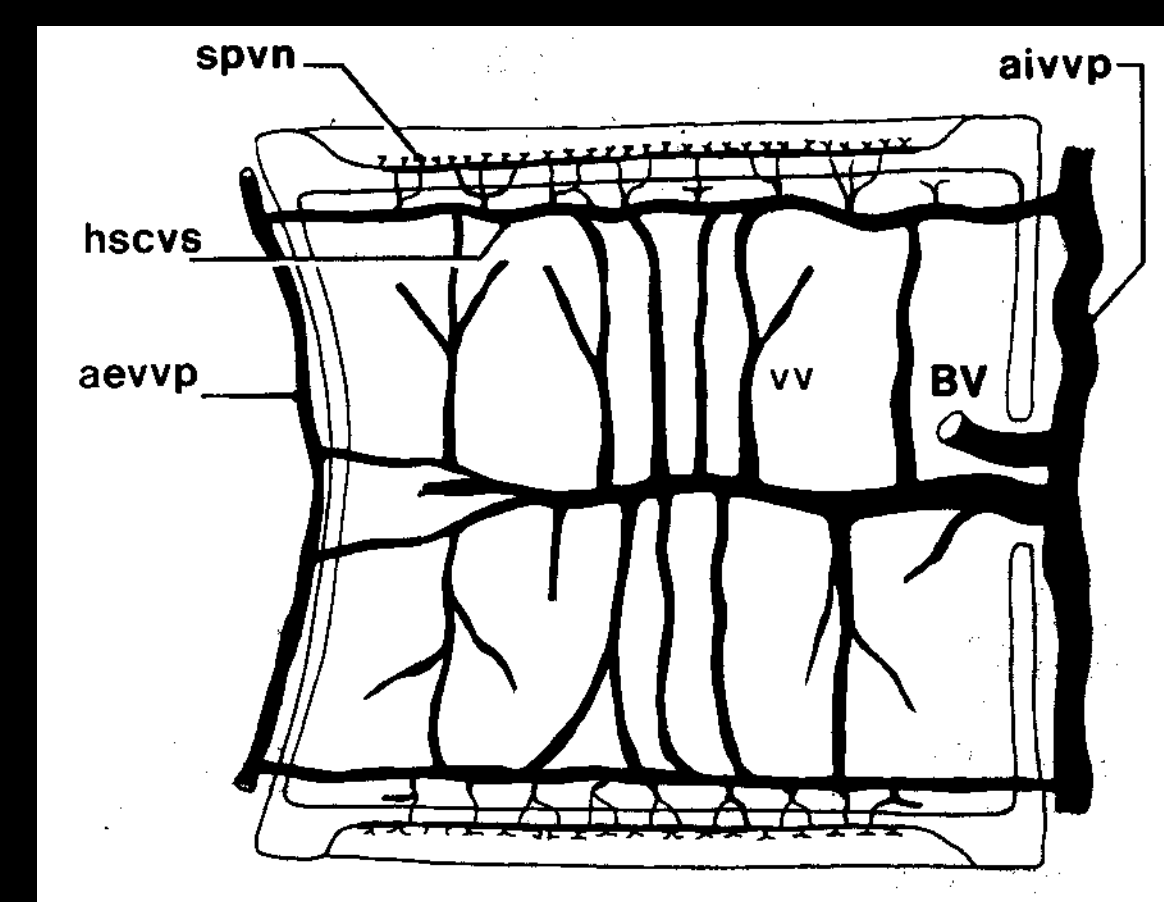

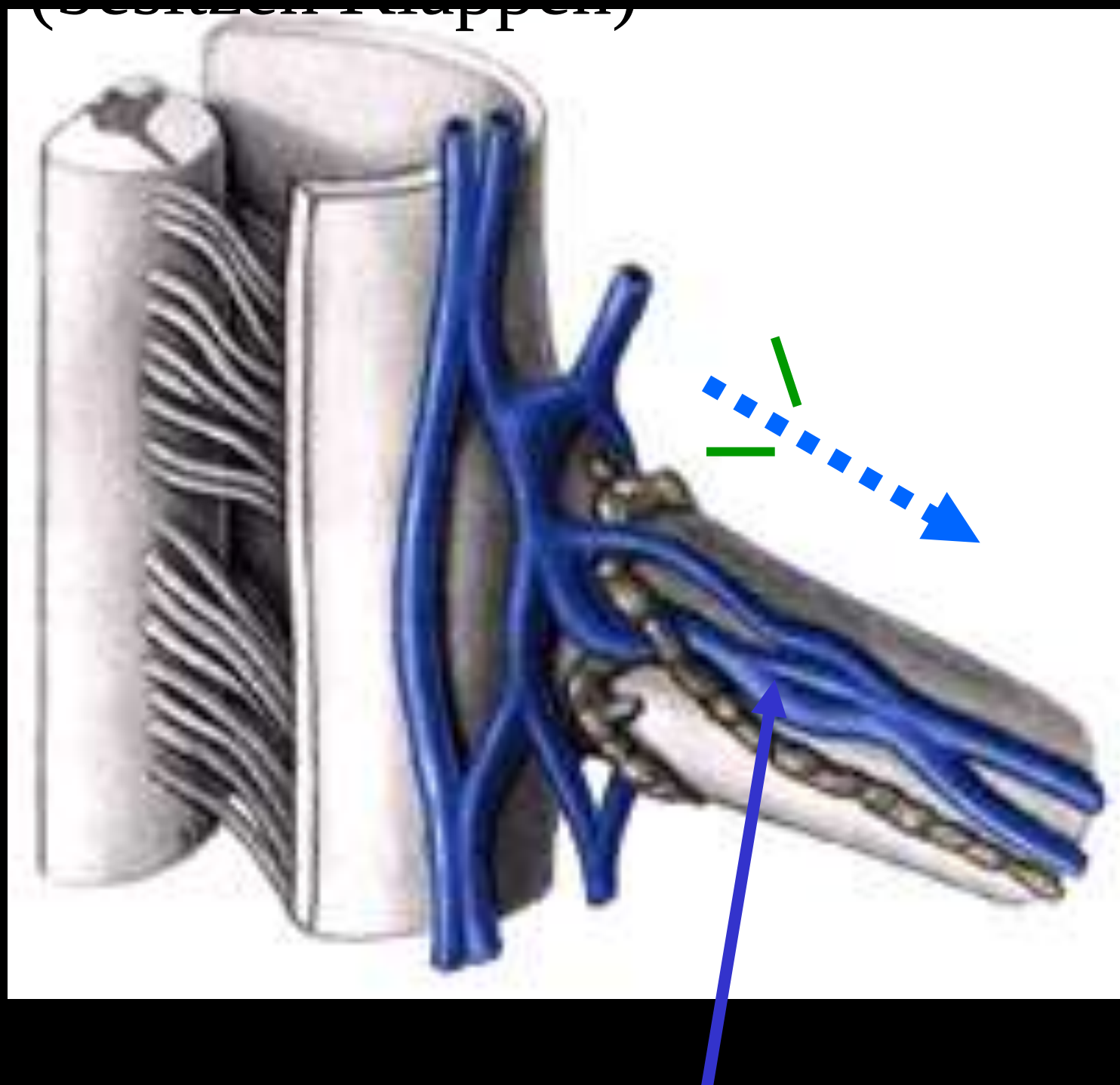

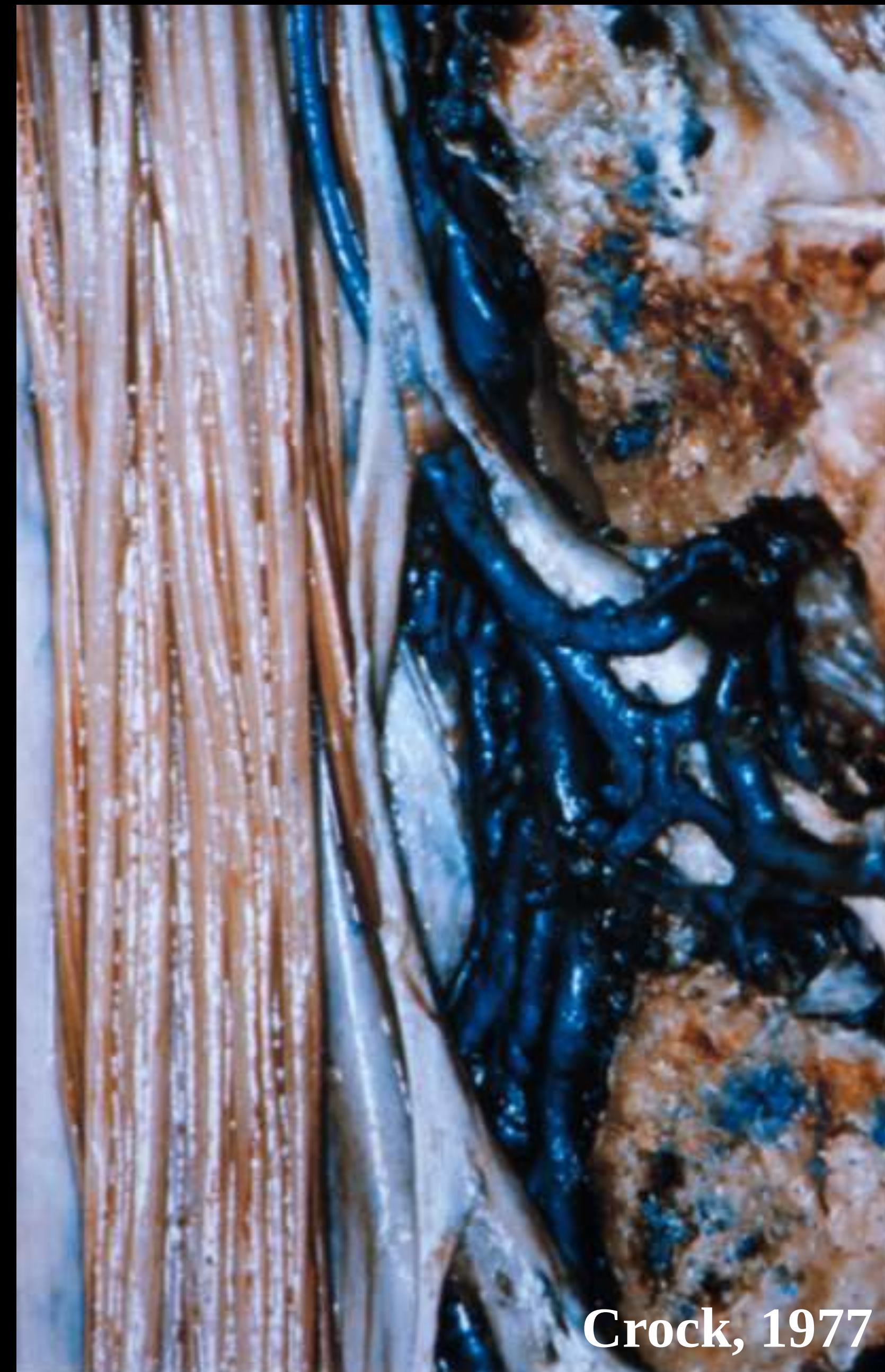
Crock, 1977


HWS


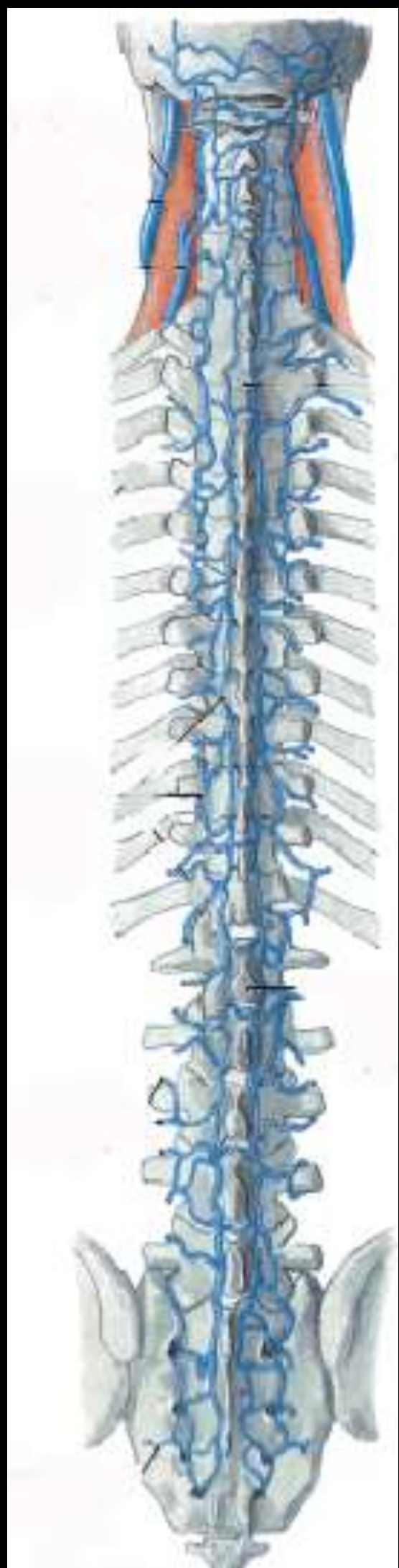

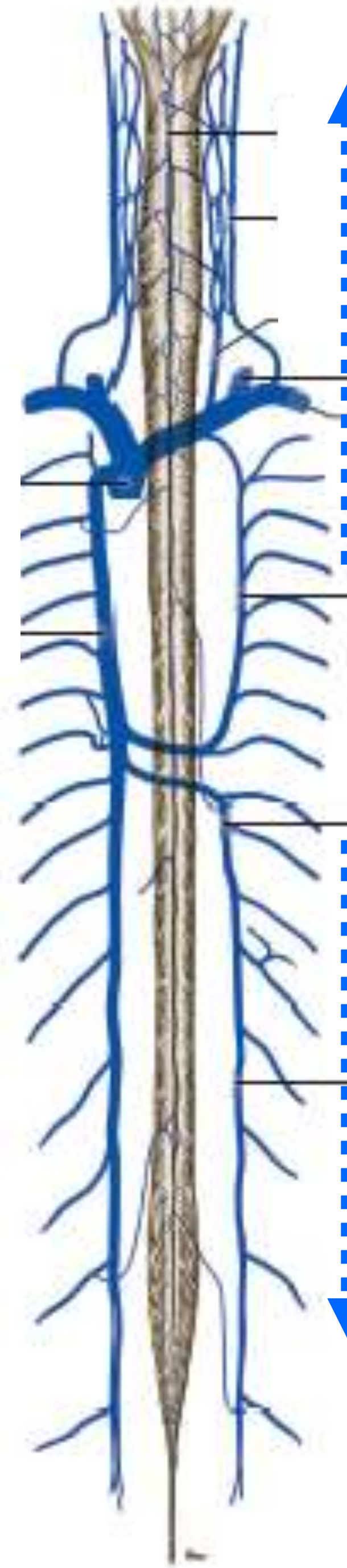
bevorzugt
Abflussri
V. vertebralis
V. cava
superior
V. azygos
V. hemiazygos acc.
V. hemiazygos
V. lumbalis ascendens
bevorzu
Abfluss
b Ansicht von vorn

Sagittal contrast-enhanced MR angiographic images (T1-weighted gradient-echo sequence [5.9/1.9; flip angle, 30°]) obtained during two dynamic phases.

Nijenhuis R J et al. Radiology 2004;233:541-547

Radiology

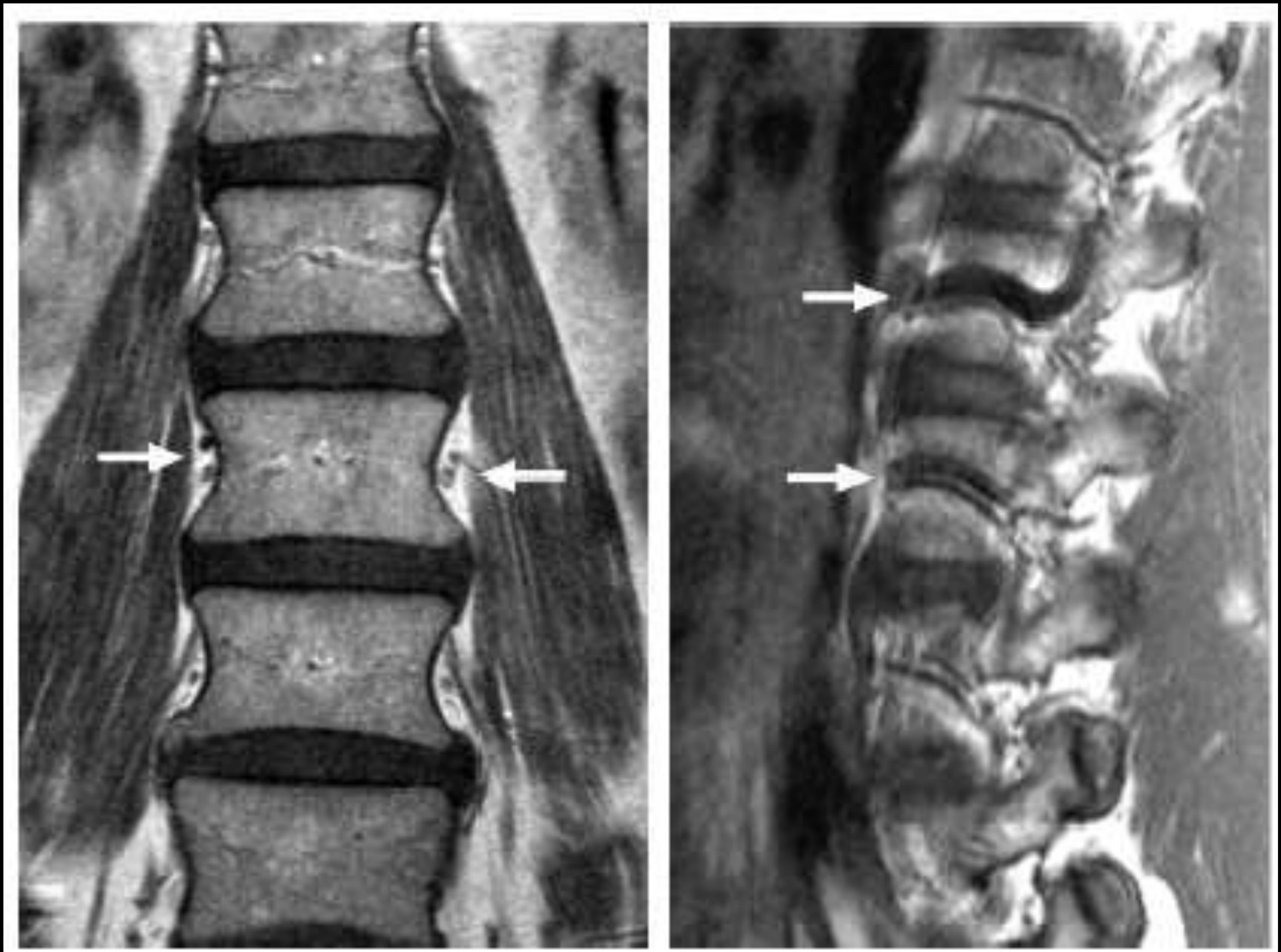

PITFALLS: EPIDURAL VEIN

T1-WI CSE

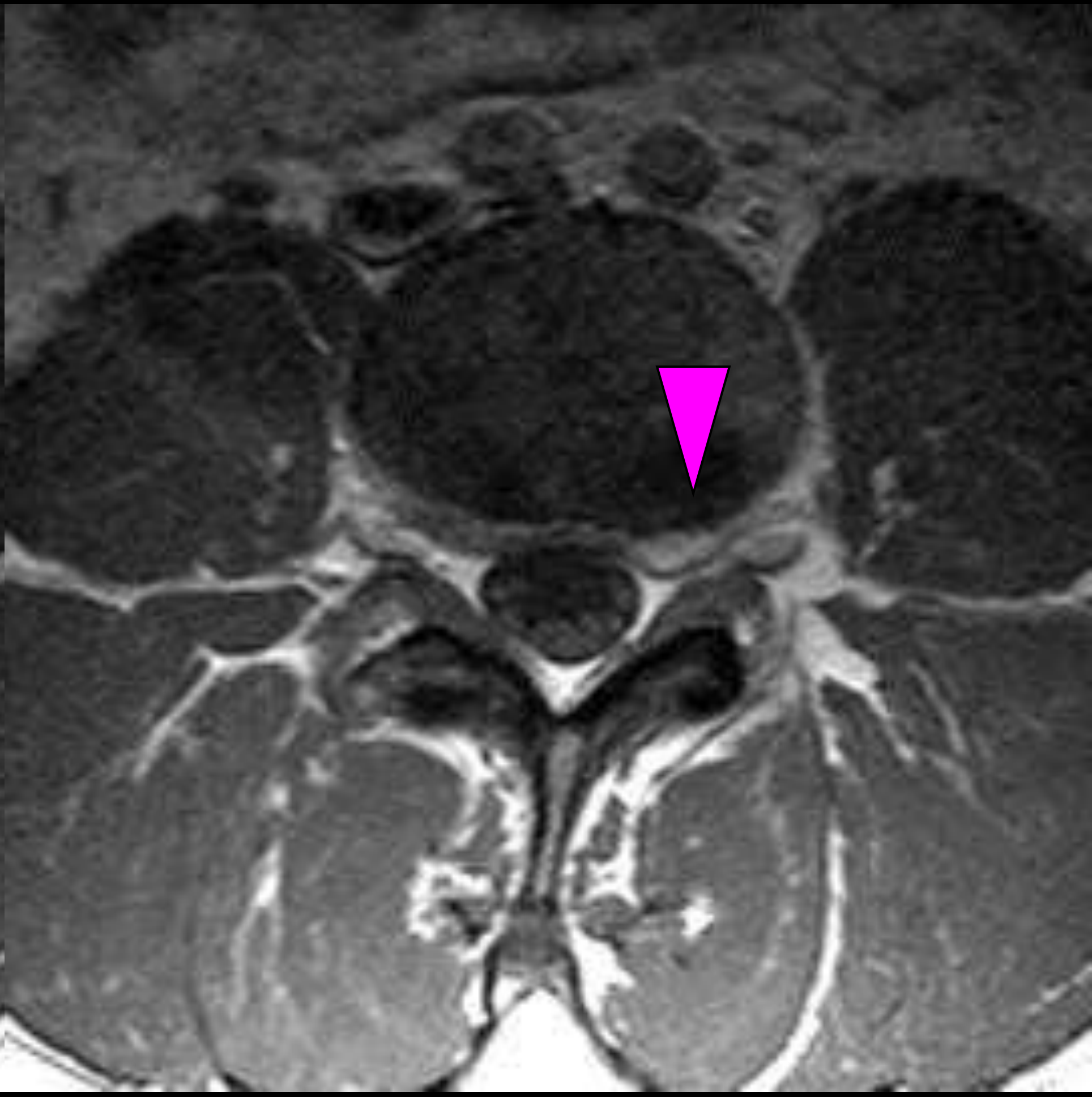

Contrast T1-WI CSE

PITFALLS: EPIDURAL VEIN

MRI

Normal enhancement

- Vessels of epidural plexus
- Basivertebral venous plexus
- Dorsal root ganglion (DRG)-do not confuse with an enhancing schwannoma

T1-WI
Fat Sat
Contrast
Enhanced

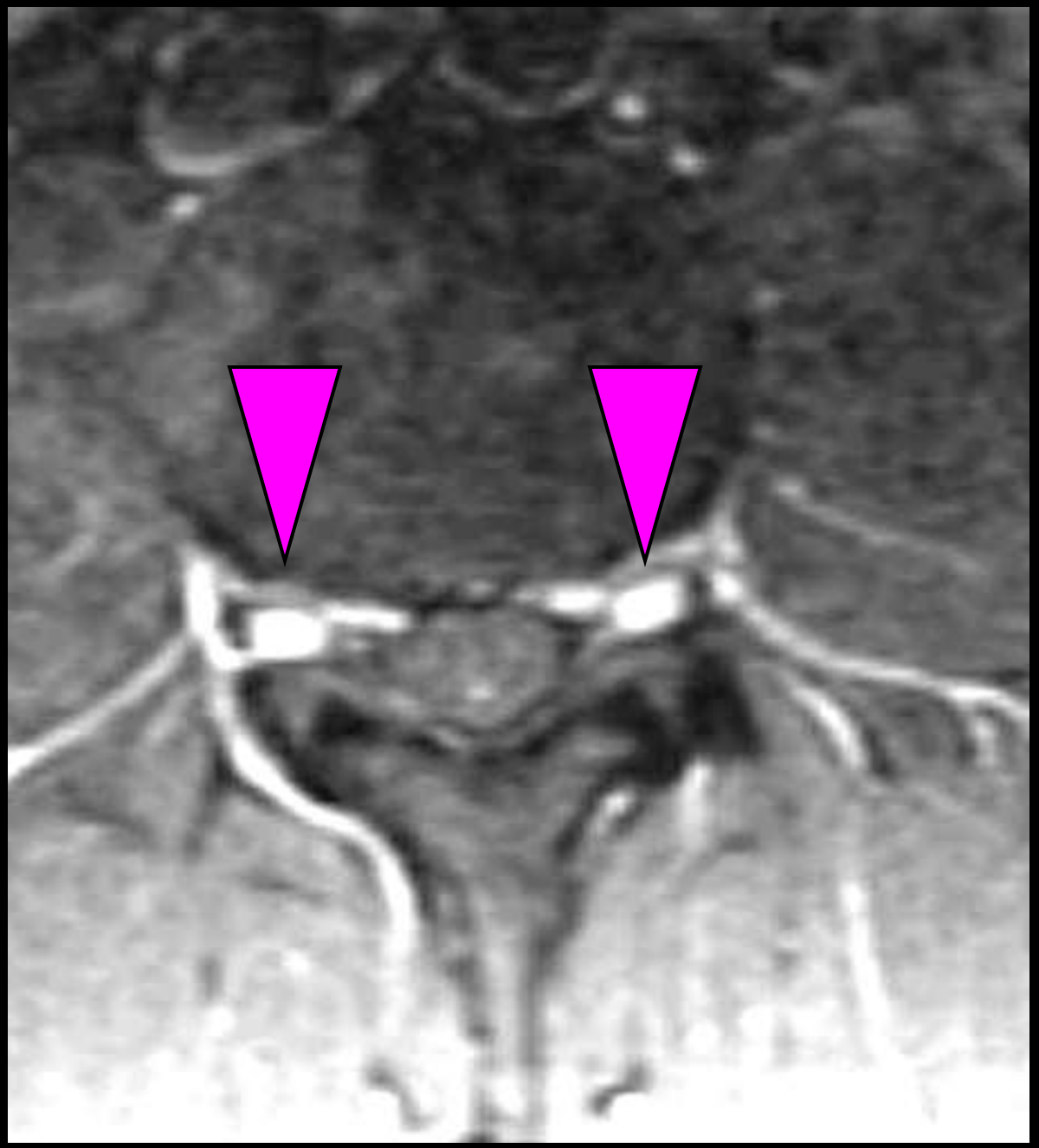

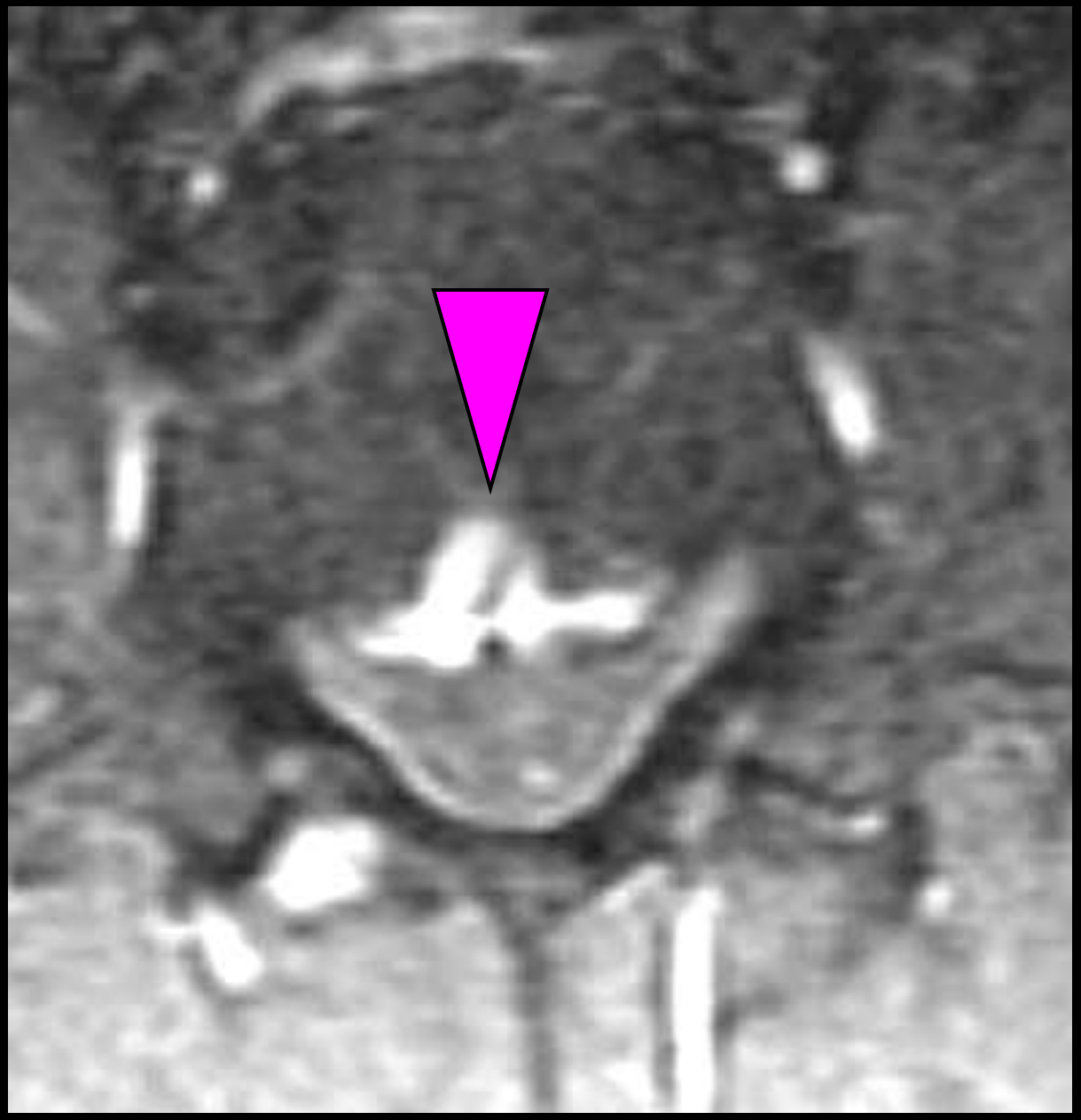

Radicular Vein Enhancement

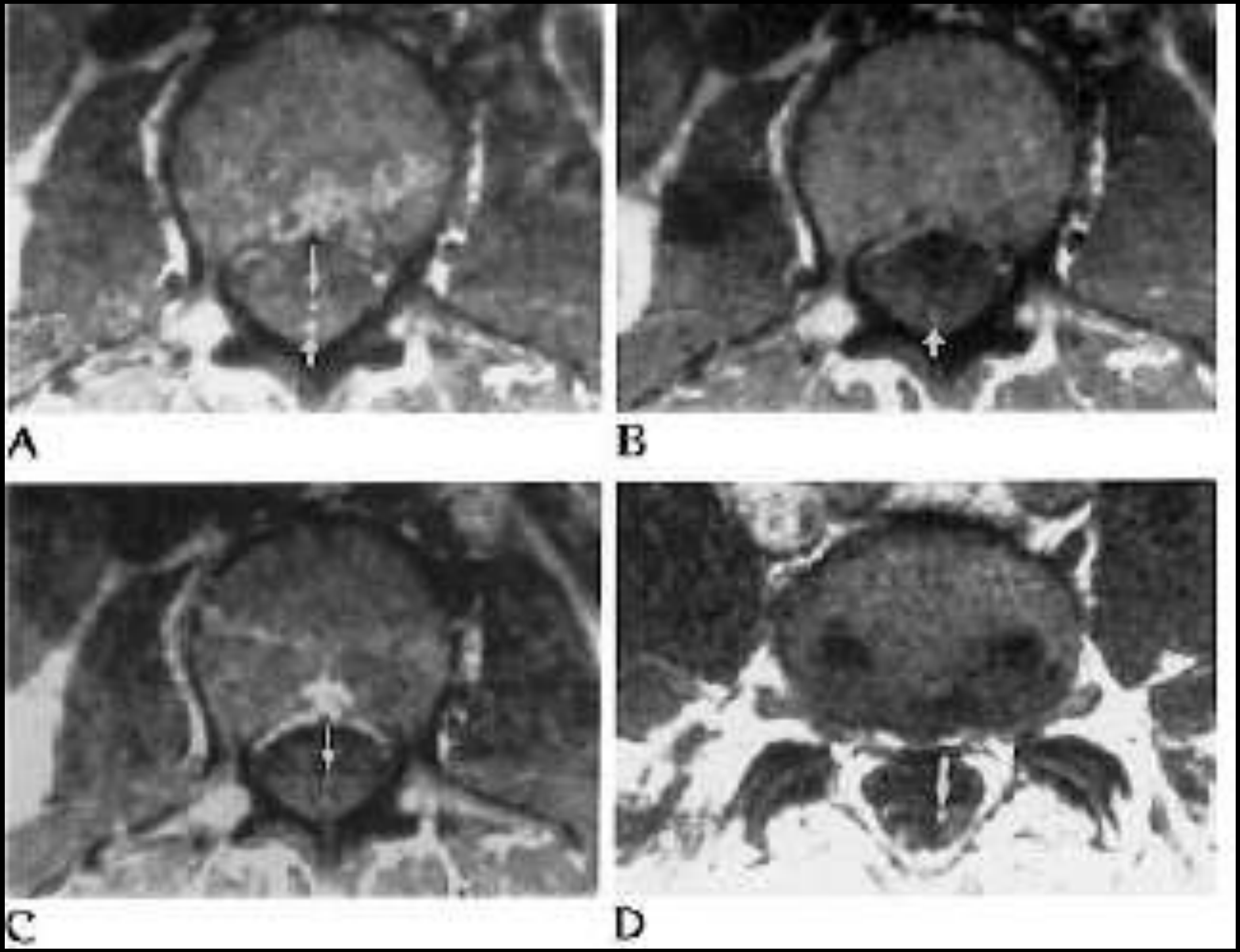

Lane JI, Koeller KK, Atkinson JLD. Contrast-Enhanced Radicular Veins on MR of the Lumbar Spine in an Asymptomatic Study Group. *AJNR Am J Neuroradiol* 16:269–273, February 1995.

SUMMARY: Contents

Bones

Joints

Ligaments

Muscles/tendons

Spinal Canal: Epidural/Intradural

Neural Canals/Neuroforamina

Neural Elements

Vascular Anatomy

Lateral

- The axis "ring"
- Intervertebral disc (IVD)
- Facet joint parallelism
- Interspinous distance
- Atlanto-dental interval <3mm
- Prevertebral ST
  - C2 < 7mm, <5mm(peds)
  - C6 < 22mm
  - At C4-C7 < ¾ Vert Body
- Essential to evaluate to the C7-T1 level (Swimmers view)

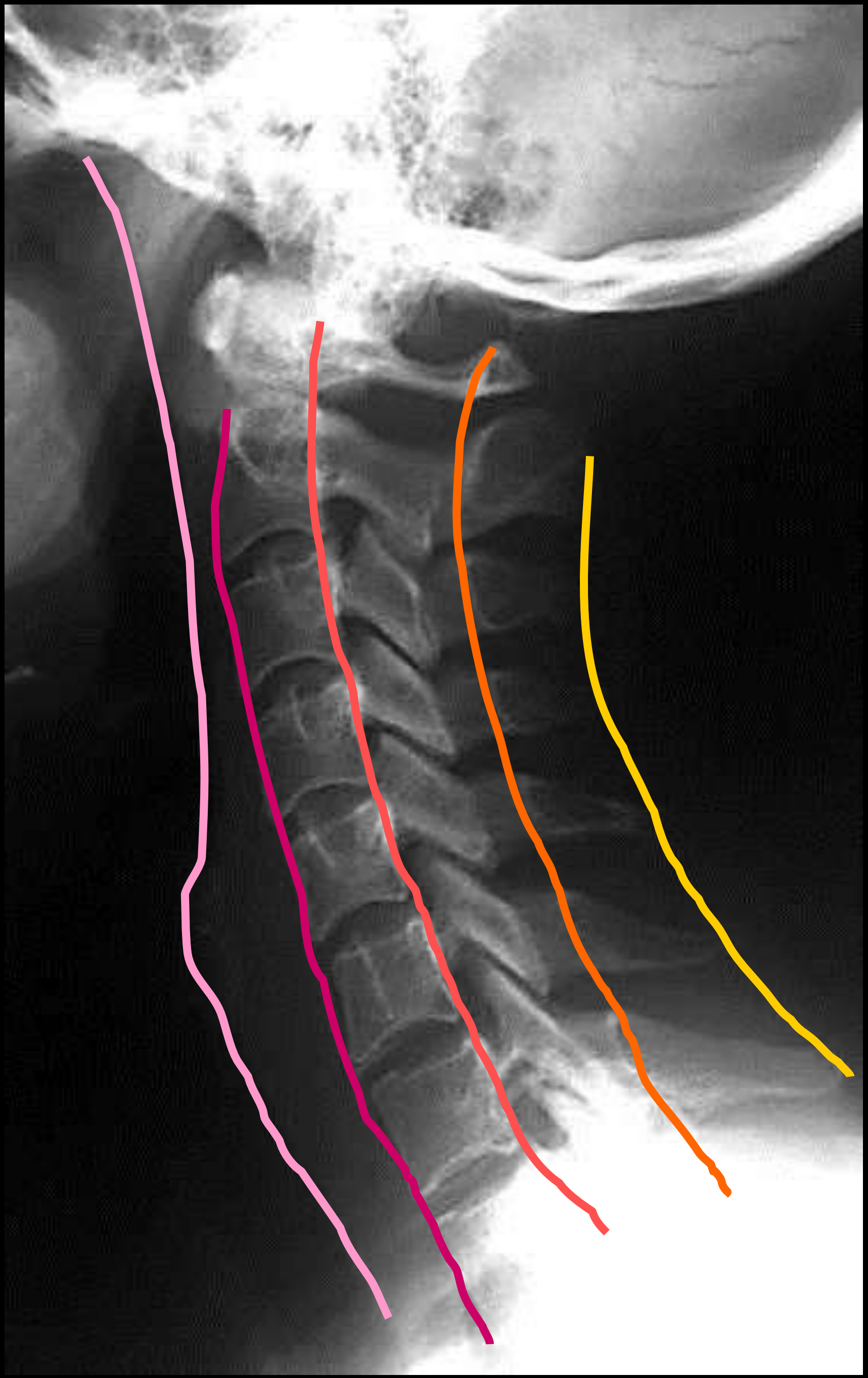

Lateral

THE FIVE LINES

- Anterior prevertebral soft tissues
- Anterior vertebral body line
- Posterior vertebral body line
- Spinolaminar line
- Spinous process line

The Axis Ring

Anterior arc = junction cortex C2 body and pedicle

Upper arc = junction dens and body

Posterior arc = posterior cortex C2 body

Inferior apex = transverse process C2

Oblique View

- Neuroforaminal Encroachment
- Contralateral pedicle
- Vertebral body morphology
- Laminae appear as "shingles on a roof"
- Trauma Obliques
  - supine imaging ➔ can appear distorted

AP View

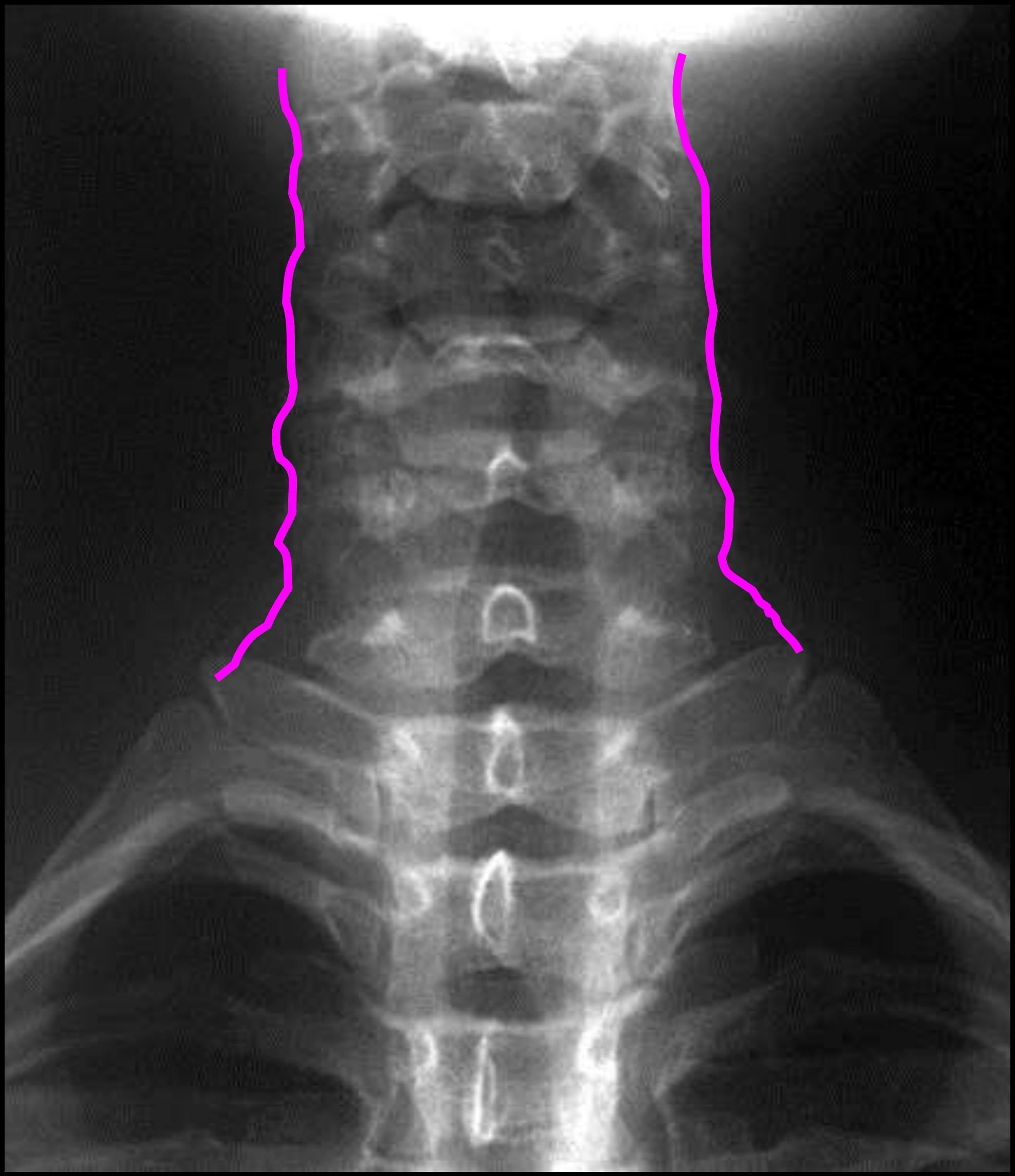

- Visualizes C3 to upper thoracic VB
- Alignment of the spinous processes
  - Bifid may not align
- Smooth alignment of the lateral margins of the articular masses
- Uncovertebral joints
- VB morphology

AP Odontoid View

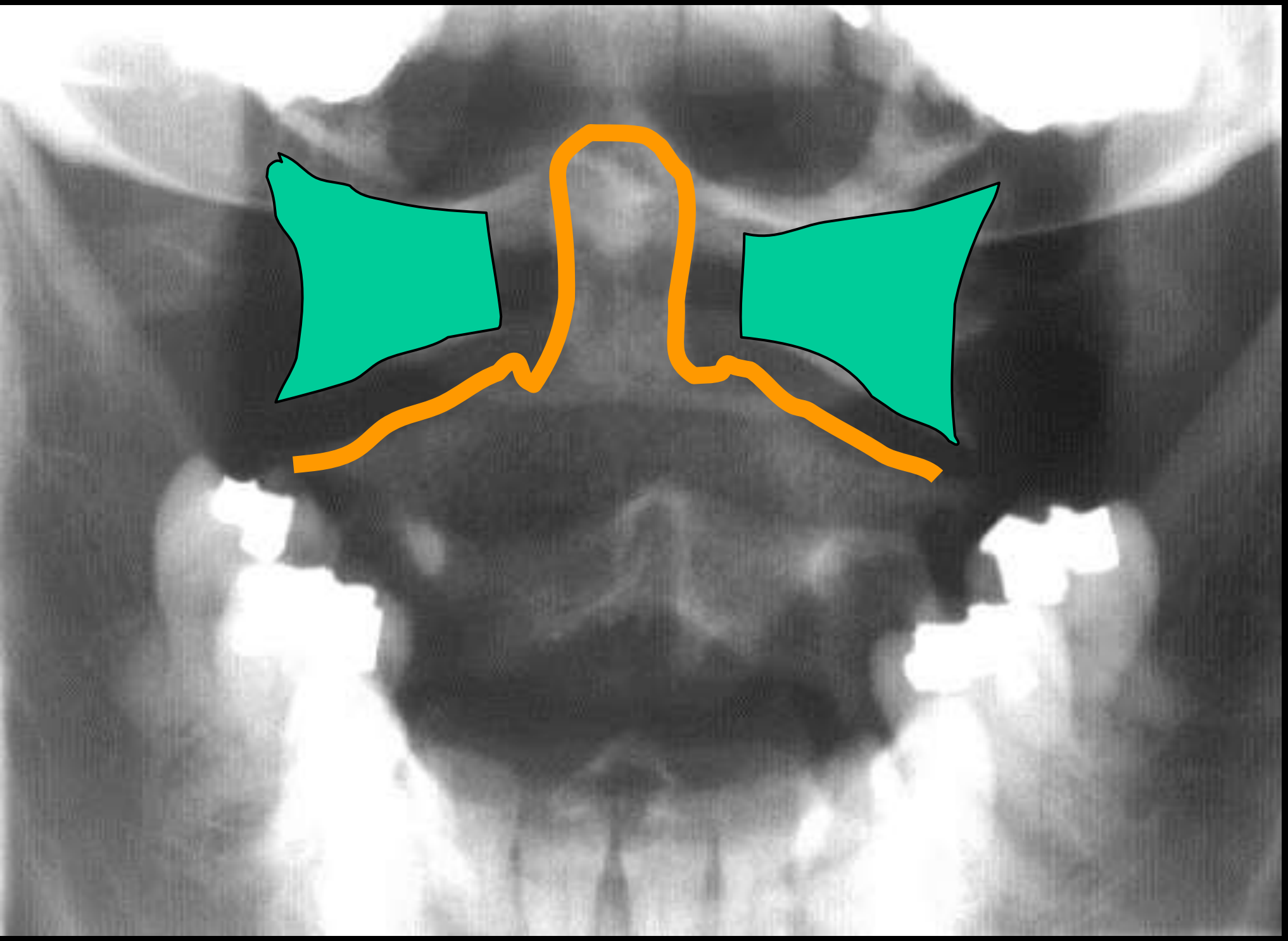

- Atlantooccipital joint
- Atlantoaxial joint
- Odontoid morphology
- Odontoid process position
- Alignment of C1 lateral masses & C2
- Rotation/head tilt - narrowing occurs on side opposite of head movement

C1 - C2 Lateral Articulation
Related Neural & Vascular Elements

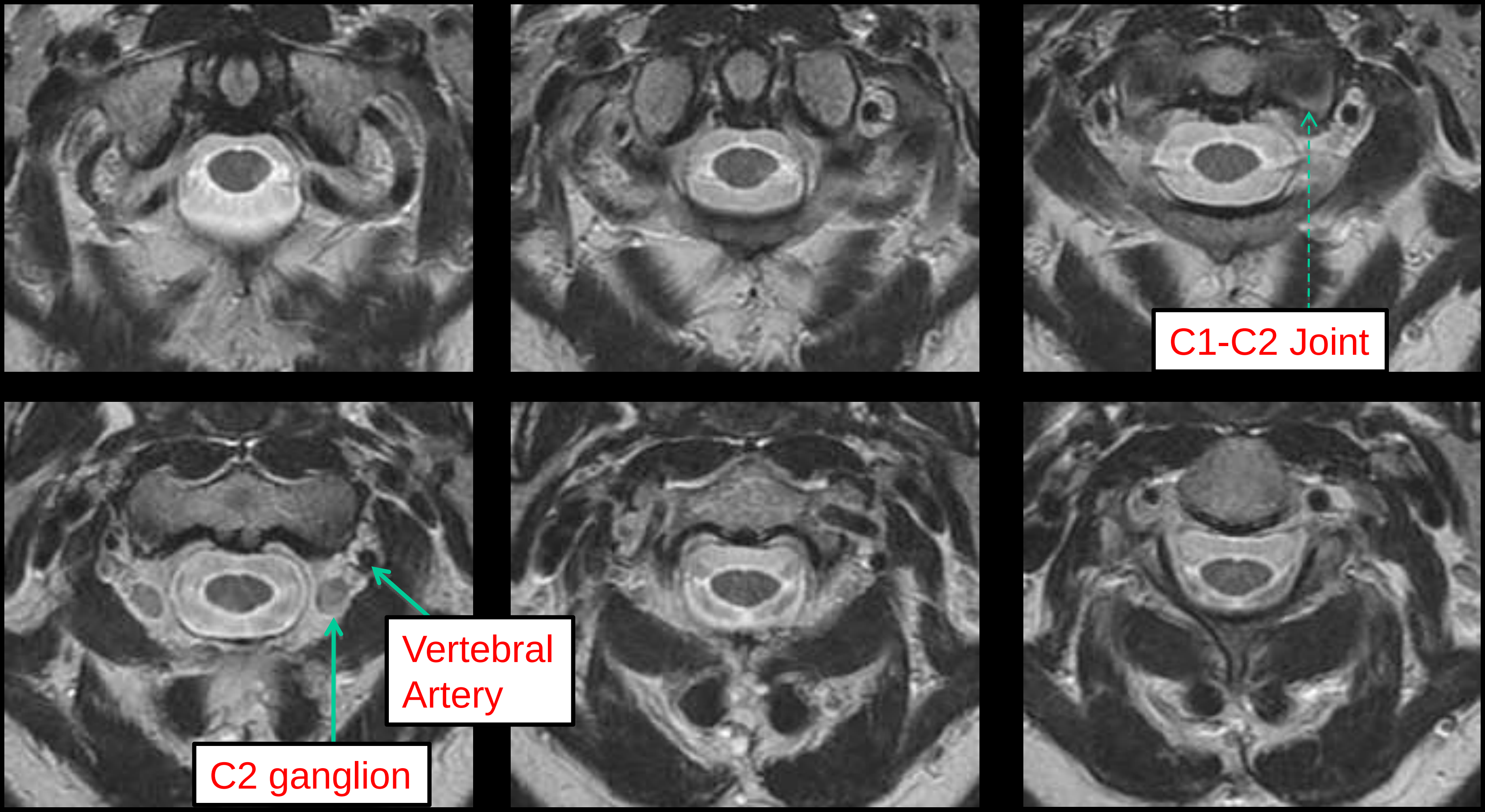

Courtesy of Tim Maus, MD

C1 - C2 Lateral Articulation Related Neural &

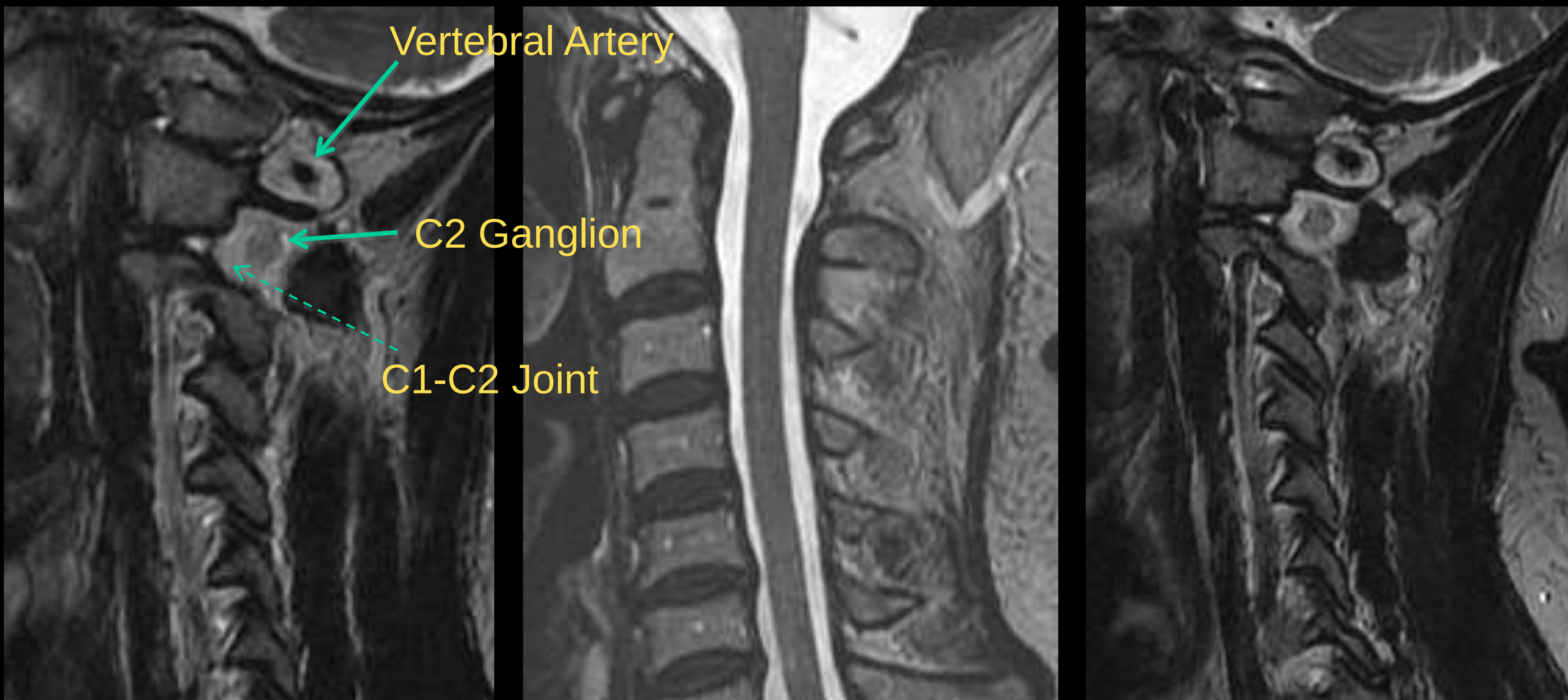

Courtesy of Tim Maus, MD

MR Imaging Protocol: C-spine

- Sagittal T1-weighted SE
- Sagittal T2-weighted FSE
- STIR/Fat-Suppressed T2-weighted
- Axial T2* gradient-echo
- Axial T2-weighted FSE

Typical Cervical Exam

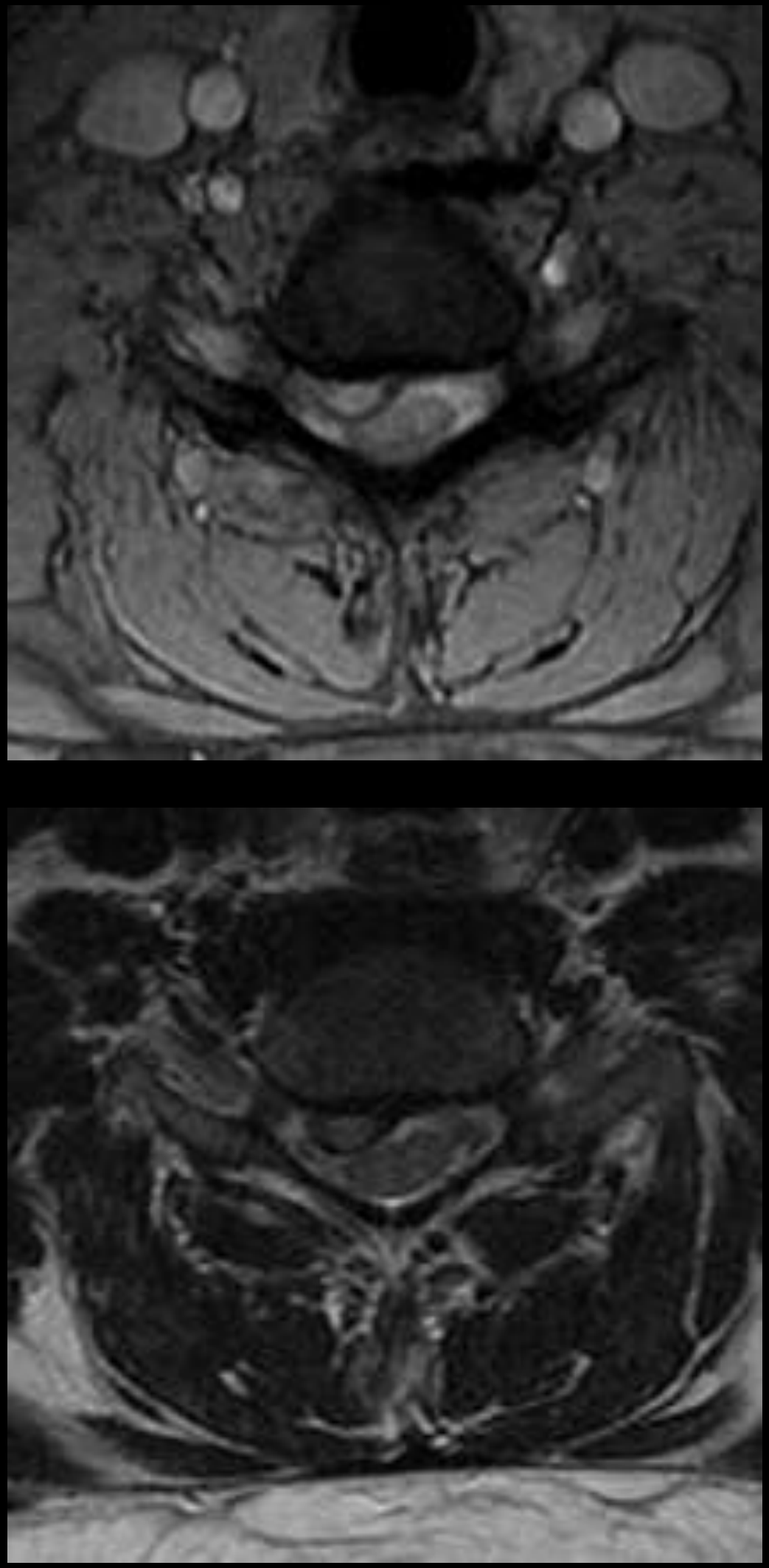

- Sagittal T1 & FSE T2
- Axial FSE T2 & GRE T2

Khanna AJ, ed. MRI for Orthopaedic Surgeons. 2010

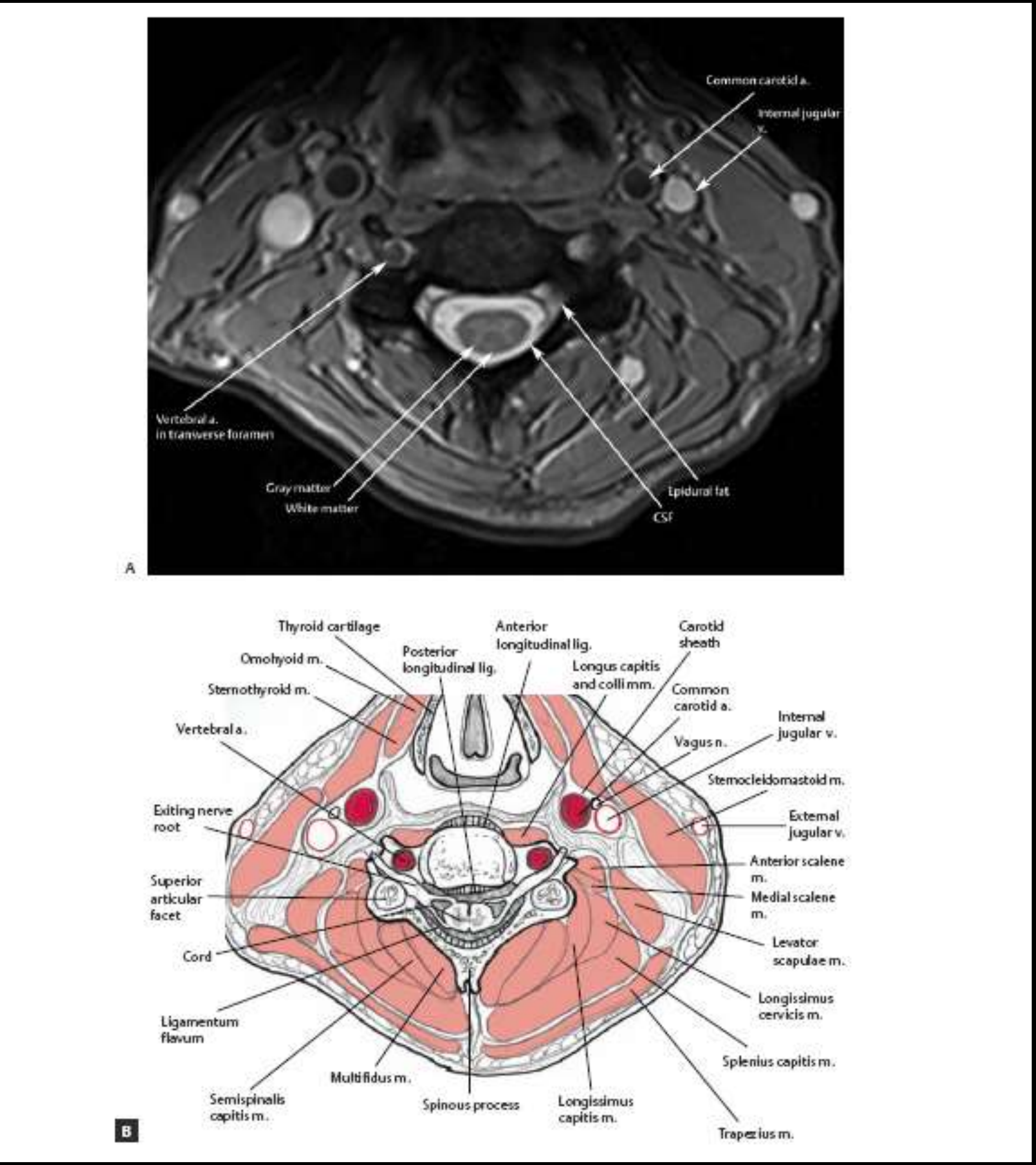

Khanna AJ, ed. MRI for Orthopaedic Surgeons. 2010

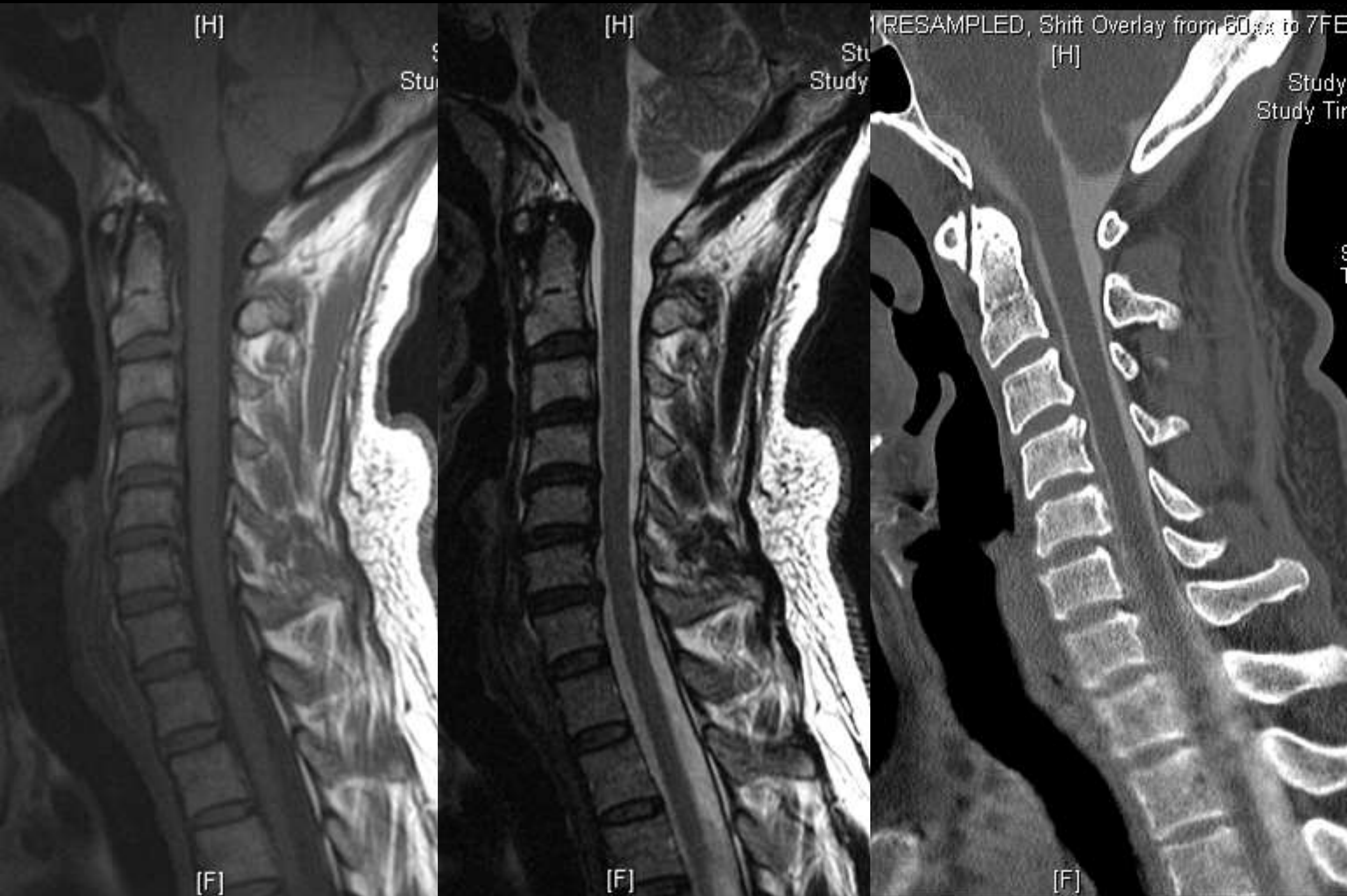
[H]
Study
[F]
[H]
Study
[F]
RESAMPLED, Shift Overlay from
[H]
Study
[F]

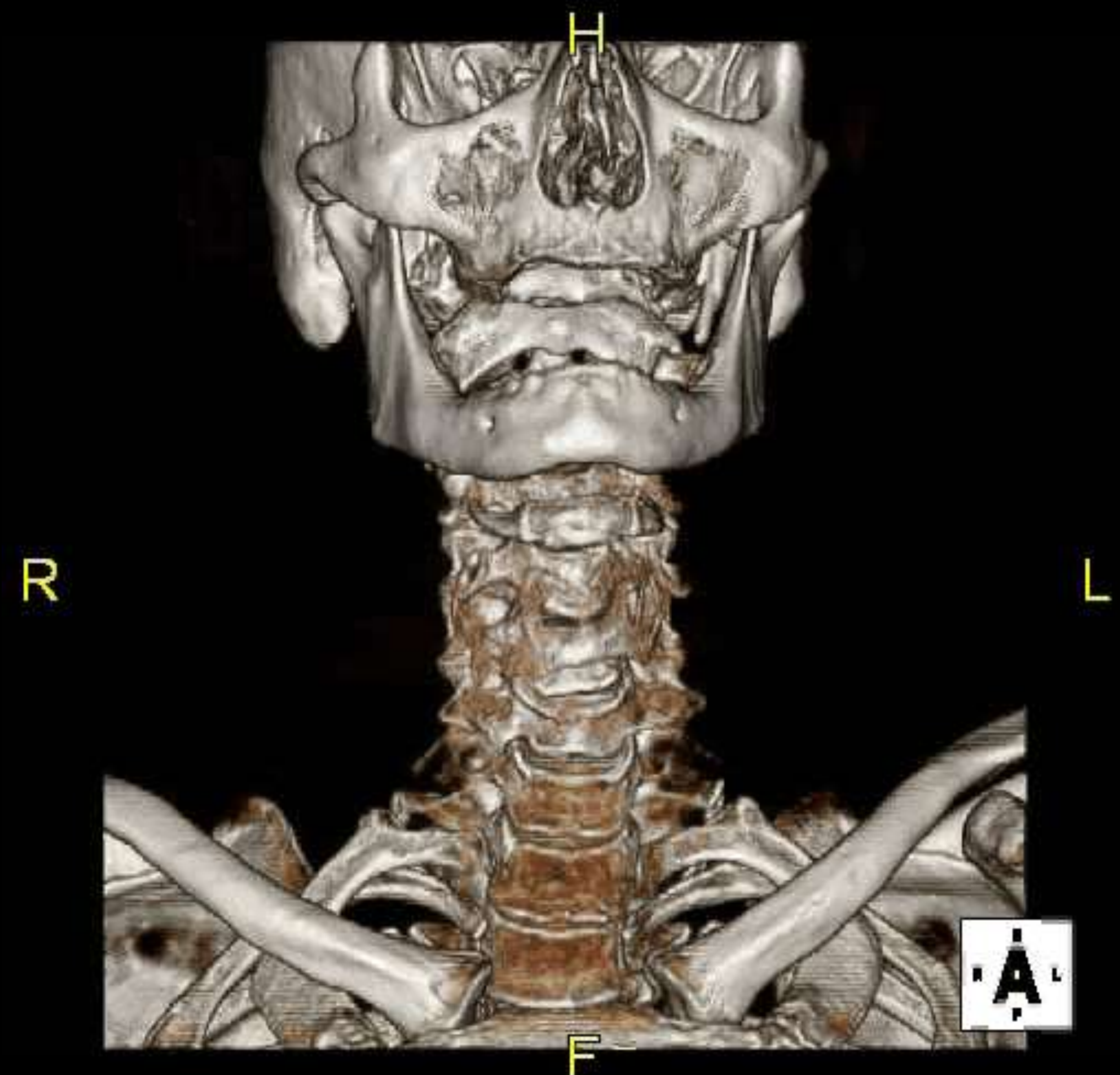

Courtesy of Krishna Juluru

ACR Imaging Protocol

- Field Strength
- Coil
- Pulse Sequences
  - Sagittal
    - T1 CSE
    - T2 FSE (fat suppression)
  - Axial ➔ oblique parallel to IVD
    - T2 FSE
    - T1 CSE

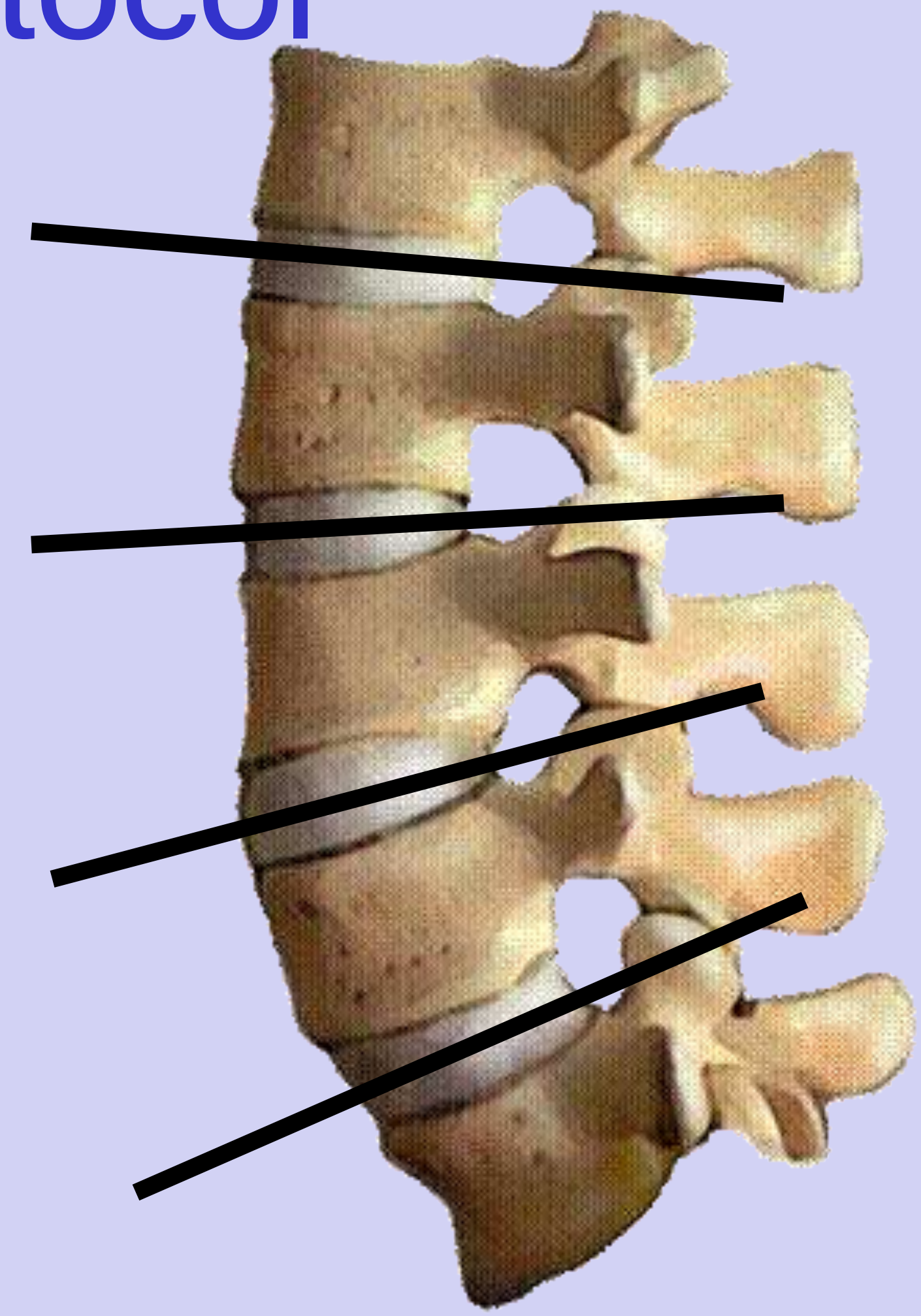

Typical Lumbar Exam

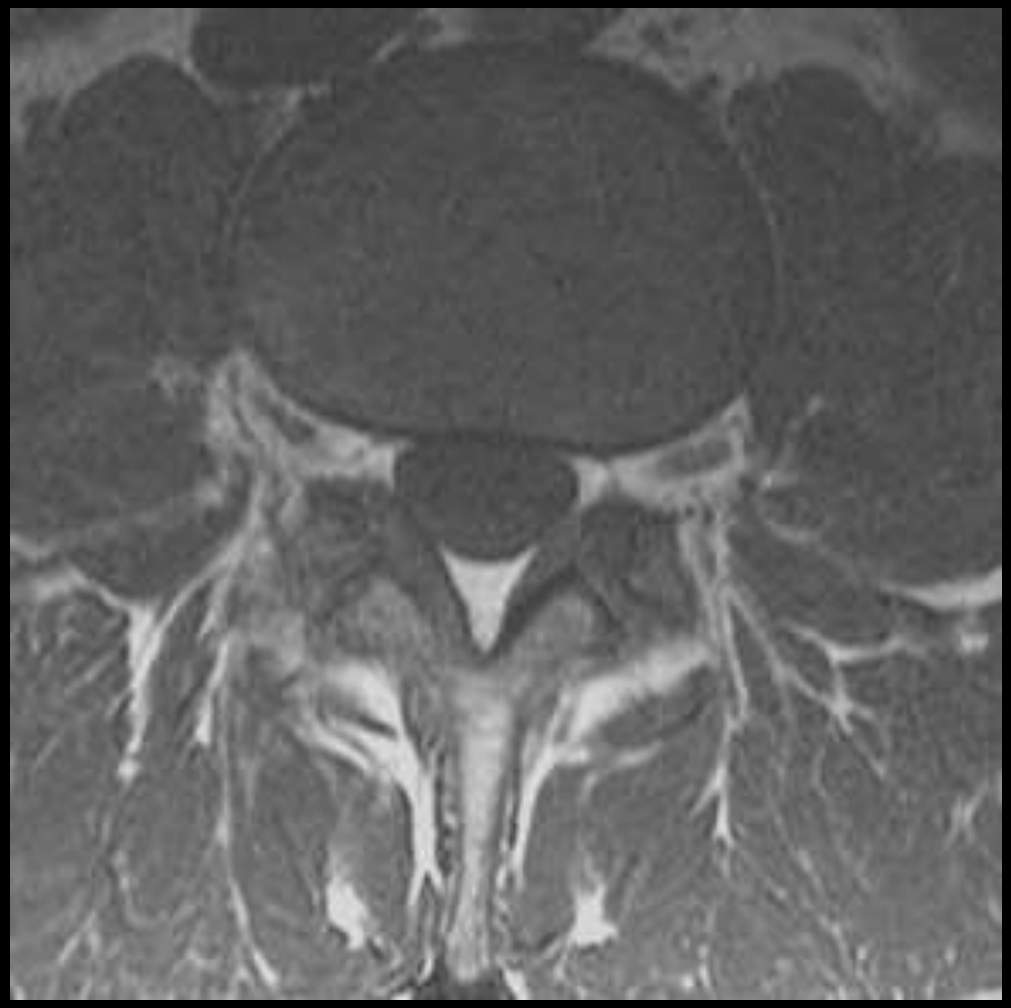

- T1, FSE T2 sagittal and axial images
- Axial images aligned to interspace

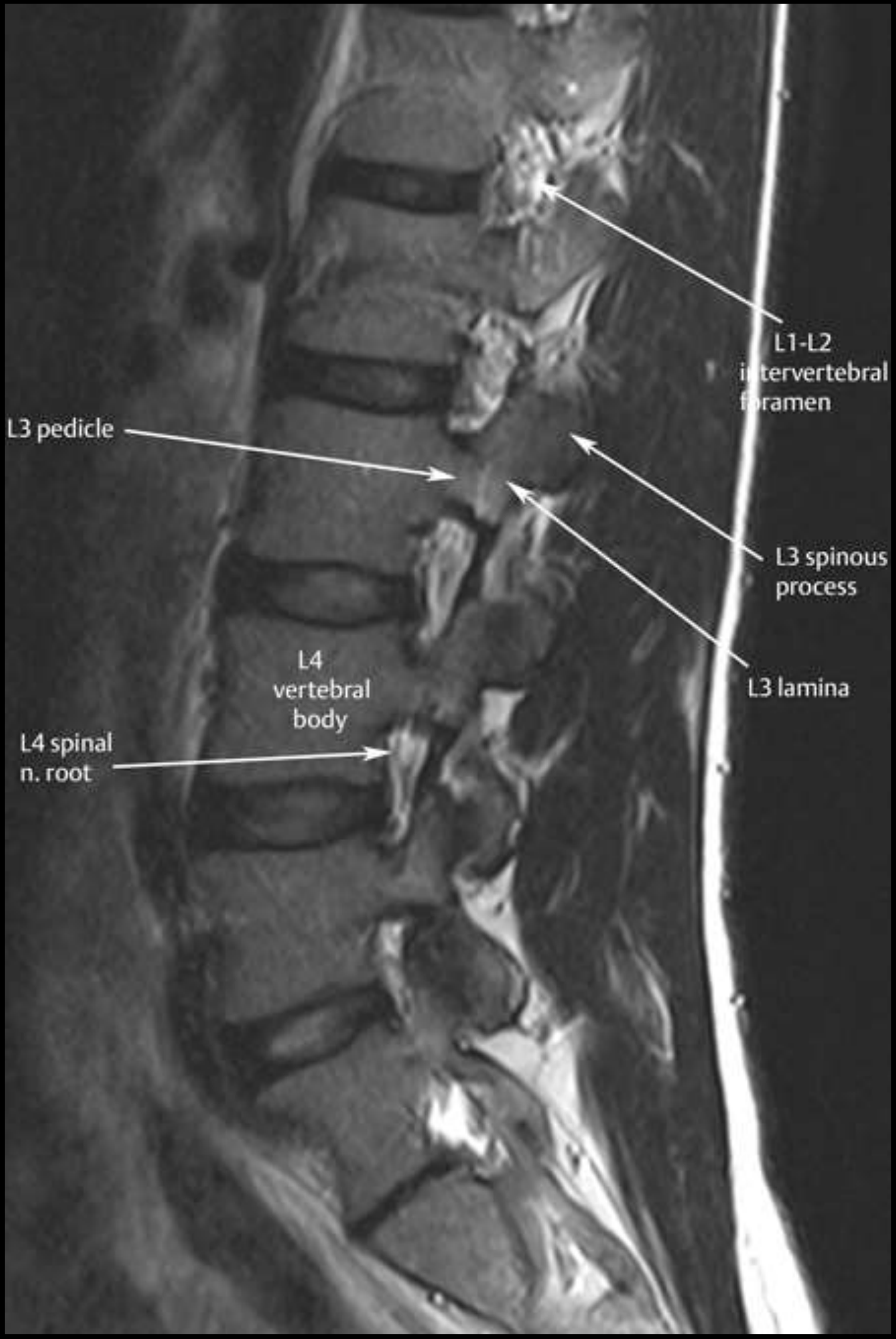

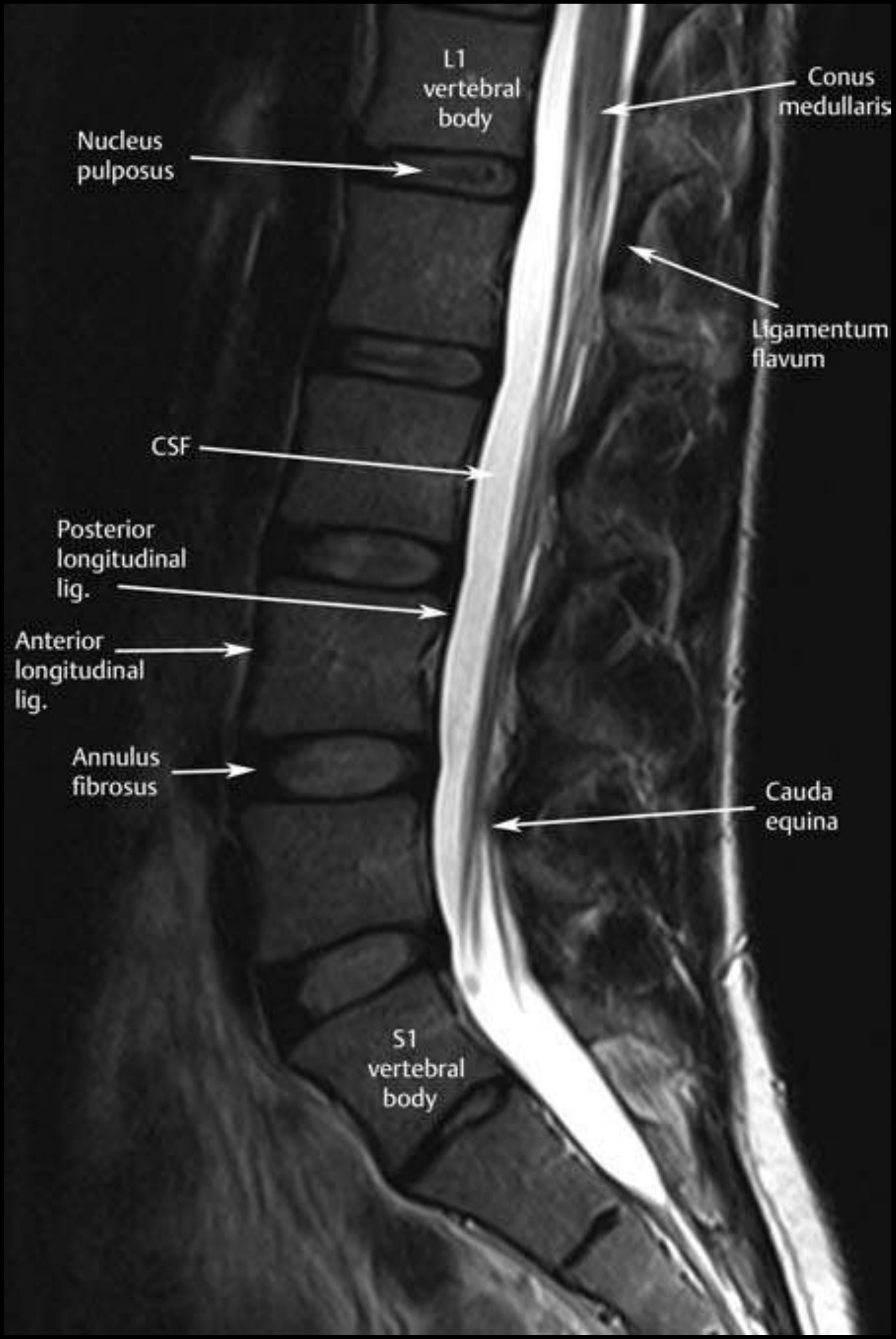

Khanna AJ, ed. MRI for Orthopaedic Surgeons. 2010

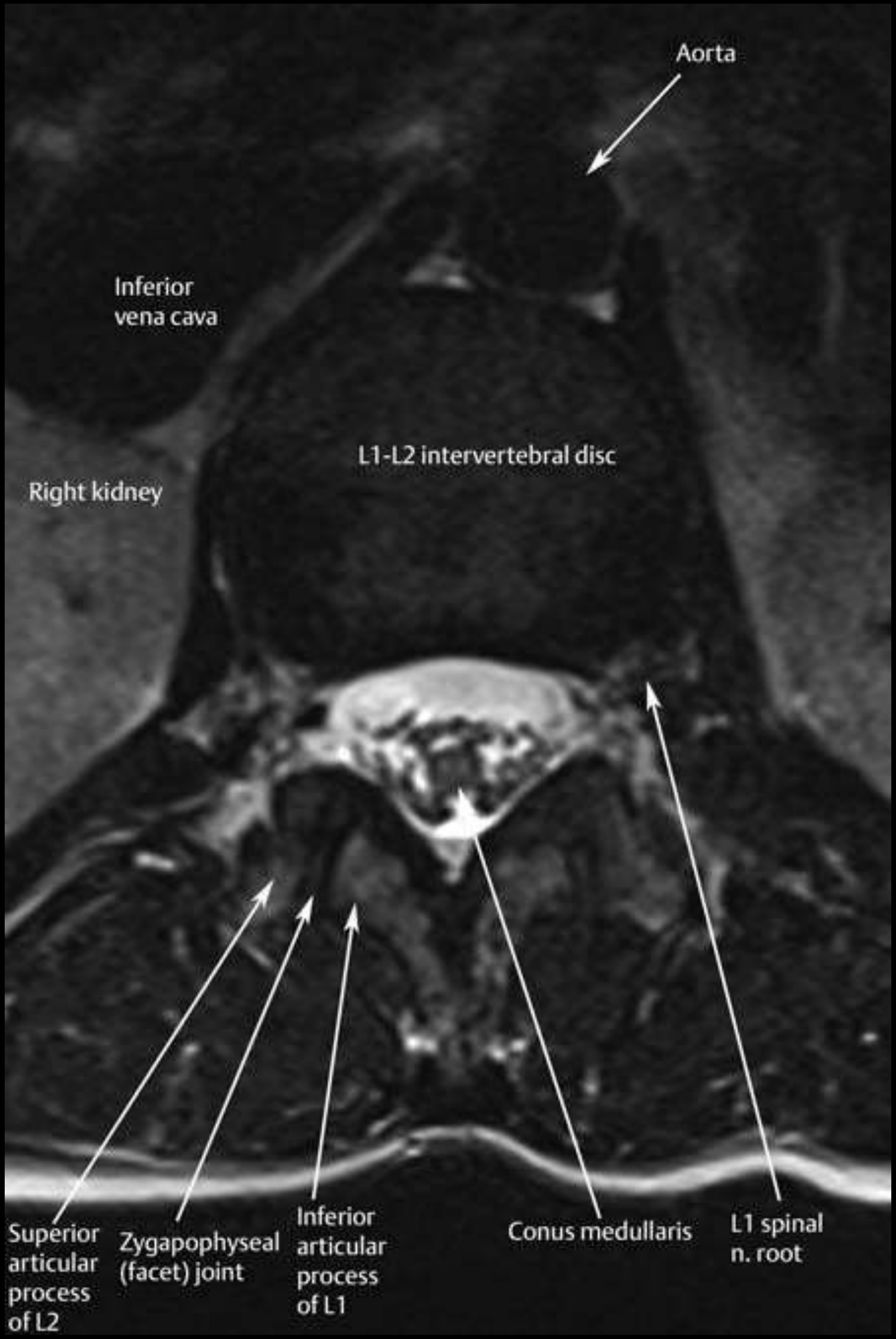

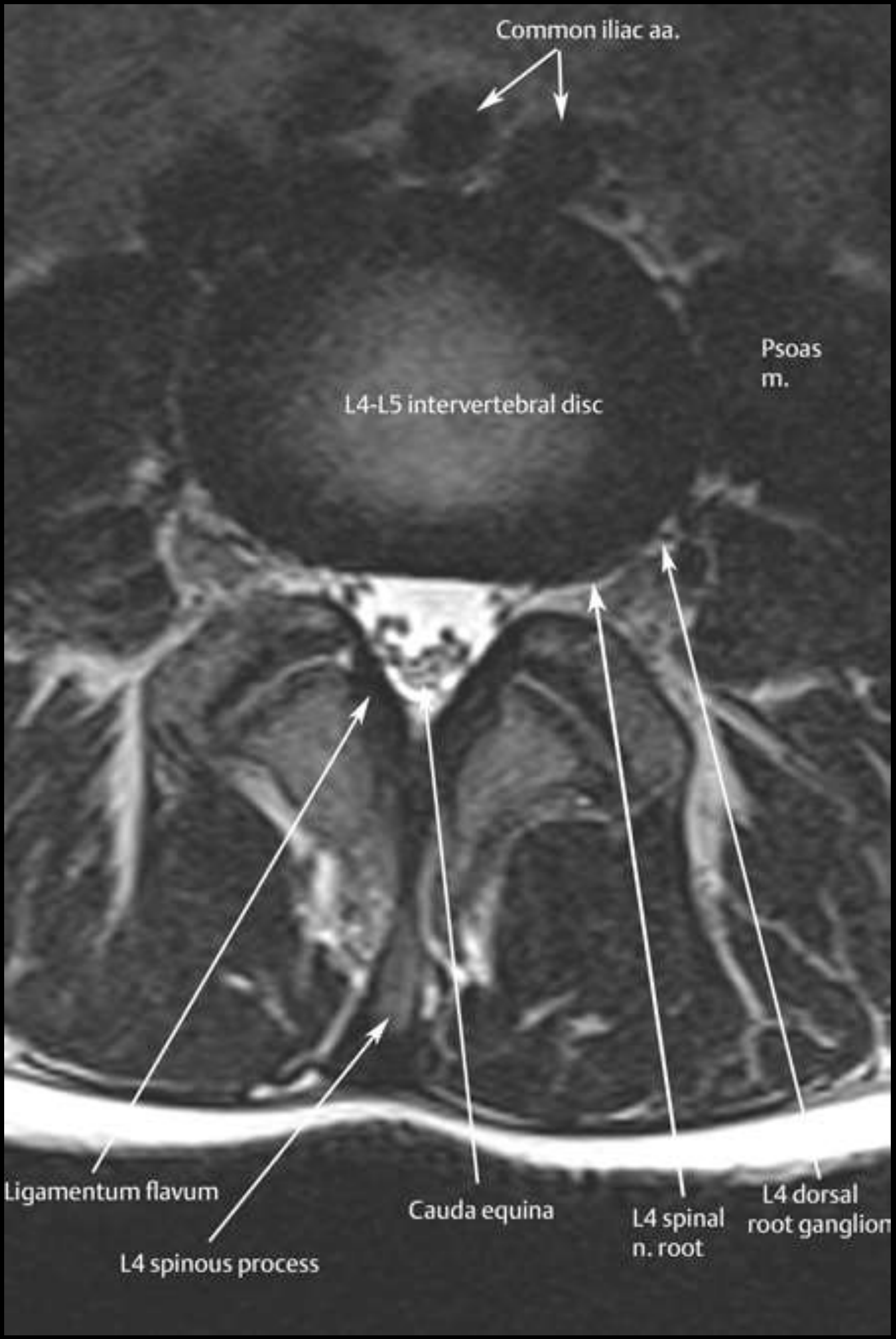

Khanna AJ, ed. MRI for Orthopaedic Surgeons. 2010

Thank You